



New treatment for Meniere's disease

John Tonkin, AM, MBBS, DLO, FRCS, FRACS, is visiting medical officer, St Vincent's Private Hospital, Sydney, New South Wales.

Meniere's disease is fairly common in Australia. Clinically it presents as a combination of symptoms of episodic vertigo, fluctuant deafness, and tinnitus in the affected ear accompanied by a feeling of fullness or blocking in that ear. The pathophysiology of Meniere's disease is a hydrops of the inner ear. The cause of this hydrops is yet to be firmly established.

In the early stages of the disease, medical management with a strict low salt diet sometimes with the addition of a diuretic, is the mainstay of treatment. Additional measures such as the prescription of betahistine hydrochloride (Serc) are often used. However, a Cochrane review¹ states there is insufficient evidence to say whether betahistine has any effect on Meniere's disease. Nonetheless, medical measures often result in the patient's disease being moderately or well controlled.

In some cases however, medical management is insufficient and surgical intervention is necessary. Frequently destructive measures such as labyrinthectomy, division of the vestibular nerve and various operations on the endolymphatic sac are prescribed.

A conservative surgical measure namely the introduction of gentamicin into the affected inner ear has been developed as an alternative to these more invasive techniques.

Preliminary results from both overseas and here in Australia have shown gen-

tamicin infusion of the middle ear to be a very satisfactory treatment for resistant vertigo in patients with Meniere's disease.²

Gentamicin infusion of the middle ear

The discovery of a hormone secreted by the chief cells of the saccus endolymphatic has given rise to new insights into the pathophysiology of Meniere's disease.^{3,5}

This hormone, called saccin, has been shown to have powerful diuretic properties. It is thought that saccin regulates the function of the stria vascularis which is believed to act in the same way as the renal tubules absorbing sodium from the endolymph.

Excess saccin inhibits the function of the stria vascularis causing a rise in the sodium content of the endolymph. Because of the increase in sodium content the osmotic pressure rises and fluid passes across the Reissner's membrane. This provides an explanation for the occurrence of hydrops.

The initial investigation and ongoing development and testing of this theory has been conducted by Paul Bretlau's laboratory in Denmark. Expanding on this pathophysiology, it is known that gentamicin inhibits the synthesis of protein. It is believed therefore that gentamicin infusion of the inner ear causes a reduction in the synthesis of protein in the chief cells of the saccus endolymphatic sac. This

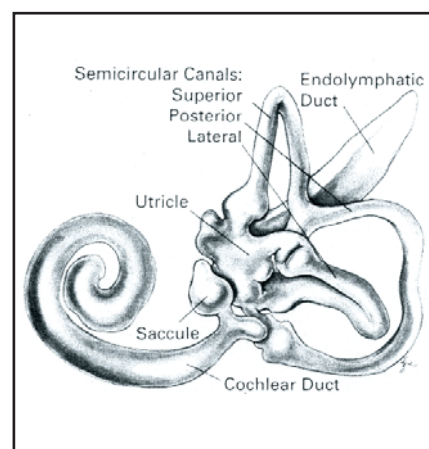


Figure 1. The adult membranous labyrinth as viewed from medially. Adapted from Anson B J, Donaldson J A. *Surgical Anatomy of the Temporal Bone and Ear*. Philadelphia PA: WB Saunders, 1983.

reduction of secretion of saccin is the most likely reason for the success of gentamicin infusion in the treatment of Meniere's disease.

The procedure

This operation can be carried out under local anaesthetic. A tympanomeatal flap can be elevated and the round window niche easily visualised without removing any of the bone of the annulus. The chorda tympani nerve is not endangered in any way.

Once the round window niche has been visualised the gelfoam can be gently packed into the niche and the gentamicin dripped onto the Gelfoam. Gentamicin

passes with great ease across the round window membrane as a slow but continuous infusion. The amount used for this procedure is 4 mg. This is one-tenth of 1 mL of the standard gentamicin ampoule of 80 mg/2mL.

A small amount of gentamicin is allowed to soak into the Gelfoam placed in the round window niche. As soon as one-tenth of 1 mL has been injected into the middle ear the flap is replaced and a small wick placed over the tympanomeatal flap.

The patient can leave hospital in a few hours time or after several hours if a light general anaesthetic has been given. Most patients experience a sense of ataxia for a short period after surgery. This may vary in length from a week or two to several weeks. In the elderly, it can sometimes be a moderate problem and would have to be managed by means of Cooksey-Cawthorne exercises.

These are the so-called post-labyrinthectomy exercises and as a general rule patients can carry out these exercises for themselves, although occasionally patients may need the advice and care of a vestibular physiotherapist.

Care should be taken in the patient who has other disabilities such as poor eyesight or additional disabilities of the major joints of the leg.

Results

In the first 25 cases carried out, the results are as follows:

- 50% hearing remained the same
- 25% hearing improved somewhat
- 25% hearing loss
- 0% had a severe loss of hearing.

Vertigo

Ninety percent of cases experience a satisfactory abolition of the attacks of vertigo or at the very least a major diminution of the severity and frequency of the attacks.

Tinnitus

Seventy-five percent of cases experienced a major reduction or even abolition of the tinnitus soon after the procedure and with no recurrence of the tinnitus since surgery.

Since this analysis of the first 25 cases, an additional 50 cases have been carried out. The results have continued to be very satisfactory.

One case has had a vestibular nerve section because of severe recurrence. Of the 75 cases, nine cases have had a repeat gentamicin, and in two cases a third infusion of gentamicin was necessary in order to achieve a total abolition of their attacks of dizziness. This treatment has been successful even in patient's with very severe Meniere's disease who are experiencing drop attacks.

In general none of the successful cases have continued with medical management, eg. a low salt diet. Although these patients have been cautioned to observe a modest intake of salt.

References

1. James A L, Burton M J. Betahistine for Meniere's disease or syndrome. *Cochrane Database Syst Rev* 2001; (1):CD001873.
2. Tauber S, Jager L, Issing W J. Follow up assessment of intratympanic gentamicin therapy and saccotomia in Meniere's disease. *Laryngorhinootologie* 2002; 81(5):335-341.
3. Qvortrup K, Rostgaard J, Holstein-Rathlou N H, Bretlau P. The endolymphatic sac, a potential endocrine gland? Department of Medical Anatomy, University of Copenhagen, The Panum Institute, Denmark. *Acta Otolaryngol* 1999; 119(2):194-199.
4. Gibson W P, Arenberg I K. Pathophysiologic theories in the etiology of Meniere's disease. Department of Surgery, The University of Sydney, Australia. *Otolaryngol Clin North Am* 1997; 30(6):961-967.
5. Qvortrup K, Rostgaard J, Holstein-Rathlou N H. The inner ear produces a natiuretic hormone. Department of Medical Anatomy, University of Copenhagen, The Panum Institute, Denmark. *Am J Physiol* 1996; 270(6):F1073-1077.