

THEME

Gynaecological malignancies



Alison H Brand

MD, FRCS(C), FRANZCOG, CGO, is a certified gynaecological oncologist, Westmead Hospital, New South Wales. alisonb@westgate.wh.usyd.edu.au

The woman with postmenopausal bleeding

BACKGROUND

Postmenopausal bleeding is a common complaint from women seen in general practice.

OBJECTIVE

This article outlines a general approach to such patients and discusses the diagnostic possibilities and their management.

DISCUSSION

The most common cause of postmenopausal bleeding is atrophic vaginitis or endometritis. However, as 10% of women with postmenopausal bleeding will be found to have endometrial cancer, all patients must be properly assessed to rule out the diagnosis of malignancy. Most women with endometrial cancer will be diagnosed with early stage disease when the prognosis is excellent as postmenopausal bleeding is an early warning sign that leads women to seek medical advice.

Postmenopausal bleeding (PMB) is defined as bleeding that occurs after 1 year of amenorrhea in a woman who is not receiving hormone therapy (HT). Women on continuous progesterone and oestrogen hormone therapy can expect to have irregular vaginal bleeding, especially for the first 6 months. This bleeding should cease after 1 year. Women on oestrogen and cyclical progesterone should have a regular withdrawal bleeding after stopping the progesterone.

Patients requiring investigation include:

- women with any postmenopausal bleeding, spotting or vaginal discharge if not on HT
- women on continuous combined HT who have bleeding 6 months after starting treatment, and
- women on cyclical HT who have bleeding outside the expected time of withdrawal bleed.

Postmenopausal bleeding may be caused by the following:

- hormone (oestrogen) therapy
- atrophy of the vagina or uterus
- uterine or cervical polyps
- endometrial hyperplasia

- cancer of the uterus, cervix, or vagina (*Table 1*).

Endometrial or vaginal atrophy is the most common cause of PMB but more sinister causes of the bleeding such as carcinoma must first be ruled out. Patients at risk for endometrial cancer are those who are obese, diabetic and/or hypertensive, nulliparous, on exogenous oestrogens (including tamoxifen) or those who experience late menopause¹ (*Table 2*).

Assessment

The majority of women diagnosed with endometrial cancer present with vaginal bleeding or discharge. Most women recognise that this is abnormal and seek medical advice as a result. Abnormal postmenopausal bleeding should always be taken seriously and investigated, no matter how minimal or insignificant it may appear.

Initial assessment by the general practitioner should include a complete history with assessment of risk factors, as well medication history covering use of oestrogen, tamoxifen or anticoagulants. It is also important to inquire about any nonprescription medications such as phytoestrogens.

Examination

Clinical examination should include abdominal examination, looking for abdominal masses. A speculum examination should be performed to allow assessment of atrophic vaginitis and to rule out tumours of the cervix, vagina or vulva, or cervical polyps. A Pap smear should be taken if there is any suspicion of an abnormality on the cervix (note: this is a diagnostic test not a screening test and therefore the presence of blood is irrelevant). The finding of atrophic vaginitis or an endocervical polyp should not be accepted as the explanation of the bleeding without further assessment of the endometrial cavity.

Bimanual examination should be performed to assess uterine size, mobility and position before performing endometrial biopsy. Cervical or vaginal masses that were not seen on speculum examination may be palpated, as well as detection of adnexal masses. Rectovaginal examination allows detection of nodularity in the cul de sac. Abnormal bleeding should NEVER be an excuse, on the part of either the patient or the doctor, not to perform an examination, as it is usually indicative of a problem.

Biopsy

The gold standard for diagnosis of any malignancy is tissue biopsy. Endometrial office biopsy can be easily performed in most patients (with the exception of those with cervical stenosis) with only minor discomfort or cramping in most cases. (An antiprostoglandin administered 1 hour before the procedure can reduce cramping.) Endometrial office biopsies are usually performed by a gynaecologist rather than the GP. Technically, it is not a difficult procedure to learn or do, however, there is always the chance of complications such as perforation and infection (which the operator must then be able to deal with), and of course the GP must be confident in his/her ability to interpret the results. General practitioners could potentially undertake this procedure if they were interested in office gynaecological procedures, had appropriate training and medical defence cover.

The diagnostic accuracy of office endometrial biopsy for endometrial cancer is over 90% when compared to dilatation and curettage (D&C). A review of 13 598 D&Cs and 5851 office biopsies showed that adequacy of the specimens were comparable, but that D&C had a high complication rate.²

Hysteroscopy and biopsy should be reserved for cases in which office endometrial sampling cannot be performed due to cervical stenosis or patient discomfort, or where bleeding persists after negative office biopsy or where an inadequate specimen is obtained.

Table 1. Causes of postmenopausal bleeding¹⁴

Cause of bleeding	Frequency (%)
Endometrial or cervical polyps	2–12
Endometrial hyperplasia	5–10
Endometrial carcinoma	10
Exogenous oestrogens	15–25
Atrophic endometritis and vaginitis	60–80
Other (vaginal trauma, urethral caruncle, uterine sarcoma, cervical cancer, anticoagulants)	

Table 2. Relative risks for endometrial cancer¹⁴

Characteristic	Relative risk
Nulliparity	2–3
Late menopause (>age 52 years)	2.4
Obesity	
15–25 kg overweight	3
>25 kg overweight	10
Diabetes mellitus	2.8
Unopposed estrogen therapy	4–8
Tamoxifen	2–3
Atypical endometrial hyperplasia	8–29

Ultrasound

Transvaginal ultrasound is often recommended as a preliminary 'noninvasive' technique for assessing the endometrium in women with PMB. Unfortunately, it cannot give a definitive answer as to the presence or absence of malignancy, although it can sometimes be helpful in the assessment of uterine polyps. There is no consensus in the literature as to what the cut-off value for normal endometrial thickness should be. It has been reported as anywhere from 4–8 mm. Obviously the lower the cut-off, the higher the sensitivity for detection of endometrial cancers and its precursors but at a cost of lower specificity and increased false positives.³ A normal endometrial thickness on ultrasound does not exclude endometrial cancer, especially in those with significant risk factors. A suggested algorithm for the management of abnormal vaginal bleeding is presented in *Figure 1*.

Differential diagnosis

Atrophic vaginitis/endometritis

The diagnosis of atrophic vaginitis is made when speculum examination reveals a thin, friable vaginal wall that may

bleed upon opening the speculum.

Women with atrophic endometritis usually have been postmenopausal for over 10 years. There is often minimal tissue or just mucous and blood on endometrial biopsy. Treatment is topical or systemic oestrogens. The addition of progesterone is needed if using systemic oestrogens with an intact uterus.

Cervical polyps

Endocervical polyps are more common than ectocervical polyps. They appear as red protrusions from the cervical os. They can usually be easily removed in the office by grasping with sponge forceps and twisting on their pedicle. Any bleeding can usually be stopped with cautery or Monsel's solution. The polyp should be sent for pathological examination.

Endometrial polyps

The incidence of endometrial polyps varies with age, reaching a peak in the fifth decade of life.⁴ Because they are oestrogen sensitive, their incidence declines after menopause. They are also associated with tamoxifen use and are the most common abnormality seen with tamoxifen use.⁵ Rarely, endometrial polyps may undergo malignant change into a carcinoma or sarcoma.

Hysteroscopy can identify endometrial polyps by direct

visualisation. Saline infusion sonograms have been used to identify the polyps that show up as filling defects. Pelvic ultrasound usually does not reveal endometrial polyps unless they are particularly large. Treatment is removal during hysteroscopy. The specimen should always be sent for pathological assessment.

Endometrial hyperplasia

Endometrial hyperplasia covers a range of pathological changes in the uterine glands and stroma. Hyperplasia can be simple or complex, with or without atypia. The presence of atypia is the most worrisome feature as approximately 20% of those with atypical hyperplasia will have a concomitant endometrial carcinoma and a further 25–30% will develop endometrial hyperplasia within 2 years if the condition is left untreated.⁶

Hyperplasia without atypia can be treated with progesterone, with an expected response rate of 80%.⁷ Hyperplasia with atypia responds less well to progesterone treatment and definitive treatment in the postmenopausal woman should be hysterectomy with or without oophorectomy because of the risk of concomitant and future malignancy. Those patients medically unfit for surgery can be treated with high dose progesterone but need to be reassessed frequently with endometrial sampling to ensure reversal of changes.

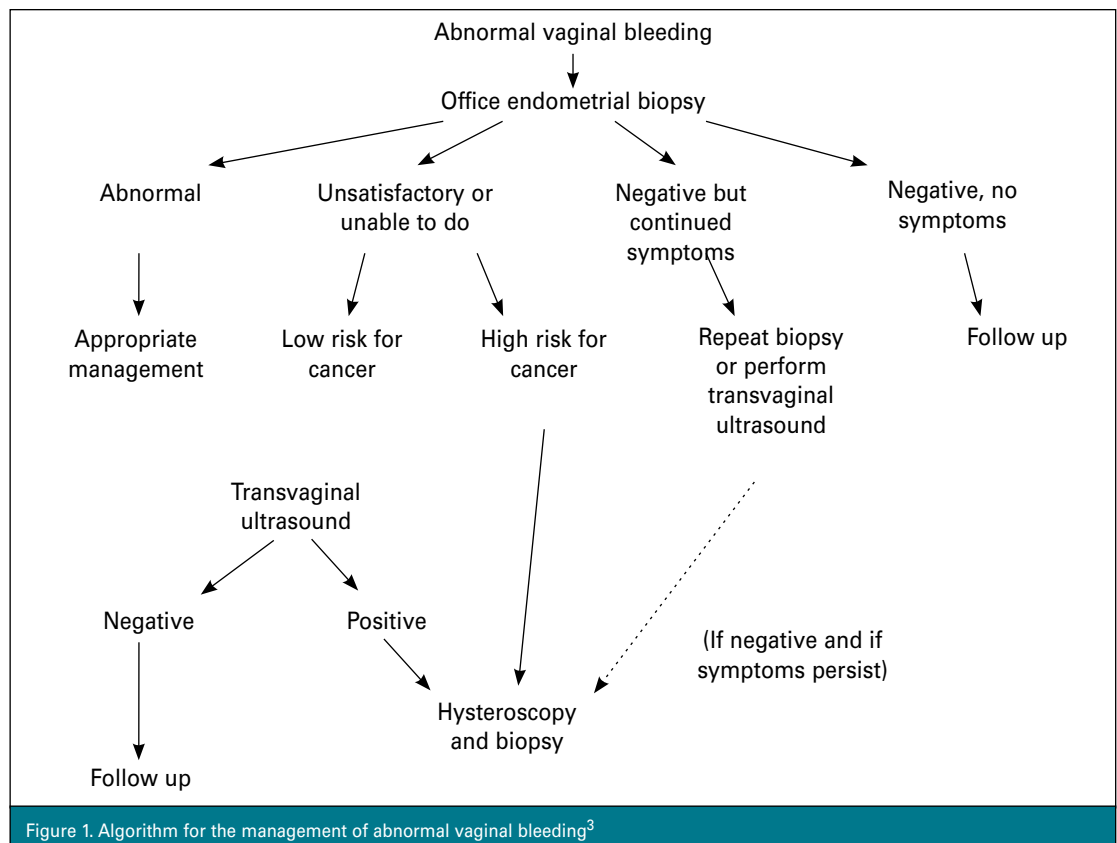


Figure 1. Algorithm for the management of abnormal vaginal bleeding³

Endometrial carcinoma

Over 90% of women with endometrial carcinoma present with vaginal bleeding. Other symptoms include irregular perimenopausal bleeding or heavy irregular bleeding in patients with anovulatory cycles. Rarely, abnormal endometrial cells are seen on a routine Pap smear in asymptomatic postmenopausal women.

Uterine cancer is the fifth commonest cancer in women in Australia and is the commonest cancer of the female genital tract. In 2001, there were 1537 new cases of uterine cancer in Australia and 299 deaths from uterine cancer, accounting for approximately 2% of all cancer deaths.⁸

Treatment

Treatment of endometrial carcinoma is almost always surgical. Staging is carried out at the same time and allows accurate assessment of extent of disease. Complete surgical staging should include peritoneal cytology, total abdominal hysterectomy, bilateral salpingo-oophorectomy, and bilateral pelvic and para-aortic lymphadenectomy. In reality, patients with low grade, noninvasive tumours have an extremely low risk of lymph node spread and do not routinely require lymphadenectomy. Unfortunately, although the grade of tumour is usually known before definitive surgery, myometrial invasion is not, and a decision regarding need for lymphadenectomy will need to be made intra-operatively. As the ability to perform lymph node dissection is outside the usual skill set of a general gynaecologist, referral to a gynaecological oncologist should be considered. The performance of lymphadenectomy allows accurate assessment of lymph node status and may avoid the necessity for adjuvant radiotherapy should the lymph nodes be negative.

In recent years there has been a move toward laparoscopic management of early stage endometrial carcinoma, primarily because of the benefits associated with laparoscopic surgery in general (ie. shorter hospital stay and quicker recovery). This is especially true for obese patients in whom open surgery can be difficult. To date, trials comparing open versus laparoscopic surgery have shown, as would be expected, shorter hospital stay, quicker return to normal activities, decreased requirements for analgesics and less overall complications.⁹ No trials as yet, have been large enough to answer the question as to whether prognosis is the same although there is an ongoing trial in Australia attempting to address this question.¹⁰

Complete surgical staging reduces the need for adjuvant radiotherapy. In surgically staged patients, adjuvant radiotherapy would be reserved only for patients with high grade, deeply invasive tumours, those with cervical spread or those with involvement of lymph nodes. The only randomised

Case study 1

A woman, 59 years of age, presents with complaints of spotting per vagina. On examination, a large 2 cm infarcted endocervical polyp is seen protruding from the endocervical canal. This is removed with a sponge forceps. Pathology is reported as a benign endocervical polyp. The bleeding continues and 3 months later she re-presents to her GP. An endometrial biopsy shows grade 2 endometroid adenocarcinoma.

Practice point: It is important to rule out other serious causes of postmenopausal bleeding even if a seemingly obvious cause is noted.

Case study 2

A woman, 52 years of age, presents with complaints of postmenopausal bleeding while on continuous combined HT after 1 year. Office endometrial biopsy reveals inadequate tissue. Hysteroscopy and D&C reveals atrophic endometrium with no polyps. Curettages are negative. Six months later, she represents with ongoing complaints of vaginal spotting. She remains on the HT. She has no risk factors for endometrial cancer. Endometrial biopsy is again negative with minimal tissue. Transvaginal ultrasound shows thin endometrium. The most likely explanation for the bleeding is felt to be the HT and she is switched to sequential HT. She has a regular withdrawal bleed and no irregular spotting.

Practice point: Ongoing spotting on HT, especially if it is continuous combined HT with adequate progesterone dose, is unlikely to be due to hyperplasia or malignancy. This should be investigated appropriately in the first instance, but in the absence of risk factors for endometrial cancer, switching the patient to sequential HT will usually alleviate the troublesome irregular spotting.

trial looking at the benefit of adjuvant radiotherapy showed a decrease in the risk of pelvic recurrence but no improvement in overall survival.¹¹

The most common histological type of endometrial cancer is endometroid, accounting for over 75% of all endometrial carcinomas. Other histological types include papillary serous, clear cell and carcinosarcoma (malignant mixed müllerian tumour) which all exhibit a much more aggressive behaviour.

Prognosis for endometrial carcinoma is usually good as most patients are diagnosed at an early stage. Those patients with stage 1 disease (ie. confined to the uterus) would be expected to have a greater than 85% 5 year survival (*Table 3*).

Screening for endometrial carcinoma, with either office endometrial biopsy or transvaginal ultrasound, has not been shown to be cost effective for the general population. It may confer some benefit for those patients with extreme risk, ie. hereditary nonpolyposis colon cancer carriers who have up to a 40% life time risk of endometrial cancer.¹² The Australian Cancer Network recommends that such patients at very high risk for endometrial cancer consider either

Table 3. FIGO staging of endometrial cancer and prognosis¹⁵

FIGO stage	Extent of disease	5 year survival
Stage I	IA: tumour limited to endometrium IB: invasion to less than half of the myometrium IC: invasion to greater than half the myometrium	} 85%
Stage II	IIA: endocervical gland involvement only IIB: cervical stromal invasion	} 70%
Stage III	IIIA: tumour invades serosa of uterus and/or adnexae, and/or positive peritoneal cytology IIIB: vaginal metastases IIIC: metastases to pelvic and/or para-aortic lymph nodes	} 40–60%
Stage IV	IVA: tumour invades bladder and/or bowel mucosa IVB: distant metastases including intra-abdominal spread or inguinal lymph nodes	} 10–20%

prophylactic surgery or screening with annual transvaginal ultrasound, although the efficacy of such screening has not been determined.¹³ It is acknowledged that this recommendation is based on expert opinion rather than definitive scientific evidence.

Summary of important points

- Postmenopausal bleeding should always be investigated, as 10% of patients will have endometrial carcinoma.
- The commonest cause of postmenopausal bleeding is an atrophic vaginitis or endometritis.
- Assessment of the endometrium with tissue pathology is essential, even if the presence of obvious atrophic vaginitis or cervical polyp.
- The prognosis for endometrial carcinoma is usually good as most patients present with early stage disease due to the early symptom of postmenopausal bleeding.

Conflict of interest: none declared.

References

1. Brinton LA, Berman ML, Mortel R, et al. Reproductive, menstrual and medical risk factors for endometrial cancer: Results from a case control study. *Am J Obstet Gynecol* 1992;167:1317–25.
2. Chambers JT, Chambers SK. Endometrial sampling. When? Where? Why? With what? *Clin Obstet Gynecol* 1992;35:28–39.
3. Brand A, Dubuc-Lissior J, Ehlen T, Plante M. Diagnosis of endometrial cancer in patients with abnormal vaginal bleeding. SOGC clinical practice guidelines. *J Soc Obstet Gynecol Can* 2000;22:102–4.
4. Van Bogaert LJ. Clinicopathologic findings in endometrial polyps. *Obstet Gynecol* 1988;71:771–3.
5. Deligdisch L, Kalir T, Cohen C, et al. Endometrial histopathology in

700 patients treated with tamoxifen for breast cancer. *Gynecol Oncol* 2000;78:181–6.

6. Kurman RJ, Kaminski PF, Norris HJ. The behavior of endometrial hyperplasia: A long term study of 'untreated' hyperplasia in 170 patients. *Cancer* 1985;56:403–12.
7. Ferenczy A, Gelfand M. The biologic significance of cytologic atypia in progesterone-treated endometrial hyperplasia. *Am J Obstet Gynecol* 1989;160:126–31.
8. Australian Institute of Health and Welfare (AIHW) and Australasian Association of Cancer Registries (AACR) 2004. *Cancer in Australia 2001*. AIHW Cat No. 23. Canberra: AIHW (Cancer Series No. 28).
9. Tollund L, Hansen B, Kjer JJ. Laparoscopic assisted vaginal vs. abdominal surgery in patients with endometrial cancer stage 1. *Acta Obstet Gynecol Scand* 2006;85:1138–41.
10. Janda M, Gebski V, Forster P, Jackson D, Williams G, Obermair A. LACE Trial Committee. Total laparoscopic versus open surgery for stage 1 endometrial cancer: the LACE randomised controlled trial. *Contemp Clin Trials* 2006;27:353–63.
11. Aalders J, Abeler V, Kolstad P, Onsrud M. Postoperative external irradiation and prognostic parameters in Stage 1 endometrial carcinoma. *Obstet Gynecol* 1980;56:419–46.
12. Burke W, Petersen G, Lynch P, et al. Recommendations for follow up care of individuals with an inherited predisposition to cancer. I. Hereditary nonpolyposis colon cancer. *Cancer Genetics Studies Consortium. JAMA* 1997;277:915–9.
13. Australian Cancer Network Colorectal Cancer Guidelines Revision Committee. Guidelines for the prevention, early detection and management of colorectal cancer. The Cancer Council Australia and Australian Cancer Network, Sydney 2005.
14. Lurain J. Uterine cancer. In: Berek JS, Adashi EY, Hillard PA, editors. *Novak's Gynecology* 12th ed. Baltimore: Williams & Wilkins, 1996:1057–110.
15. Hacker N. Uterine cancer. In: Berek JS, Hacker NF, editors. *Practical Gynaecological Oncology* 3rd ed. Lippincott Williams and Wilkins.