



Cutaneous manifestations of systemic disease

BACKGROUND While most patients who present with a rash have no associated systemic illness, many systemic illnesses have skin manifestations at some stage.

OBJECTIVE This article uses case vignettes to illustrate a problem oriented approach to five commonly presented skin conditions that have common and varied systemic associations. A logical sequence of management for each case is provided.

DISCUSSION Often the skin manifestations of systemic disease are vague and nonspecific such as the toxic erythema that might follow a viral infection or a drug eruption. Sometimes it is the systemic manifestations that are vague and nonspecific, while the skin manifestations are highly specific and define the illness. There is currently no useful classification for cutaneous manifestations of systemic disease.

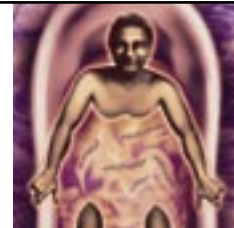
While most patients who present with a rash have no associated systemic illness, many systemic illnesses have skin manifestations at some stage. Examples include lymphoma, connective tissue disease, inflammatory bowel disease, and diabetes.

Often the skin manifestations of systemic disease are vague and nonspecific such as the toxic erythema that might follow a viral infection or a drug eruption. Sometimes it is the systemic manifestations that are vague and nonspecific, while the skin manifestations are highly specific and define the illness. Examples include smallpox, varicella, measles, rubella, and Reiter disease.

Almost all skin conditions can have a systemic association. Examples include the onset of psoriasis and seborrheic dermatitis in HIV, atopic dermatitis

in Job syndrome, itch as a manifestation of Hodgkin disease, and acne with Cushing disease. Almost any rash can be caused by drugs including psoriasis, seborrheic dermatitis, acne, rosacea, lichen planus, erythema multiforme, bullous pemphigoid and pseudolymphoma.

As a result there is no useful classification available for the cutaneous manifestations of systemic disease. Therefore, instead of trying to unnecessarily simplify that which is truly complex, we have decided to take a somewhat different approach with this article. Rather than produce multiple tables with long lists of diagnoses we have taken a problem oriented approach to five skin conditions – as they might present to a general practitioner – that have common and varied systemic associations.



Jennifer Cahill,

MBBS, is a dermatology professional registrar, St Vincent's Hospital, Victoria.



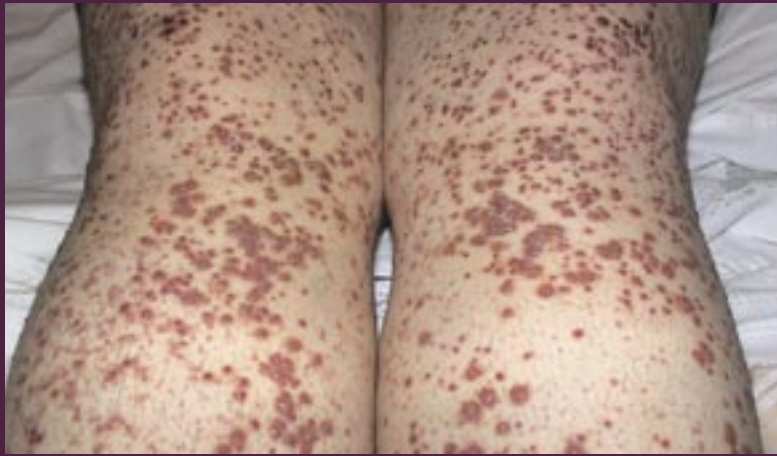Rodney Sinclair,

MBBS, FACD, is Professor of Dermatology, University of Melbourne, Director of Dermatology Services, St Vincent's Hospital, Melbourne, and Director, Research and Training, Skin and Cancer Foundation of Victoria
rod.sinclair@svhm.org.au

Dependent palpable purpura

Case 1

A woman, 32 years of age, presented with a 1 week history of red, well demarcated, nonblanching purpura on her lower legs and ankles. The possible cause varies from banal to life threatening. Systemic involvement may be minimal or severe. A diagnostic algorithm is useful in this setting.



Step 1. Is this vasculitis or thrombocytopenic purpura?

Palpation of the purpura is highly discriminating in this context, with palpable purpura indicating vasculitis.¹ Often it is best to lightly run your index finger over the rash with your eyes closed, as this can be a subtle sign. Irrespective of your impression on examination, a platelet count should be routine.

Nonpalpable purpura can also occur with an itchy dermatosis on the lower legs in the context of venous insufficiency. Scratching may lead to occasional purpura that are often linear. The presence of the original rash is also a clue to this diagnosis.

Step 2. Is this allergic vasculitis or septic vasculitis?

Septic vasculitis occurs with meningococcaemia and rarely with gonococcaemia. Patients may develop the rash before they become obviously unwell. If you always think of this possible diagnosis and always check the patient's temperature then you will only miss this diagnosis occasionally. If in doubt, the recommended protocol is an immediate dose of benzylpenicillin (intramuscular or intravenous [IV]) or ceftriaxone (IV) and immediate transfer of the patient to hospital.² It is often best not to wait for an ambulance. If possible, blood cultures or aspirates from the centre of a purpuric lesion should be collected before administration of the antibiotics.

Step 3. Is this Henoch Schönlein purpura?

Two skin punch biopsies are required: one for routine haematoxylin and eosin (H&E) staining to confirm the diagnosis of vasculitis and the second sent fresh for

direct immunofluorescence (IF). Vasculitis has a highly specific histology with perivascular neutrophils, disrupted neutrophils (leukocytoclasia) and endothelial cell swelling. A biopsy should always be done in cases of suspected vasculitis. Henoch Schönlein purpura can only be diagnosed when the direct IF is positive for IgA. Henoch Schönlein purpura is an important diagnosis to make for prognostic reasons and direct IF is strongly recommended.

Step 4. What is the cause of allergic vasculitis?

There are numerous possible causes, however after appropriate investigation approximately 30–50% of patients will remain idiopathic.^{2,3} Specific syndromes include polyarteritis characterised by a positive perinuclear antibodies against neutrophils (pANCA) test, connective tissue disease characterised by a positive antinuclear antibody or rheumatoid factor, drugs, postinfective (especially streptococcal infection with a positive anti-DNase B, hepatitis B and C), and malignancy (either solid or more commonly haematological, eg. myeloma).

Occasionally a small vessel vasculitis that produces purpura may accompany a large vessel vasculitis such as Wegener's (characterised by a positive cytoplasmic ANCA) or polyarteritis nodosa, which is a separate and distinct condition from polyarteritis.

When the purpura is most pronounced on the extremities (ie. feet, toes) one should consider deposition of temperature sensitive antigen complexes (cold agglutinins, cryofibrinogen, cryoglobulins) that may sometimes accompany paraproteinaemia. Testing requires prior communication with the laboratory.

A logical sequence of management for this patient would include the following investigations and/or procedures.

Establish the diagnosis and rule out differential diagnoses:

- palpate purpura
- check temperature and assess if patient is unwell
- perform full blood examination (FBE) to check platelets
- skin biopsy
- direct IF on skin biopsy.

Identify the cause:

- pANCA
- streptococcal serology or throat swab (especially in children)
- erythrocyte sedimentation rate (ESR), urea and electrolytes (U&E), liver function tests (LFTs)

- other investigations directed by findings on history including hepatitis serology, rheumatoid factor, cryoglobulins, immunoglobulins, antinuclear factor (ANF), total complement levels and serum protein electrophoresis.

Assess the extent of the vasculitis:

Further investigations should be directed toward investigating relevant systems:

- renal – urinalysis looking for proteinuria and haematuria
- gastrointestinal – abdominal pain, gastrointestinal bleeding
- musculoskeletal – nonerosive polyarthritits
- pulmonary – pleural effusion
- cardiac – pericardial effusion.

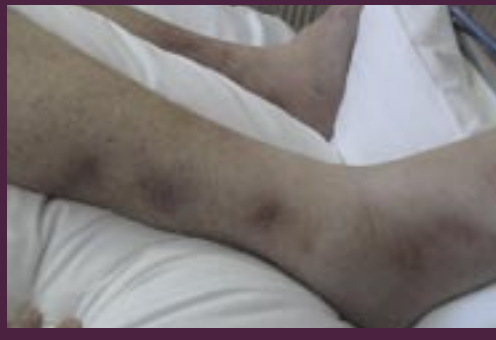Management

The general principles of management for vasculitis include rest, elevation of the legs and compression hosiery. Systemic therapy is often indicated if the vasculitis is extensive, painful, ulcerating, or if there is renal involvement. The cause of the vasculitis should be managed as appropriate.

Red dermal nodules on shins

Case 2

A young man, 18 years of age, presented with discrete, painful, tender, erythematous nodules on his shins associated with fever, aching wrist joints and malaise. The nodules persisted for about 2 weeks and gradually resolved leaving bruising on his shins where the nodules had been.



Step 1. Is this panniculitis?

Panniculitis is an inflammation of the subcutis and often also the deep dermis. The epidermis is not involved and, while the skin may be red, it is not scaly or vesiculated or excoriated. The skin surface markings are intact.

A biopsy is very useful, but must include fat (incisional

biopsy). Sarcoid can directly involve the skin and produce a similar appearance. Dermal infiltrates such as nodular pretibial myxoedema can sometimes be confusing.

Step 2. Is this a septal panniculitis?

Panniculitis can be classified histologically either as septal (inflammation centred around the fibrous septa between lobules), lobular (inflammation centred in the fat lobules), or mixed. The causes of panniculitis are similar to those of vasculitis, however the list is longer. Life threatening forms of panniculitis often occur on the trunk and proximal limbs as well as dependant sites. Most forms of panniculitis are lobular. Erythema nodosum (EN) produces a septal panniculitis. Biopsy is recommended in all but classic cases to establish the histological subtype.

Step 3. What is the cause of this patient's EN?

Erythema nodosum most often occurs as a reaction to a systemic illness. While many cases are idiopathic and some are drug induced (especially by the oral contraceptive pill and sulphur drugs), the most common causes in Australia are streptococcal pharyngitis, sarcoidosis and inflammatory bowel disease (ulcerative colitis more commonly than Crohn disease).² Tuberculosis and other infections such as yersinia, chlamydia and hepatitis B are rare causes.

A logical sequence of management for this patient would include the following investigations and/or procedures.

Establish the diagnosis and rule out differential diagnoses:

- Incisional skin biopsy that includes subcutaneous fat. Classic cases of EN may not require a biopsy.

Identify the cause:

- streptococcal serology or throat swab
- chest X-ray (sarcoidosis and tuberculosis)
- FBE
- Mantoux test.

Assess the extent of systemic disease:

- ESR
- other investigations based on initial findings, eg. staging for Hodgkin disease.

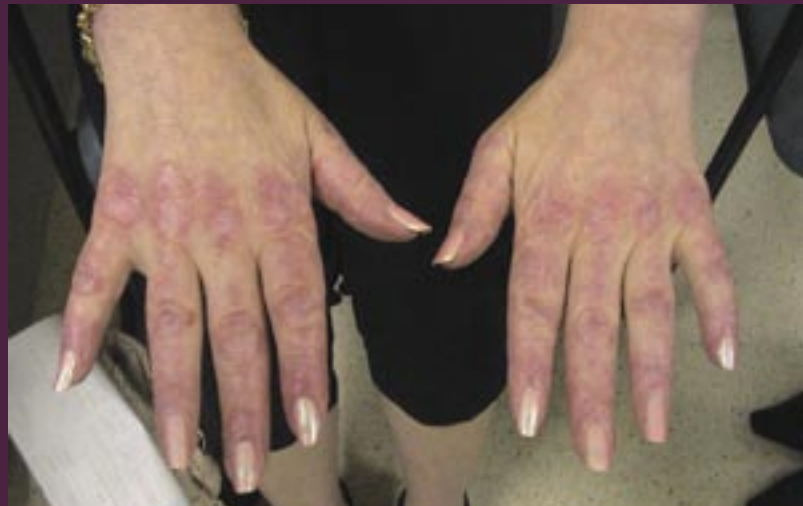Management

Erythema nodosum is a self limiting condition. Management includes rest and elevation of the legs and nonsteroidal anti-inflammatory drugs (NSAIDs). Prednisolone may be used in severe cases for symptomatic relief once tuberculosis has been ruled out.

Photosensitive facial rash

Case 3

A woman, 45 years of age, presented with a macular, erythematous, scaly rash on her face that was exacerbated by sunlight. Her upper eyelids and beneath her nose and chin were spared, but she also had erythema on her anterior neck, and on the dorsa of her hands.



Step 1. Is the rash exacerbated by the sun?

Rosacea and seborrhoeic dermatitis are the commonest facial rashes. Rosacea affects up to 40% of women at some stage in their life. Seborrhoeic dermatitis occurs in up to 70% of young adults, however most only get dandruff. Rosacea is highly variable in its appearance. Many patients get no pustules, just erythema or flushing. The flushing is often heat induced and this is commonly wrongly attributed by patients to sun exposure. Facial seborrhoeic dermatitis is often, but not always, accompanied by dandruff.

Step 2. Is this a photosensitive facial rash or a photoexacerbated dermatosis?

Many facial rashes such as seborrhoeic dermatitis, atopic dermatitis, psoriasis and rosacea can worsen with sun exposure in some people. The cause is unknown, but there is usually a long history of the pre-existing rash. The distribution of these rashes is often not strictly that of a photosensitive eruption.

Step 3. Is this a true photosensitivity or phototoxicity?

Many drugs sensitise people to sunlight. People taking medications including doxycycline, isotretinoin and antipsychotics will burn more quickly in the sun. Certain plants such as compositae (eg. daisies) can produce a photoallergic rash known as chronic actinic dermatitis.

With true photosensitivity, patients develop an erythema after minimal sun exposure and sometimes only 1–2 minutes of exposure is required. Causes of true photosensitivity include connective tissue diseases such as systemic lupus erythematosus (SLE) and dermatomyositis (DM), and porphyria. Dermatomyositis can occur without myositis and is usually associated with an occult malignancy such as colon, stomach, breast or nasopharyngeal carcinoma.²

A logical sequence of management for this patient would include the following investigations and/or procedures.

Confirm the diagnosis and exclude differentials:

- full skin examination to assess if the rash is only in sun exposed areas, or if there is involvement of covered areas
- skin biopsy for histopathology and direct IF (in SLE) direct IF is positive for IgM
- auto-antibody screen including antinuclear antibodies (present in: >95% of SLE patients, 60% of DM patients),⁴ extractable nuclear antigens, double standard DNA antibodies (specific for SLE)
- creatinine kinase (elevated in 60–90% of patients with DM) should be done if patients have proximal weakness⁵
- aldolase and lactate dehydrogenase can also be elevated in DM, but should only be tested if DM is strongly suspected.

Assess the extent of disease:

- U&E, urinalysis and 24 hour urine collection (persistent proteinuria in SLE, elevated creatinine clearance in DM)
- FBE (anaemia, lymphopenia and thrombocytopenia can occur in SLE)
- ESR (elevated in SLE and can indicate activity of the disease).

Establish a cause or association:

- investigations for associated malignancy in DM (carcinoma of the breast, ovary, lung, gastrointestinal tract)
- muscle biopsy in DM if signs of muscle involvement
- monochromatic and broadband light testing (to demonstrate an abnormal reaction to light) for chronic actinic dermatitis
- ECG (in DM may show evidence of myocarditis, atrial or ventricular irritability, atrioventricular block).

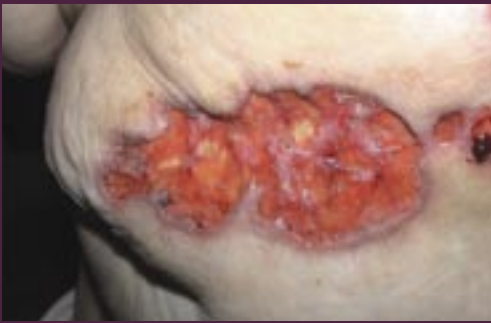Management

Sun protection is important including sunscreen, hat, protective clothing and tinted glass or Perspex windows (if UVA sensitive). Topical steroids can also be useful.

Alleged white tail spider bite

Case 4

A woman, 55 years of age, presented with a painful ulcer, increasing in size, on her left lower flank. It began as small, painful papule after the patient had spent the day gardening. A neighbour had said she heard that there were white tail spiders in the area.



Step 1. Was she bitten by a spider?

The general consensus is that the poor white tail spider is a badly maligned creature. A number of authors have reviewed the case reports of alleged white tail spider bites and adjudged them to have little or no academic substance.⁶ Rarely has a white tail spider been seen or captured at the 'scene of the crime'. Most cases are in fact due to either cellulitis or pyoderma gangrenosum (PG).

Step 2. Is this pyoderma gangrenosum?

Pain is a characteristic feature of PG, however skin infections can also be painful. Other differential diagnoses that should be considered include infections (especially atypical mycobacteria), deep fungal infection and botryomycosis, venous stasis ulcers (especially if secondarily infected) and malignant ulcers (either basal cell or squamous cell carcinoma, including Marjolin type).

Step 3. What is the cause of PG?

Pyoderma gangrenosum can be associated with a number of systemic conditions including:

- ulcerative colitis and Crohn disease
- inflammatory arthritis, eg. rheumatoid arthritis
- paraproteinaemia and myeloma
- haematological malignancies

- chronic active hepatitis.

An underlying association is not found in up to 30% of cases.³

A logical sequence of management for this patient would include the following investigations and/or procedures.

Establish a cause and exclude differential diagnoses:

Incisional biopsy for both histopathology and culture. The histopathology of PG is variable and nonspecific, and the diagnosis is often one of exclusion. Culture is essential to exclude an infective cause of the ulcer, especially as the treatment of PG involves potent systemic immunosuppressive agents.

Assess the extent of disease and establish an association:

Appropriate investigations can be performed directed toward identifying an underlying cause. Apart from this, PG is localised to the skin and soft tissues, and further investigations are generally not required.

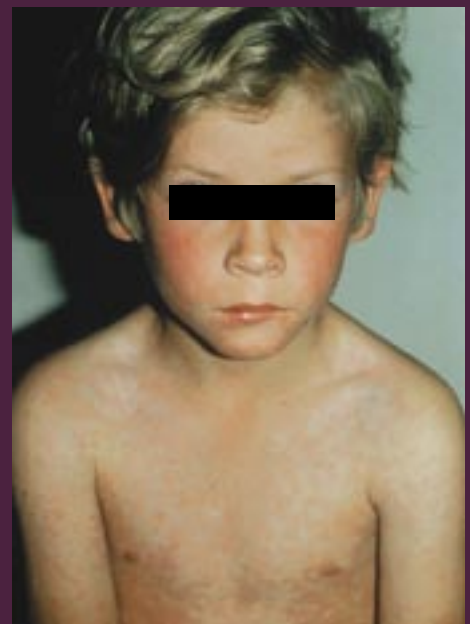Management

Systemic immunosuppression, initially in the form of prednisolone, is likely to be needed and can be started once tissue culture results have excluded atypical infection.

Toxic erythema

Case 5

A child, 13 years of age, presented with a generalised, erythematous nonpruritic macular rash.



Step 1. Does the patient have a fever or look unwell?

The sudden appearance of a rash and fever is a common general practice presentation. Early in the evolution of the rash, distinctive morphological features may not be present. For example, a patient with evolving acute generalised pustular dermatosis (AGEP) may present with widespread erythema alone. The pustules often occur within 24 hours of administration of the causative drug. The desquamation of toxic shock syndrome may not occur for 2 weeks and is often confined to the hands. With Kawasaki disease, the eyes and mouth are usually involved at presentation, and the erythema of the palms and soles is an important clue. With scarlet fever, the rash is initially a punctate erythema that generalises over 3–4 days and is followed by truncal and acral desquamation after 7–10 days. Staphylococcal scalded skin syndrome only occurs in infants and patients with severe renal impairment unable to excrete the toxin.

Drug hypersensitivities vary from the benign to life threatening. Patients tend only to be febrile with the more severe forms (*Table 1*). Mucosal involvement usually coincides with the development of the rash of Stevens-Johnston syndrome, while in erythema multiforme minor the mucosal involvement is often minimal. Toxic epidermal necrolysis has a prodrome of flu-like symptoms for 2–3 days and then macular erythema followed by sloughing of sheets of entire thickness epidermis.

Step 2. Did the patient have a mild febrile illness or upper respiratory tract infection 10–14 days earlier that has now resolved?

The most common causes of toxic erythema in the community are viral exanthems that are nonspecific. Often these patients have received treatment for their recent infection and developed drug hypersensitivity. For example initial penicillin allergy often develops 10–14 days after commencement of therapy. Repeat exposure leads to relapse of the rash usually within 1–2 days.

In addition, patients with infectious mononucleosis (IM) or chronic lymphocytic leukaemia are prone to develop a toxic erythema following ampicillin therapy. This is not a true penicillin allergy and re-exposure to ampicillin after the IM has passed does not tend to lead to recurrence of the rash.

A logical sequence of management for this patient would include the following investigations and/or procedures.

Assess the patient to see if they are unwell:

- detailed history
- skin biopsy (essential when a definitive diagnosis is required, or a serious illness is suspected)
- blood culture if toxic shock syndrome is suspected or cannot be excluded.

Establish the cause:

- streptococcal serology or throat swab (scarlet fever)
- monospot test or serology for IM
- FBE.

Assess the extent of disease:

Guided by results of initial findings and investigations.

Table 1. Signs of a serious drug eruption¹

- Signs of a serious drug eruption:
- High fever
 - Sore throat
 - Gritty eyes, photophobia or mouth ulcers
 - Swollen, tender lymph glands
 - Malaise, myalgia, arthralgia/arthritis
 - Headache, neck stiffness
 - Dyspnoea, cough, rhinorrhoea, ear pain, skin tenderness

Management

In the case of a drug eruption, minor reactions can be managed by identifying the drug involved and ceasing its use. Re-challenge with a suspected drug is generally not advised. Serious drug eruptions or undiagnosed febrile illnesses require early hospital referral.

Conflict of interest: none declared.

References

1. Lawrence CM, Cox CH. Physical signs in dermatology. 2nd ed. London: Mosby, 2002;310.
2. Therapeutic Guidelines. Dermatology. Version 2. Melbourne: Therapeutic Guidelines Ltd, 2004.
3. Textbook of dermatology. Burns T, Breathnach S, Cox N, Griffiths C, editors. 7th ed. Oxford: Blackwell Science, 2004.
4. Magro CM, Crowson AN. The immunofluorescent profile of dermatomyositis: a comparative study with lupus erythematosus. J Cutan Pathol 1997;24:543–52.
5. Klippel JH, Dieppe PA, editors. Rheumatology. 2nd ed. London: Mosby, 1998; 7:13.8
6. Isbister GK, Gray MR. White tail spider bite: a prospective study of 130 definite bites by Lampona species. Med J Aust 2003;179:199–202.

Email: afp@racgp.org.au

AFP