



Stuart M Lyon

MBBS, FRANZCR, is Head, Vascular and Interventional Radiology, Alfred Hospital Melbourne, Victoria. s.lyon@alfred.org.au

Karda Cavanagh

BMed(Hons), FRACGP, GAICD, is a general practitioner, Monash Caulfield Health Service, Victoria.

Uterine artery embolisation

A treatment alternative for women with fibroids

BACKGROUND

Fibroids are a common benign tumour of the female reproductive tract. Uterine artery embolisation is a minimally invasive catheter based technique that compares favourably with surgical treatments.

OBJECTIVE

Uterine artery embolisation is an intervention that is especially suited to women who wish to preserve their uterus. This article briefly outlines the medical and surgical treatment options for fibroids with an in depth focus on fibroid embolisation.

DISCUSSION

Australian interventional radiologists have been performing uterine artery embolisation for fibroid disease successfully for a number of years. This procedure – like any intervention – is not without complication, but it does enable women a valid alternative treatment pathway for fibroids. General practitioners can discuss the procedure with their local interventional radiologist and can foster a broader understanding of the process with their female patients when considering treatment options.

Uterine fibroids are the commonest tumour of the female reproductive tract, affecting almost 30% of women in their reproductive years.^{1,2} Fibroids are the most frequent reason for hysterectomy in premenopausal women. It is difficult to obtain Australian estimates of the cost of fibroid disease, but in the United States more than \$2 billion is spent in annual hospital charges alone.²

Symptoms of fibroid disease

Symptoms associated with fibroids have a significant impact on quality of life.² Uterine fibroids cause symptoms through a mass effect: frequency, urgency and/or constipation, swelling/bloating, sciatica; and through abnormal uterine bleeding, dysmenorrhoea, menorrhagia, and anaemia.³ Uterine fibroids have also been associated with infertility.⁴

Medical and surgical treatment options

Each treatment option for fibroid disease has advantages and disadvantages. One of the major decisions that a

woman needs to make when considering treatment options is whether she would prefer to keep her uterus.

Uterus removal

The traditional treatment for fibroids is hysterectomy. Hysterectomy rates in Australia are approximately 30 000 per year. Twenty-two percent of hysterectomies in Australia are performed for fibroids, with a further 18% for menorrhagia.⁵ The main advantage of hysterectomy is that it treats the problem of fibroids definitively. The disadvantages are the complications associated with surgery: haemorrhage, infection, other organ injury, thromboembolic episodes, deep venous thrombosis and pulmonary embolism; and psychological issues associated with uterus removal and the loss of childbearing potential.⁵ Women require approximately 38 days to resume normal activities posthysterectomy.⁶

Uterus sparing

Gonadotropin releasing hormone (GnRH) therapy

is a medical treatment that suppresses oestrogen production, shrinking fibroids and thereby assisting in fibroid removal at hysteroscopy. Therapy induces menopausal symptoms and is associated with fibroid regrowth when therapy is ceased.⁷ GnRH therapy is also relatively expensive.

Myomectomy (both laparoscopic and open) enables the removal of fibroids while allowing uterus conservation. A general anaesthetic is required. Adhesions may cause problems postoperatively and the recurrence rate of fibroid regrowth is 10–27%.⁷ Hysteroscopic resection and/or endometrial ablation involves resection of submucous fibroids and endometrial scraping and burning to create amenorrhea. This can be performed as an outpatient procedure with short recovery times. However, there is a significant recurrence rate of fibroids at 2 years (32%⁸) with the majority then managed by hysterectomy. There is also a high rate of adenomyosis (52%⁹), possibly caused by ablation, which has a negative impact on fertility.

Uterine artery embolisation

Uterine artery embolisation (UAE) is a radiological intervention that treats the entire fibroid uterus while preserving the uterus. The procedure was originally performed in the 1980s in Paris to minimise blood loss from larger fibroids during surgery. However, it was discovered that many of these patients were asymptomatic following embolisation. Since 1995, over 25 000 UAEs as treatment for symptomatic fibroids have been performed worldwide.¹⁰ Fertility rates post-UAE appear similar to patients undergoing myomectomy.¹¹

The procedure

Fibroid or uterine artery embolisation is performed as a day procedure by an interventional radiologist. The procedure can be organised through contacting a tertiary referral hospital. It is important for the patient to see a gynaecologist in the work up for UAE to ensure there is no malignant cause of dysmenorrhoea and in the uncommon event of a complication subsequently requiring hysterectomy.

Via the right common femoral artery both left and right uterine arteries are cannulated (*Figure 1a, b*). Embolisation is performed by injecting polyvinyl alcohol particles until there is a cessation of vascular flow. This results in the infarction of the fibroids and temporary ischaemia of the uterus. The procedure usually takes under 1 hour. The mean radiation exposure in a large series of UAEs performed in the United Kingdom was approximately the same as that incurred in a barium enema.³

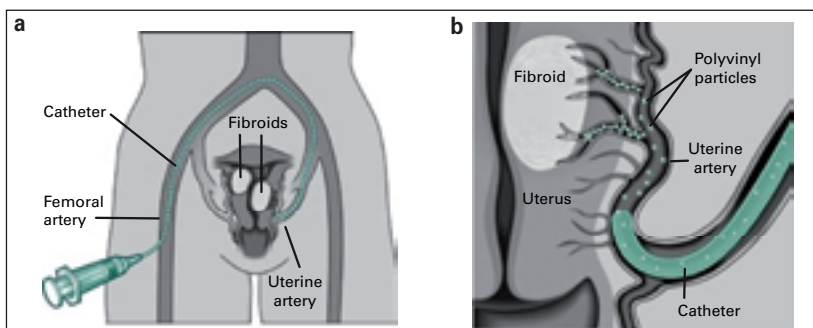


Figure 1a, b. Cannulation of left and right arteries. Images courtesy Society of Interventional Radiology

Results

Post-UAE, fibroids undergo necrosis and will reduce significantly from their original volume, thereby reducing the symptoms associated with the mass effect. It is also believed that removal of vascular engorgement plays a role in the removal of symptoms. Patients undergoing UAE are generally satisfied with the procedure. In a series of 400 UAEs, 97% of patients were pleased with the outcome and would recommend the treatment to others.³

Hospital stays for the procedure are less than hospital stays for hysterectomy.¹² For UAEs, stays are usually less than 48 hours,^{7,13} whereas hospital stays for hysterectomy are approximately 6 days.⁷ Postprocedure, women return to normal activities within 14 days and the mean number of days off for women who work outside the home is 10 days, including the procedural day.¹³ Narcotic use for pain relief can be up to 5 days for UAE, however this compares favourably with myomectomy at nearly 9 days.¹⁴ When comparing myomectomy with UAE, women who underwent UAE reported a complete or significant resolution of menorrhagic symptoms (92%) versus myomectomy (64%).¹⁵

Uterine artery embolisation pregnancy rates are similar to myomectomy,¹¹ however, long term data is lacking. Uterine artery embolisation is more effective than myomectomy in symptom control however, and slightly less effective than hysterectomy. A comparison of outcomes is shown in *Table 1*.

Indications for UAE

Indications for UAE are women with symptoms consistent with fibroid disease and uterine fibroids confirmed by ultrasonography or magnetic resonance imaging (MRI).^{19,20}

Contraindications

The absolute contraindications to UAE include active infection, viable pregnancy, and leiomyosarcoma or adnexal malignancy unless it is for palliation. Relative contraindications to UAE include coagulopathy, severe contrast material allergy and renal impairment.¹⁹

Table 1. Comparison of outcomes^{15–18}

Comparison of outcomes	Hysterectomy	Myomectomy	UAE
Bleeding cessation at 6 months	100%	64%	86%
Bulk/pressure symptoms improvement	80–94%	91%	80–83%
Pelvic pain improvement	98%	54%	74–84%
Hospital stay (mean)	2.3–7.3 days	2.9–3.6 days	0–3.6.0 days
Return to normal activities	33–36 days	36 days	8–14 days
No further treatment for fibroids	100%	90%	87–99%

Table 2. Comparison of complications^{15–18}

Comparison of complications	Hysterectomy %	Myomectomy %	UAE %
Haemorrhage	1–30	8–13	0
Thromboembolism	5	2	0.5
Rehospitalisation and/or re-operation	5–12	3	1–5
Local infection	10–24	5–31	0–22

Complications/adverse events

The largest series to date found an overall peri-procedural complication rate of 8.5% and a 1.25% serious complication rate.¹⁹ The most common peri-procedural adverse event was pain. This required supplementary therapy as an outpatient or readmission (2.1%).¹³ Complications from UAE include:

- passage of fibroid (most common complication 2.5%)
- postembolisation syndrome (self limiting cramping pelvic pain, nausea and low grade temperature related to ischaemia and infarction of the fibroid)
- endometritis
- infection
- premature ovarian failure
- deep venous thrombosis
- pulmonary embolism
- nontarget embolisation
- hysterectomy
- fibroid regrowth.^{10,13,19}

In their review of 25 000 UAEs, Kitamura et al¹⁰ found only two reported deaths, one caused by septicaemia and the other by pulmonary embolus. The US Fibroid Registry, which has logged the outcomes of 3160 women undergoing UAE, recorded a postprocedure hysterectomy rate of 0.1%.¹³

Complications from hysterectomy include:

- major haemorrhage (requiring transfusion)
- unintentional organ damage
- pulmonary embolus
- deep venous thrombosis
- major anaesthetic problem
- unintended laparotomy
- infection
- haematoma
- death
- wound dehiscence.²¹

A comparison of some of the complications is outlined in *Table 2*.

Follow up

Patients are usually discharged within 24 hours of the procedure. All patients need to be followed up by their general practitioner and radiologist to ensure that there are no complications and to check outcomes. If a patient develops a temperature more than 38°C and if she has increasing pain, she should be admitted to hospital for a septic work up.³ It is important to note that fibroid expulsion can occur up to 12 months after the procedure.³

Conclusion

Uterine artery embolisation is an effective treatment for fibroid disease with fewer major complications compared to hysterectomy and myomectomy. Uterine artery embolisation necessitates a shorter hospital stay than myomectomy or hysterectomy. The resumption of normal activities post-UAE occurs in half the time of that for women posthysterectomy. Women report a high level of satisfaction with the procedure. Women in Australia considering their options for the treatment of fibroid disease should be offered UAE as a treatment alternative.

Conflict of interest: none declared.

References

1. Lumsden MA. Embolisation versus myomectomy versus hysterectomy. Which is best, when? *Hum Reprod* 2002;17:253–9.
2. Myers ER, Barber MW, Couchman GM, et al. Management of uterine fibroids [Evidence Report/Technology Assessment No. 34, contract 290–97–0014 to the Duke Evidence based Practice Center]. AHRQ Publication No. 01–E052. Rockville, MD: Agency for Healthcare Research and Quality, 2001.
3. Walker WJ, Pelage JP. Uterine artery embolisation for symptomatic fibroids: clinical results in 400 women with imaging follow up. *BJOG* 2002;109:1262–72.
4. Dennerstein L, Wood C, Westmore A. *Hysterectomy: New options and advances*. 2nd edition. Oxford: Oxford University Press, 1995.
5. Johnstone K, Beaumont M, editors. *Hysterectomy: Not clear cut!* Proceedings

- of Women's Health Victoria's Forum, 2 July 2001. Available at www.whv.org.au/Articles/Hysterectomy_forum.pdf [Accessed January 2006].
6. Pinto E. Artery embolisation versus abdominal hysterectomy for treatment: a prospective, randomised, and controlled clinical trial. *Radiology* 2003;226:425–31.
 7. Smith SJ. Uterine fibroid embolisation. *Am Fam Physician* 2000;61:3601–7, 3611–2.
 8. A Scottish audit of hysteroscopic surgery for menorrhagia: complications and follow up. Scottish Hysteroscopy Audit Group. *Br J Obstet Gynaecol* 1995;102:249–54.
 9. Hallez JP. Myomectomies by endo-uterine resection. *Curr Opin Obstet Gynecol* 1996;8:250–6.
 10. Kitamura Y, Ascher SM, Cooper C, et al. Imaging manifestations of complications associated with uterine artery embolisation. *Radiographic* 2005;25:S119–32.
 11. Mc Lucas B, Goodwin S, Adler L, Rappaport L, Reed R, Perrella R. Pregnancy following uterine artery embolisation. *Int J Gynecol Obstet* 2001;74:1–7.
 12. Gupta J, Sinha A, Lumsden M, Hickey M. Uterine artery embolisation for symptomatic uterine fibroids. *Cochrane Database Syst Review* 2006 Jan 25;(1):CD005073.
 13. Worthington-Kirsch R, Spies JB, Myers ER, et al. The Fibroid Registry for Outcomes Data (FIBROID) for uterine embolisation, short term outcomes. *Obstet Gynecol* 2005;106:52–9.
 14. Razavi MK, Hwang G, Jahed A, Modanloo S, Chen B. Abdominal myomectomy versus uterine fibroid embolisation in the treatment of symptomatic uterine leiomyomas. *AJR Am J Roentgenol* 2003;180:1571–5.
 15. Razavi MK, Hwang G, Jahed A, Modanloo S, Chen B. Abdominal myomectomy versus uterine fibroid embolisation in the treatment of symptomatic uterine leiomyomas. *AJR Am J Roentgenol* 2003;180:1571–5.
 16. Pinto I, Chimeno P, Romo A, et al. Uterine fibroids: uterine artery embolisation versus abdominal hysterectomy for treatment: a prospective, randomised, and controlled clinical trial. *Radiology* 2003;226:425–31.
 17. Spies JB, Cooper JM, Worthington-Kirsch R, Lipman JC, Mills BB, Benenati JF. Outcomes of uterine embolisation and hysterectomy for leiomyomas: results of a multicentre study. *Am J Obstet Gynecol* 2004;191:22–31.
 18. McLucas B, Adler L. Uterine fibroid embolisation compared with myomectomy. *Int J Gynecol Obstet* 2001;74:297–9.
 19. Hovesejian DM, Siskin GP, Bonn J, et al. Quality improvement guidelines for uterine artery embolisation for symptomatic leiomyomata. *Cardiovasc Intervent Radiol* 2004;27:307–13.
 20. Spies JB, Spector A, Roth AR, Baker CM, Mauro L, Murphy-Skrynarz K. Complications after uterine artery embolisation for leiomyomas. *Obstet Gynecol* 2002;100:873–80.
 21. Garry R, Fountain J, Mason S, et al. The eVALuate study: two parallel randomised trials, one comparing laparoscopic with abdominal hysterectomy, the other comparing laparoscopic with vaginal hysterectomy. *BMJ* 2004;328:129.