




# Dry eyes, menopause and hormone therapy

## Eye series - 21

**Chris Hodge**, BAppSc (Orth), is Research Director, The Eye Institute, Chatswood New South Wales.

**David Ng**, MBBS (Syd), FRANZCO, MPH, is an Ophthalmic Surgeon, The Eye Institute, Chatswood, New South Wales.



### Case history

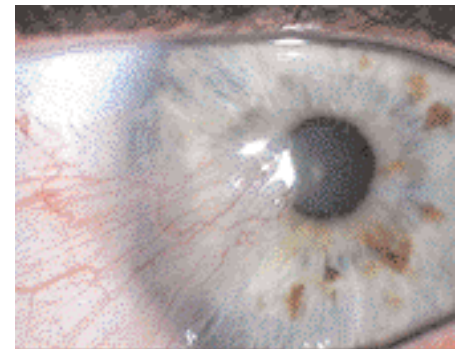
A woman, 49 years of age, returns for a regular check up to monitor menopausal changes and to decide whether medication for her menopause symptoms is necessary. As an accountant who works long hours in front of a computer, she has noticed her eyes have felt increasingly dry and irritable. She also describes a burning sensation in her eyes. Lubricant drops work only temporarily to reduce symptoms.

### FEEDBACK

#### Answer 1

It is often difficult to diagnose dry eye syndrome because of the inconsistency in the correlation between symptoms and clinical signs. However, a detailed patient history can often provide important clues to the diagnosis and an ordered examination can help to refine the likely cause and lead to effective treatment.

A patient that complains of irritable, burning eyes is more likely to have a decrease in the quality of the tear film due to inflammation. Artificial tears will serve to wash the eye removing possible inflammatory agents, but they tend to provide only temporary relief as they do not treat the causative factors. Conditions that cause a decrease in the production of tear film (eg. hyposecretion of the lacrimal gland due to oral medication) are more likely to lead to a simple dry feeling. Lubricating drops will provide more adequate and long lasting relief in these cases. Gross changes such as severe lid defects (ectropion or entropion), pterygium or pingueculae can be seen without the need for specialist equipment. These changes will disrupt the tear film surface leading to symptoms (*Figure 1*). Symptoms will vary depending on the extent of the conditions. In the absence of a slit lamp microscope, an ophthalmoscope on a high plus setting can be used as a simple magnifier to locate more subtle changes to the ocular surface and lid margins. Meibomian gland dysfunction and chronic lid inflammation may cause



**Figure 1.** Pterygium left eye that can disrupt the tear film

lash damage and scarring to the lid margins which will further disrupt the corneal tear film and lead to symptoms. Corneal staining with fluorescein or rose bengal can be useful to determine the quality of the tear film. The use of Schirmer's tear film test provides an approximate but useful guide to the amount of tears produced. This may help to further differentiate the origin of the condition.

#### Answer 2

The relationship between menopause (and HT) and dry eye syndrome is not well understood, but oestrogen is known to affect the sebaceous glands in the body. The meibomian glands are modified sebaceous glands found in the eyelids and are responsible for the production of the outer lipid layer of the tear film. The role of the lipid layer is to reduce the evaporation of the aqueous layer and increase the stability of the tear film. Reduced production may lead to an increased tear film break up resulting in local irritation. Furthermore, a significant reduction (or fluctuation) in meibomian gland function

### Question 1

Which tests will help determine the cause of these symptoms?

### Question 2

How does menopause contribute to 'dry eye'?

### Question 3

Will hormone therapy (HT) lead to an improvement or deterioration of these symptoms?

### Question 4

Describe the treatment of 'dry eye'.

### Question 5

What other ocular side effects have been attributed to HT?

may lead to increased inflammation at the lid margins. This may produce clinical changes that lead to dry and irritable conditions.

### Answer 3

The complexity of dry eye syndrome and the lack of clinical understanding of the condition have led to contrasting results in the literature, in particular whether HT may serve to relieve or exacerbate dry, irritable eyes attributed to menopause. Schaumberg et al<sup>1</sup> questioned over 25 000 postmenopausal women as part of a larger women's health study and concluded that those who had taken HT had up to a 69% greater chance of developing dry eye. Furthermore, for every 3 years of HT use there was a 15% increased risk of having dry eyes. In contrast, Petit et al<sup>2</sup> found that the intervention of HT can improve tear film results and relieve symptoms. Many variables exist and further study is required before a definitive answer can be provided.

### Answer 4

Effective treatment begins, if possible, with treatment of the underlying cause. Meibomian gland dysfunction should be treated with a combination of warm lid compresses and nonirritating cleaning solutions or lid scrubs which remove excess oils or irritation. Antibiotic or steroid drops may be necessary to help break the inflammation cycle in severe cases. Misdirected lashes that have occurred as a result of long term inflammation may require epilation. This often provides only temporary relief as the lashes generally grow back within 6–8 weeks. Laser therapy applied to the base of the lash or electrolysis may help to create a permanent effect.

Artificial tears also help to provide relief by washing away possible inflammatory agents and by providing a smooth ocular surface. The severity of symptoms governs the requirement for drops. Commonly artificial tears are used regularly, either three or four times per day. Environmental factors such as dry, humid conditions or heavily air conditioned offices may increase the need for

usage. If drops are required more than six times per day then nonpreserved preparations are recommended. The preservatives can further irritate eyes. If a patient does not find relief from drops then more viscous gels can be tried. If these are not satisfactory then the insertion of temporary plugs into the lacrimal puncta of the eyelids will stop the tears from draining and create a reservoir to provide coverage for the dry eye. Permanent punctal cautery is useful in extreme cases.

### Answer 5

Hormone therapy has been reported to have both positive and negative effects on the ocular system. Positively, large studies have shown a correlation between HT and a lower prevalence of cataract formation.<sup>3,4</sup> A recent study<sup>5</sup> has also attributed a reduction in the progression to severe age related macular degeneration to oestrogen HT, although variation in results across studies exist. Hormone therapy has also been found to slightly reduce intraocular pressure in menopausal women.<sup>6</sup> Results again differ between studies as to the relevance of the data due to the number of variables that can lead to intraocular pressure and thereby glaucoma.

Negative ocular side effects of HT have also been reported. An increased risk of retinal vein thrombosis has been recognised in the regular use of treatment.<sup>7</sup>

The Therapeutic Goods Administration's Adverse Drug Reactions Advisory Committee has also reported ocular adverse events associated with the use of bisphosphonates. These include various reports of inflammation such as scleritis, episcleritis and conjunctivitis, haemorrhage, optic neuritis and visual field defects.<sup>8</sup>

Conflict of interest: none declared.

### References

1. Schaumberg DB, Buring JE, Sullivan DA, Dana MR. Hormone replacement therapy and dry eye syndrome. *JAMA* 2001;286:2114–2119.
2. Pelit A, Bagis T, Kayaselcuk F, et al. Tear function tests and conjunctival impression cytology

before and after hormone replacement therapy in postmenopausal women. *Eur J Ophthalmol* 2003;13:337–342.

3. Freeman EE, Munoz B, Schein OD, West SK. Hormone replacement therapy and lens opacities: the Salisbury Eye Evaluation project. *Arch Ophthalmol* 2001;119(11):1687–1692.
4. Younan C, Mitchell P, Cumming RG, Panchapakesan J, Rochtchina E, Hales AM. Hormone replacement therapy, reproductive factors, and the incidence of cataract and cataract surgery: the Blue Mountains Eye Study. *Am J Epidemiol* 2002;155:997–1006.
5. Snow KK, Cote J, Yang W, Davis NJ, Seddon JM. Association between reproductive and hormonal factors and age related maculopathy in postmenopausal women. *Am J Ophthalmol* 2002;134:842–848.
6. Affinito P, Di Spiezo Sardo A, Di Carlo C, et al. Effects of hormone replacement therapy on ocular function in postmenopause. *Menopause* 2003;10:482–487.
7. Kirwan JF, Tsatoumas MD, Vinall H et al. Sex hormone preparations and retinal vein occlusion. *Eye* 1997;11:53–56.
8. Australian Drug Evaluation Committee. Bisphosphonates and ocular inflammation. *Australian Adverse Drug Reactions Bulletin*. Vol 23, 2004. Available at: [www.tga.gov.au/adr/aadrb/aadr0404.htm#3](http://www.tga.gov.au/adr/aadrb/aadr0404.htm#3).

AFP

### Correspondence

Email: [chodge@theeyeinstitute.com.au](mailto:chodge@theeyeinstitute.com.au)