



# Itchy eyes case study

## Eye series - 17



**Chris Hodge**, BAppSc, DOBA, is Research Director, The Eye Institute, Chatswood, New South Wales.

**David Ng**, MBBS, FRANZCO, MPH, is an ophthalmic surgeon, The Eye Institute, Chatswood, New South Wales.

### Case history

A 45 year old woman presents with itchy, irritable eyes. She finds it is generally worse in the morning. Although there is no obvious discharge she occasionally finds herself cleaning dandruff-like particles from her lashes. The condition is intermittent in nature. In the past she has used over-the-counter ocular lubricants that provide temporarily relief, but symptoms usually recur. She is otherwise healthy with no associated health problems.

### Question 1

Describe the differential diagnoses.

### Question 2

Differentiate the common types of blepharitis. What ocular signs – seen upon close examination – will help determine the correct diagnosis?

### Question 3

Is it possible for this patient to go blind?

### Question 4

Describe the treatment options.

### Question 5

What are the possible side effects of these treatments?

## FEEDBACK

### Answer 1

Itchy, irritable eyes may represent the presence of a number of ocular conditions:

**Allergic conjunctivitis** may cause such symptoms but there would more commonly be excessive discharge and redness as well. In severe cases the lids will also become inflamed and swollen. Attacks will generally occur around the hayfever season unless a chronic situation is present. Patients may also have an allergic type history, ie. asthma, hayfever, eczema.

**Ocular surface disease** such as superficial keratitis will produce symptoms of local irritation and subsequent tear film disruption. Patients will complain of a foreign body sensation and often note constant tearing. Vision may or may not be affected depending on the origin and severity of the particular condition.

**Inflammatory diseases** of the lids or lid margins will also disrupt the tear film surface and lead to the patient complaining of burning, irritable eyes. Localised swelling of the lids, with or without associated crusting or discharge will be noticeable on close examination. As the production of tear film is significantly reduced during sleeping hours, disorders that affect the stability of the tear film will generally be exacerbated upon waking. Infections may include conditions such as chalazions, styes or blepharitis, or unusual presentations such as molluscum contagiosum, an infection due to the pox class of viruses (*Figure 1*).

**Mechanical lid anomalies** such as entropion or ectropion (inward or outward turning of the

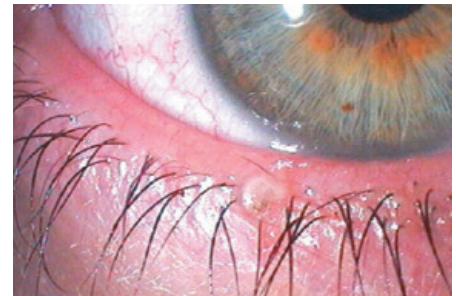

Figure 1. Molluscum contagiosum

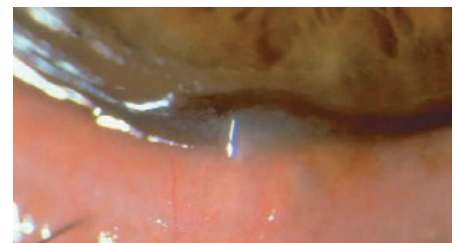


Figure 2. Meibomianitis

lids) may lead to irritation and tearing. The symptoms are usually constant and aggravated further by external factors such as dry or windy conditions. Patients may gain temporary relief from symptoms by excessive eye rubbing. This will often leave the eye red and inflamed and cause the condition to further deteriorate.

### Answer 2

Blepharitis is a relatively common inflammatory condition of the lid margins. The condition may be classified into two main types, anterior and posterior blepharitis. Symptoms of both types will be similar, however, subtle differences will allow proper diagnosis and lead to more effective treatment. Anterior blepharitis may be classified further due to the existing cause:

- Staphylococcal anterior blepharitis is

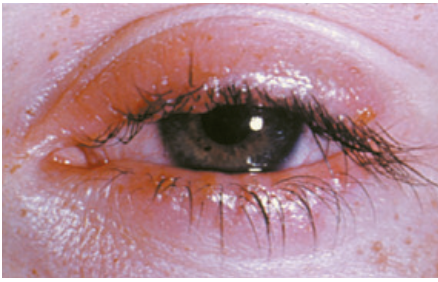


Figure 3. Blepharitis

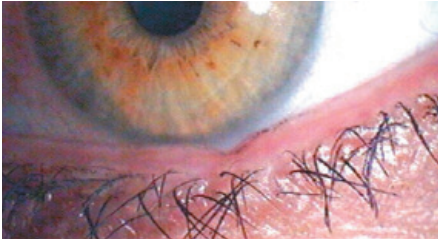

Figure 4. Lower lid notching

caused by chronic infection at the base of the lashes. Without adequate treatment this may lead to ulceration of the lid surface and tissue destruction. Long term complications may include misdirection (trichiasis) or loss of lashes and scarring of the lid margin. Further spread of the infection may lead to chronic styne formation. On observation the lid margin will appear inflamed with small, hard scales surrounding the base of the lashes (collarettes). When removed they may lead to small, bleeding ulcers. Telangiectasia may be seen on close examination

- Seborrhoeic anterior blepharitis will generally leave the lashes with a waxy appearance with the lashes often sticking together. A dandruff-like scale is present. Unlike the staphylococcal type, the scales are soft and do not bleed on removal. Associated skin changes due to the dermatitis may manifest itself in itchy symptoms across other parts of the body
- Posterior blepharitis is generally caused by a dysfunction of the meibomian glands. This condition may occur isolated or in combination with the various anterior types of blepharitis or secondary to acne rosacea or dermatitis. Posterior blepharitis may lead to an excess of oily, waxy secretions from the glands (meibomian

seborrhoea) (Figure 2) or alternately the inflammation may cause the glands to become blocked (posterior meibomianitis) (Figure 3). Firm massaging of the lid margin may show thick, inspissated secretions. Chronic cases may cause permanent lid thickening or scarring leading to corneal and tear film changes and exacerbation of symptoms. Systemic antibiotics may be required to assist the treatment of these cases.

### Answer 3

The condition blepharitis is unlikely to lead directly to blindness. However, lid changes such as notching, trichiasis, entropion and ectropion may occur (Figure 4). These further changes may result in corneal and conjunctival inflammation and or scarring, leading ultimately to loss of vision.

### Answer 4

Because of the chronic, intermittent nature of the condition, treatment is aimed at controlling symptoms and breaking the cycle of inflammation. The following simple steps will provide effective treatment:

- regular artificial tears help to temporarily alleviate the itchy feeling, and will also serve to wash the eye removing possible inflammatory agents
- lid scrubs
  - warm compresses serve to liquefy the meibomian secretions helping to facilitate the expression of the clogging debris
  - firm stroking (massage) on the eyelids toward the eyelashes will bring the remaining debris to the surface for removal
  - cleansing lid margins using 5 drops of baby shampoo into half a cup of cool, boiled water (dip a cottonbud into the solution and scrub horizontally at eyelid margin)
  - rinsing well with water will remove any excess solution and debris.

This process should be performed twice per day for 1 month then daily for a further month. Chloramphenicol ointment may be applied to the lid margins for the first week

for severe staphylococcal anterior blepharitis. If the lid margin is very inflamed, hydrocortisone ointment may also be applied throughout the first week.

In more severe cases oral tetracyclines can help resolve symptoms. Due to the nature of the condition, doses may need to be used chronically, tapered or discontinued and restarted when symptoms arise again. Topical steroids may prove useful in some cases, however, usage should be minimised to prevent potentially damaging side effects. The patient should be counselled to follow the course of treatment fully (even though symptoms may resolve soon after treatment commences) as the base infection may still be present.

### Answer 5

Patients using topical steroids and tetracycline class drugs should be monitored for the possibility of side effects. Chronic topical steroid use may lead to the formation of cataracts, increase the possible risk of infection and cause a possible increase in the patient's intraocular pressure that may lead to glaucomatous changes and peripheral vision loss. Patients treated with tetracyclines may complain of gastrointestinal symptoms such as nausea and diarrhoea. Tetracyclines have also been associated with the development of increased sensitivity to light and the patient should be counselled to avoid moderate to harsh sunlight and use adequate protection. Sensitivity may continue for several weeks or months after the treatment course has continued. Furthermore these drugs may interfere with the effectiveness of the oral contraceptive pill. Treatment with tetracyclines is a contraindication during pregnancy. Although blepharitis is uncommon in small children, use of tetracyclines within this age group may lead to limited bone growth and teeth discolouration and should not be used.

Conflict of interest: none declared.

AFP

### Correspondence

Email: chodge@theeyeinstitute.com.au