



RACGP

*Clinical guidance  
for MRI referral*



## **Clinical guidance for MRI referral**

### **Disclaimer**

The information set out in this publication is current at the date of first publication and is intended for use as a guide of a general nature only and may or may not be relevant to particular patients or circumstances. Nor is this publication exhaustive of the subject matter. Persons implementing any recommendations contained in this publication must exercise their own independent skill or judgement or seek appropriate professional advice relevant to their own particular circumstances when so doing. Compliance with any recommendations cannot of itself guarantee discharge of the duty of care owed to patients and others coming into contact with the health professional and the premises from which the health professional operates.

Whilst the text is directed to health professionals possessing appropriate qualifications and skills in ascertaining and discharging their professional (including legal) duties, it is not to be regarded as clinical advice and, in particular, is no substitute for a full examination and consideration of medical history in reaching a diagnosis and treatment based on accepted clinical practices.

Accordingly The Royal Australian College of General Practitioners and its employees and agents shall have no liability (including without limitation liability by reason of negligence) to any users of the information contained in this publication for any loss or damage (consequential or otherwise), cost or expense incurred or arising by reason of any person using or relying on the information contained in this publication and whether caused by reason of any error, negligent act, omission or misrepresentation in the information.

### **Recommended citation**

Clinical guidance for MRI referral. East Melbourne:  
Royal Australian College of General Practitioners, 2013.

### **Published by**

The Royal Australian College of General Practitioners  
100 Wellington Parade  
East Melbourne Victoria 3002 Australia

T 1800 626 901  
F 03 9696 7511  
[www.racgp.org.au](http://www.racgp.org.au)

ISBN 978-0-86906-369-9 (web)  
ISBN 978-0-86906-372-9 (print)  
Published October 2013

The development of this guidance has been funded by the  
Australian Government Department of Health and Ageing.

© Australian Government Department of Health and Ageing.  
The Royal Australian College of General Practitioners holds the  
exclusive licence to reproduce.



RACGP

*Clinical guidance  
for MRI referral*

## *Acknowledgements*

The Royal Australian College of General Practitioners gratefully acknowledges the contributions of the members of the Advisory Group as well as the various stakeholders who provided feedback that enabled the guidance to be refined through successive drafts.

Competing interests: none declared

### **Advisory Group**

Dr Evan Ackermann, Chair

General Practitioner; Chair, National Standing Committee for Quality Care, RACGP

Professor Jenny Doust

General Practitioner; GP Clinical Epidemiologist, Bond University; Member, NPS Diagnostic Expert Advisory Panel

Dr Dan Ewald

General Practitioner; Adjunct Associate Professor, University Centre for Rural Health, University of Sydney; Clinical Advisor, North Coast NSW Medicare Local

Dr Rakesh Padarath

General Practitioner; former Chair, Education Committee, Queensland Faculty RACGP

Professor Tim Usherwood

General Practitioner; Professor of General Practice, University of Sydney

Associate Professor Michael Yelland

General and Musculoskeletal Medicine Practitioner; Associate Professor, Primary Health Care, Griffith University



# Contents

<b>Preamble</b>	<b>iv</b>
<b>Information about MRI referrals and reports</b>	<b>1</b>
MRI referrals	1
MRI reports	1
<b>Use of MRI</b>	<b>2</b>
Effective uses of MRI	2
Benefits and risks of MRI	2
Contraindications and safety	3
<b>GP resources</b>	<b>5</b>
<b>Patient information</b>	<b>6</b>
What patients may ask about MRI referrals	6
Patient resources	6
<b>Summary of MBS item descriptions</b>	<b>7</b>
<b>MRI of the head</b>	<b>8</b>
Unexplained seizure(s)	8
Background	9
Imaging choice	9
Imaging issues, benefits and risks	10
Unexplained chronic headache	11
Background	12
Imaging choice	13
Imaging issues, benefits and risks	13
<b>MRI of the cervical spine</b>	<b>14</b>
Cervical radiculopathy	14
Background	15
Imaging choice	16
Imaging issues, benefits and risks	16
Cervical spine trauma	17
Background	18
Imaging choice	18
Imaging issues, benefits and risks	19
<b>MRI of the knee</b>	<b>20</b>
Background	21
Imaging choice	22
Imaging issues, benefits and risks	22
<b>Appendix 1: Recommendation tables including explanation of grades</b>	<b>24</b>
<b>Appendix 2: Internal document hyperlink repository</b>	<b>29</b>
Bookmarks for seizures	29
Bookmarks for headaches	31
Bookmarks for cervical radiculopathy	33
Bookmarks for cervical trauma	35
Bookmarks for the knee	35
<b>References</b>	<b>36</b>



## Preamble

### Background

The Department of Health and Ageing (DoHA) is phasing in new Medicare Benefits Schedule (MBS)–supported referrals for magnetic resonance imaging (MRI) requested by general practitioners (GPs).

From November 2013, GPs will be able to request MRI studies of three anatomical regions with six clinical indications for patients aged 16 years and over. The regions and indications are:

- head – unexplained seizure(s) and chronic headache with suspected intracranial pathology
- cervical spine – cervical radiculopathy and cervical spine trauma
- knee – acute anterior cruciate ligament and acute meniscal tear.

To aid decision making for MRI, The Royal Australian College of General Practitioners (RACGP) has been tasked with producing clinical guidance material for the specific Medicare indications. This guidance has been developed by GPs for GPs, in consultation with radiologists and other specialists as appropriate. The guidance aims to support evidence-based decision making, reduce inappropriate referral and improve patient outcomes.

These new MBS items supplement existing Medicare-eligible requests by GPs for MRI scans for patients under the age of 16, released November 2012 (see [www.health.gov.au/internet/main/publishing.nsf/Content/di-factsheet-mri](http://www.health.gov.au/internet/main/publishing.nsf/Content/di-factsheet-mri)).

### Aim of guidance

The majority of evidence for medical imaging focuses on lesion detection or diagnostic accuracy. There is sparse evidence regarding the impact of diagnostic imaging on health outcomes. Furthermore, there is emerging evidence of preventable harms and unnecessary interventions.<sup>1,2</sup>

GPs should be cautious in the decision to use MRI. Clinical history and physical examination are keys to advising patients about appropriate imaging. This guidance focuses on MRI as adjunct to patient management, not as a first-line diagnostic tool.

This guidance is designed to:

- inform GPs of the indications for MRI referral under new Medicare arrangements
- guide the appropriate use of MRI in the management process
- provide key information for decision making at the point of care
- help determine appropriate and evidence-based use of MRI in general practice
- inform GPs of the benefits and limitations of MRI in the clinical context
- educate on the contraindications and safety issues with MRI scanning
- support GPs to inform patients of the potential negative health impacts.



## Development process

DoHA commissioned the RACGP in July 2013 to produce this guidance in time for the introduction of the new MBS-supported MRI referral items in November 2013. Given the limited timeframe, the RACGP took a pragmatic approach to the development of this guidance, but one which is in line with guideline development best practice.

The RACGP convened a GP-led Advisory Group, drawing on GP members with expertise and experience in guideline development and in general and musculoskeletal medicine. A literature search was conducted and key resources were identified. We searched international guidelines and high-grade, evidence-based statements on the specific indications to determine the role and overall benefit of imaging. We documented evidence-based statements, significant issues regarding imaging choice, and any evidence of potential harms.

This guidance provides recommendations based on current, evidence-based guidelines such as those from the Scottish Intercollegiate Guidelines Network (SIGN), the National Institute for Health and Care Excellence (NICE) and the National Health and Medical Research Council (NHMRC). In cases where recommendations specific to the indication were not available, other sources, such as systematic reviews, have been used to inform recommendations.

The guidance was progressively developed under the direction of the Advisory Group. The process was informed by feedback and information received from clinical experts and stakeholders. These include:

- Arthritis Victoria
- Australian and New Zealand Association of Neurologists
- Neurosurgical Society of Australasia
- Dr Andrew Boyden, Clinical Advisor at National Prescribing Service (NPS) Medicine Wise
- Mr Tony McBride, Health and Community Consultant
- Dr Scott Masters, RACGP National Faculty of Specific Interests – Musculoskeletal Network
- Professor Michele Sterling, Associate Director, Centre of National Research on Disability and Rehabilitation Medicine, University of Queensland.

The RACGP is grateful for information provided by the Royal Australian and New Zealand College of Radiologists (RANZCR) in its *Guidance for GP referrals for MRI studies*, which is referenced in this guidance.

## Evidence for recommendations

Due to the time constraints in the development of this guidance, we have mostly taken recommendations from existing evidence-based guidelines. The Advisory Group did not attempt to re-evaluate the evidence behind these recommendations or convert the recommendation grades to the Australian NHMRC grading levels. Therefore, the recommendations tables include the reference and sources of recommendations, the recommendation grade, and links to further information on the evidence grade where available (refer to [Appendix 1](#)). For some recommendations, an evidence grade was not available; therefore, these recommendations should be treated as expert opinion.

As the recommendations have been taken from a number of sources, there is some overlap in their scope that would not normally occur.



## Format

The guidance is divided into the three anatomical regions of the MBS item descriptions – head, cervical spine and knee.

For MRI of the head and cervical spine, we have further divided the guidance into the specific indications. For MRI of the knee, both indications have been considered together.

Each section provides key information, evidence-based recommendations, background, imaging choice, imaging issues, benefits and risks as well as optional additional background information.

## Scope

This guidance is intended for GPs who are considering referring patients aged 16 years and over with any of the specific Medicare-funded indications for MRI.

The guidance does not cover patients younger than 16 years of age.

The guidance does not give advice on interpreting MRI.





# Information about MRI referrals and reports

## MRI referrals

GPs can expect more clinically relevant reports when they ask specific clinical questions and provide a diagnosis or differential diagnoses based on clinical findings in the referral requests. For example, when requesting a neck MRI, where incidental degenerative lesions are common, providing information that the patient has neck pain with progressive left-sided C7 radiculopathy and suspected disc herniation is likely to assist the radiologist in preparing a more specific and helpful report.

Talking to a radiologist about a patient prior to referral may help to determine the most appropriate imaging. This includes the use of contrast. Note that while contrast may be requested by the referring clinician, contrast studies may not always be done if the radiologist determines plain imaging to be more appropriate.

Equally important to consider and address are the imaging expectations of patients prior to referral. Patients need to be educated that structural changes do not necessarily correlate well with symptoms.

## MRI reports

Understanding how radiologists are advised to write reports may help GPs to get the most from imaging reports. According to the RANZCR *Radiology written report guideline*,<sup>3</sup> each imaging report should:

- address the clinical question or clearly state why this is not possible
- provide a diagnosis or differential diagnosis and, where a number of possibilities exist, state them and describe their relative likelihood
- provide a concise, clinically contextualised interpretation of the previously described imaging observations. If findings are normal or non-significant, this should be stated explicitly
- recommend further imaging, investigations, referral or treatment, where indicated. The report should describe:
  - how it is expected that this will contribute to the diagnosis and/or management of the patient's current medical problem
  - the exact nature of the further investigation/referral/treatment that is recommended
  - the suggested timing of this further investigation/referral/treatment if relevant, especially if this is urgent.



## Use of MRI

### Effective uses of MRI

MRI is only effective when it supplements history and physical examination and when it is likely to improve the health outcome for the patient.

Although able to offer detailed images, MRI scanning is not always the most appropriate imaging.<sup>4</sup> In many cases, a physical examination by an experienced practitioner is able to provide an equal or better diagnosis than an MRI scan and at a substantially lower cost.

MRI is often the first imaging choice for many brain and spinal cord conditions, due to its superior detail. However, in emergency situations or when looking for bony abnormalities (e.g. occult spine fractures), computed tomography (CT) is usually recommended due its speed and superior imaging of bone.

### Benefits and risks of MRI

MRI does not use ionising radiation. In situations where it will provide better or similar information to CT or X-ray, MRI may be a safer choice. This is particularly relevant for children and young adults, who are at a greater risk from ionising radiation than older adults.

To obtain a quality MRI scan, a patient must remain immobile for the duration of the scan and MRI scanning times are typically much longer than other modalities. This may mean that some patients will require sedation or anaesthesia for MRI. The risks of sedation or anaesthesia need to be balanced with the potential for a better health outcome with information obtained by MRI.

MRI is able to produce detailed (two- and three-dimensional) images of soft tissue, including of the brain, nerves, organs, cartilage, tendons, muscles and ligaments. This makes it a superior modality for imaging in some clinical situations.

However, the ability to see the components of the body in high detail does not necessarily mean improved outcomes for patients. GPs need to keep in mind whether any diagnostic imaging will alter treatment and the potential for revealing incidental findings.

The more sensitive the imaging modality, the more likely a finding of an 'abnormality'. Many abnormalities are not clinically relevant and will not progress. Only a very small number of people will benefit from early detection of an 'incidentaloma', while others will suffer anxiety and the effects of investigations and treatment for something that would never have caused harm.<sup>5</sup>



## Contraindications and safety

The following information has been adapted from the RANZCR Guidance for *GP referrals for MRI studies*.<sup>6</sup>

### Contraindications include:

- prostheses and implants (e.g. pacemakers, internal hearing devices, neurostimulators, orthopaedic and dental implants, programmable shunts, vascular clips)
  - newer implants and prostheses, such as titanium, many types of steel and almost all joint prostheses, are usually MRI compatible
  - electrically activated devices, such as pacemakers, may be damaged or disrupted by MRI. Some pacemakers can be safely scanned with cardiological supervision – note that not all MRI sites can provide this service
  - implanted infusion pumps can often be put in ‘safe’ mode for scanning
  - note that if imaging near an implant or prosthesis, there may be a reduction in image quality
- metallic foreign bodies (e.g. small metal fragments in the eye)
  - X-rays (or CT) may be required to confirm or exclude the presence of a foreign body
- conductors (e.g. wires, metallic surgical staples, some dermal medication patches and some tattoos)
  - MRI can induce electric currents in these conductors and generate heat. Serious burns have been recorded. If the conductor cannot be removed, external cooling can be used.

### Safety considerations include:

- hearing loss
  - the loud mechanical vibrations in the scanner can aggravate pre-existing hearing loss and tinnitus. This is usually temporary. While hearing protection is routinely offered to patients, it does not always prevent symptoms
- claustrophobia
  - between 2% and 5% of patients cannot tolerate the enclosed space of an MRI scanner. Most MRI sites can provide sedation (usually intravenous) to patients, where it is medically appropriate
- pregnancy
  - there are no known adverse effects of MRI in pregnancy. It is considered reasonable to perform MRI during pregnancy if the result is required for management during pregnancy and is not available from other tests. Otherwise, it is prudent to defer the MRI scan until after pregnancy (or at least after the first trimester)
  - MRI contrast agents are relatively contraindicated in pregnancy
- lactation
  - breastfeeding is not a contraindication to MRI or MRI contrast agents
  - it is not necessary for women to stop breastfeeding before or after an MRI, nor does breast milk need to be manually expressed and discarded after MRI.



### Contrast

Intravenous contrast is not routinely required for MR imaging. It is usually confined to looking for tumours or inflammatory lesions.

Contrast agents used for MRI are different to those used for CT and X-ray contrast studies. MRI contrast agents have lower rates of anaphylactoid reaction and are given at much lower doses than those used for CT. There is minimal risk of causing or aggravating renal impairment. However, patients with severe renal disease are at risk of nephrogenic systemic sclerosis if given MRI contrast agents (i.e. gadolinium). This is a rare but serious condition and deaths have occurred.

Prior to referral, GPs need to inform the MRI site if the patient has known significant renal impairment (i.e.  $\text{eGFR} < 30 \text{ mL/min/1.73m}^2$ ). If risk factors for potential renal impairment are present, an eGFR result (taken up to 3 months before intended MRI) will be required before administration of contrast for MRI.

For patients with significant medical illness in the 3 months preceding MRI, and for hospital inpatients, a more recent eGFR (timing will be related to the nature, severity and timing of the illness) is a wise precaution.

### Safety check

- Does the patient have any metallic implants? Surgical? Traumatic?
- Are there any implanted devices? Pacemakers? Infusion pumps?
- Have any wires been left in the patient? Pacing leads? Wire markers in catheters?
- Does the patient have significantly impaired renal function or risk factors for this (if MRI contrast agents need to be given)?
- Is the patient claustrophobic?

### Follow-up

- Identify the implant if possible (the patient may have received an information brochure about the implant at the time of surgery or you may need to obtain operative records from the surgeon or hospital where the device was implanted).
- Consult with the MRI service if you have questions about the safety of a device in the MRI environment.
- Establish safety requirements for the implant and patient.
- Consider the feasibility and risk vs. potential benefit from the proposed scan.
- Warn the MRI service if renal impairment or risk factors are present and MRI contrast agent use is likely or possible; send a recent eGFR result with request, if possible.



## GP resources

This guidance is accompanied by a series of [downloadable summary sheets](#):

- MRI of the head for unexplained seizure
- MRI of the head for chronic headache with suspected intracranial pathology
- MRI of the spine for cervical radiculopathy
- MRI of the spine for cervical trauma
- MRI of the knee for acute anterior cruciate ligament and meniscal tears.

GPs will also be able to earn CPD points with the accompanying online interactive learning module.



## Patient information

### What patients may ask about MRI referrals

NPS Medicine Wise ([www.npsmedicinewise.org.au](http://www.npsmedicinewise.org.au)) recommends that patients ask their health professional the following questions about imaging:

- How will the imaging help my condition or injury?
- What does the imaging procedure involve?
- Are there any risks associated with the imaging?
- Are there any other options?
- How much will the imaging cost?

Other questions patients may ask include:

- How much do the benefits outweigh the risks for someone of my age and condition?
- If you subsequently refer me to a specialist, will I have to have these MRIs repeated (and pay for them again)?
- What is the likelihood of incidental findings? How do you determine if they are clinically significant or not?

GPs will need to be prepared to answer these questions and be able to discuss limitations and expectations with patients.

### Patient resources

The RANZCR manages a consumer website called *Inside Radiology*, which answers basic questions about imaging, including MRI. This is available at [www.insideradiology.com.au](http://www.insideradiology.com.au)

NPS MedicineWise has patient-focused information about MRI, which includes an explanation of when MRI is and is not used, as well as the risks and benefits of MRI. This can be found at [www.nps.org.au/medical-tests/medical-imaging](http://www.nps.org.au/medical-tests/medical-imaging).



## Summary of MBS item descriptions

### Magnetic resonance imaging – Group 15

Item	Subgroup 34 – Magnetic resonance imaging – for specified conditions
<b>63551</b>	Referral by a medical practitioner (excluding a specialist or consultant physician) for a scan of head for a patient 16 years or older for any of the following: <ul style="list-style-type: none"> <li>– unexplained seizure(s) (R) (K)* (Contrast) (Anaes.)</li> <li>– unexplained chronic headache with suspected intracranial pathology (R) (K)* (Contrast) (Anaes.)</li> </ul> <b>Fee:</b> \$403.20 <b>Benefit:</b> 75% = \$302.40, 85% = \$342.75
<b>63552</b>	Referral by a medical practitioner (excluding a specialist or consultant physician) for a scan of head for a patient 16 years or older for any of the following: <ul style="list-style-type: none"> <li>– unexplained seizure(s) (R) (NK)* (Contrast) (Anaes.)</li> <li>– unexplained chronic headache with suspected intracranial pathology (R) (NK)* (Contrast) (Anaes.)</li> </ul> <b>Fee:</b> \$201.60 <b>Benefit:</b> 75% = \$151.20, 85% = \$171.40
<b>63554</b>	Referral by a medical practitioner (excluding a specialist or consultant physician) for a scan of spine for a patient 16 years or older for suspected: <ul style="list-style-type: none"> <li>– cervical radiculopathy (R) (K)* (Contrast) (Anaes.)</li> </ul> <b>Fee:</b> \$358.40 <b>Benefit:</b> 75% = \$268.80, 85% = \$304.65
<b>63555</b>	Referral by a medical practitioner (excluding a specialist or consultant physician) for a scan of spine for a patient 16 years or older for suspected: <ul style="list-style-type: none"> <li>– cervical radiculopathy (R) (NK)* (Contrast) (Anaes.)</li> </ul> <b>Fee:</b> \$179.20 <b>Benefit:</b> 75% = \$134.40, 85% = \$152.35
<b>63557</b>	Referral by a medical practitioner (excluding a specialist or consultant physician) for a scan of spine for a patient 16 years or older for suspected: <ul style="list-style-type: none"> <li>– cervical spine trauma (R) (K)*</li> </ul> <b>Fee:</b> \$492.80 <b>Benefit:</b> 75% = \$369.60, 85% = \$418.90
<b>63558</b>	Referral by a medical practitioner (excluding a specialist or consultant physician) for a scan of spine for a patient 16 years or older for suspected: <ul style="list-style-type: none"> <li>– cervical spine trauma (R) (NK)*</li> </ul> <b>Fee:</b> \$246.40 <b>Benefit:</b> 75% = \$184.80, 85% = \$209.45
<b>63560</b>	Referral by a medical practitioner (excluding a specialist or consultant physician) for a scan of knee following acute knee trauma for a patient 16 years or older with: <ul style="list-style-type: none"> <li>– inability to extend the knee suggesting the possibility of acute meniscal tear (R) (K)* (Contrast) (Anaes.); or</li> <li>– clinical findings suggesting acute anterior cruciate ligament tear. (R) (K)* (Contrast) (Anaes.)</li> </ul> <b>Fee:</b> \$403.20 <b>Benefit:</b> 75% = \$302.40, 85% = \$342.75
<b>63561</b>	Referral by a medical practitioner (excluding a specialist or consultant physician) for a scan of knee following acute knee trauma for a patient 16 years or older with: <ul style="list-style-type: none"> <li>– inability to extend the knee suggesting the possibility of acute meniscal tear (R) (NK)* (Contrast) (Anaes.); or</li> <li>– clinical findings suggesting acute anterior cruciate ligament tear. (R) (NK)* (Contrast) (Anaes.)</li> </ul> <b>Fee:</b> \$201.60 <b>Benefit:</b> 75% = \$151.20, 85% = \$171.40

\*For information on K and NK Items refer to [Capital Sensitivity for Diagnostic Imaging Equipment](#)



## MRI of the head

### Unexplained seizure(s)

#### MBS item description

*Referral by a medical practitioner (excluding a specialist or consultant physician) for a scan of head for a patient 16 years or older for:*

- **unexplained seizure(s) (R) (K) (Contrast) (Anaes.)**

#### Key information

- Although neuroimaging is indicated in most new onset seizures, there is a lack of evidence that imaging improves health outcomes.
- The type of seizure will influence decisions about neuroimaging.
- MRI is the imaging investigation of choice in most cases and CT can be considered where MRI is not available.
- There is potential to reveal incidental findings with brain MRI, which can result in unnecessary anxiety and intervention.

#### Recommendations

Recommendation	Reference/Source	Grade*
Brain imaging with CT or MRI should be considered as part of the routine neurodiagnostic evaluation of adults presenting with an apparent unprovoked first seizure	(7) Krumholz A, Wiebe S, Gronseth G, et al. Practice parameter: Evaluating an apparent unprovoked first seizure in adults, 2007	B
CT has a role in the urgent assessment of seizures, or when MRI is contraindicated or unavailable	(8) SIGN. Diagnosis and management of epilepsy in adults: a national clinical guideline, 2003	D
MRI is the imaging investigation of choice for most unexplained seizures	(9) NICE. The epilepsies: diagnosis and management of the epilepsies in adults in primary and secondary care, 2012	None given

\*Refer to [Appendix 1, Table 1.1](#), for an explanation of the Grade





## Background

There are two main seizure types: **generalised and focal** (or partial). The type of seizure will influence decisions regarding neuroimaging. Determining seizure type is best done by close attention to patient and eyewitness descriptions of the event and the findings on an electroencephalography (EEG) done in close proximity to the seizure.

It is important to make the distinction between idiopathic generalised epilepsies (IGEs) and focal (localisation-related) epilepsies, as this affects further investigations, treatment choices, prognosis and counselling.<sup>8</sup> An Australian study at a first seizure clinic found epileptogenic lesions in 17% of patients presenting with focal onset seizures.<sup>10</sup>

Patient history can often distinguish epileptic seizures from non-epileptic disorders by identifying the events directly preceding the seizure, associated conditions and details of the event, including possible triggers, duration and type of movements.<sup>11</sup> There can be difficulty in differentiating syncope from seizures based on patient self-reporting.

More than 50% of patients who present with a first seizure never have another. If patients do not have recurrence after 2 years, the risk falls to <10%. Patients with epileptic discharges on EEG or congenital neurological deficits have the highest recurrence rates (up to 90%).<sup>12</sup>

Additional investigations may be required after new onset seizure. EEG should be considered as part of the routine neurodiagnostic evaluation of adults presenting with an apparent unprovoked first seizure.<sup>7</sup> Other testing should be performed based on clinical judgement.

An MRI is not always required for a patient with new onset seizure. Idiopathic generalised epilepsy is not associated with an increased prevalence of brain lesions; therefore, if this is confidently diagnosed, the patient does not require imaging.<sup>8</sup> However, as neuroimaging is recommended in most situations of new onset seizure,<sup>11,13</sup> many patients who are later diagnosed with idiopathic generalised epilepsy will have neuroimaging after their first seizure.

Neuroimaging (preferably MRI) is recommended after a first unprovoked seizure for all adults with risk factors.<sup>11,14</sup>

Note that seizures are a feature of some brain tumours and may precede tumour diagnosis by years.<sup>15</sup>

## Imaging choice

### CT

CT has a major advantage because of the speed with which it can be obtained, so its value is mainly in the emergency situation. For emergency patients presenting with seizure, immediate non-contrast CT may be useful to guide appropriate acute management, especially where there is an abnormal neurological examination, predisposing history or focal seizure onset.<sup>16</sup>

CT of the head has demonstrated structural lesions in about one-third of adults who present to the emergency department with a first seizure.<sup>11</sup> Further, identification of lesions has altered the acute medical or surgical management in up to 17% of adults presenting with first seizure.<sup>11</sup>



## MRI

MRI is regarded by expert opinion as having a higher yield and is the preferred procedure in non-emergency or elective situations. It should only be ordered after obtaining a good clinical history, preferably including an eyewitness description, and where possible, after an EEG that does not show generalised epileptic discharges.

MRI is the preferred modality for high-resolution structural imaging in epilepsy<sup>17</sup> and is more sensitive than CT for detecting intrinsic brain tumours, stroke, focal cortical dysplasia, mesial temporal sclerosis, vascular malformations and cerebral dysgenesis.<sup>11</sup>

Although MRI is generally preferred to CT because of its greater sensitivity for intracranial pathology, CT should be performed if intracranial bleeding is suspected because of recent head trauma, coagulopathy or severe headache. This is because of the advantage of speed, as mentioned above.<sup>11</sup>

MRI is particularly indicated in those who develop epilepsy in adulthood and have any suggestion of a focal onset on history or examination.<sup>9</sup>

### Imaging issues, benefits and risks

Appropriate imaging and the identification of lesions have been shown to alter the acute medical or surgical management of patients presenting with seizures.<sup>17</sup> Whether the alteration of management led to better health outcomes is less clear.

Brain imaging has been shown to detect lesions in 21–37% of patients presenting with epilepsy.<sup>8</sup> Note that the prevalence of incidental findings on standard brain MRI is 2.7% (increasing to 4.3% using high-resolution MRI).<sup>18</sup>

Not all MRI abnormalities are associated with epileptic seizures. Punctate foci of T2 signal change in the white matter, many cystic lesions (arachnoid cysts, choroidal fissure cysts), lacunar strokes, ventricular asymmetry, diffuse atrophy and isolated venous anomalies (i.e. those not associated with arteriovenous malformation or cavernous angioma) are not known to be epileptogenic, and should be considered incidental to a seizure diagnosis.<sup>19</sup> The lesions detected in patients presenting with epilepsy only require treatment in a small minority of patients.<sup>8</sup>

The prevalence of **incidental findings** increases with age.<sup>18</sup>

Potential harm arising from the further treatment and investigation of incidental findings has to be balanced against the likelihood of benefit from detecting a significant abnormality.



## Unexplained chronic headache

### MBS item description

*Referral by a medical practitioner (excluding a specialist or consultant physician) for a scan of head for a patient 16 years or older for:*

- **unexplained chronic headache with suspected intracranial pathology** (R) (K)  
(Contrast) (Anaes.)

### Key information

- In most headache syndromes there is a lack of evidence to suggest imaging improves health outcomes.
- Most common headache types can be diagnosed on history and examination.
- Investigations including neuroimaging are only indicated when history or examination suggests headache is secondary to serious intracranial pathology.
- Abnormalities detected on neuroimaging may not be clinically significant but may lead to further unnecessary investigations or interventions.
- Neuroimaging for reassurance is not recommended.
- This guidance does not cover acute headache.

### Recommendations

Recommendation	Reference/Source	Grade*
Neuroimaging should be considered in patients with headache and an unexplained abnormal finding on the neurological examination	(20) SIGN. Diagnosis and management of headache in adults, 2008	B
Neuroimaging could be considered for headache worsened by Valsalva manoeuvre, headache causing awakening from sleep, new headache in an older patient, or progressively worsening headache†	(21) Frishberg BM, Rosenburg JH, Matchar DB, et al. Evidence-based guidelines in the primary care setting: neuroimaging in patients with nonacute headache, 2000	C
Neuroimaging is not indicated for people diagnosed with tension-type headache, migraine, cluster headache or medication overuse headache <b>solely for reassurance</b>	(22) NICE. Diagnosis and management of headaches in young people and adults, 2012	None given

\*Refer to [Appendix 1, Table 1.2](#), for an explanation of the Grade

†While these may indicate a higher likelihood of significant intracranial pathology, as reported in several small studies, the evidence is insufficient to make specific recommendations regarding neuroimaging in the presence or absence of neurological symptoms.<sup>21</sup>



## Background

Headache is one of the most common neurological problems presented to GPs. People with headache and their healthcare professionals can be worried about possible serious underlying disease.<sup>20,21</sup>

Headaches disorders are classified as either primary or secondary and these are further divided into specific headache type.<sup>20,22</sup>

Primary **headache disorders**, including migraine, tension-type and cluster headaches, account for the majority of headaches.<sup>23</sup> The aetiology of primary headaches is poorly understood and they are differentiated by their **clinical patterns**.<sup>22</sup>

Investigations, including neuroimaging, do not contribute to the diagnosis of migraine or tension-type headache. Some guidelines, but not all, recommend brain MRI in patients with cluster headache due to the small possibility of a serious underlying structural lesion.<sup>24</sup>

**Secondary headaches**, are attributed to underlying disorders.<sup>20</sup> The most common secondary headache is due to medication overuse, which occurs most commonly in those taking medication for a primary headache disorder.<sup>20</sup> Headache may also be referred from the muscles, joints and ligaments of the upper three cervical segments due to the convergence of nociceptive afferent nerves from these segments with those of the trigeminal nerve.<sup>25</sup>

**Serious causes of secondary headaches include tumour**, infection, bleeding and arteritis.<sup>24,26</sup> These warrant further investigation, which may include imaging. Note that MRI will not detect all serious causes of secondary headache, such as **giant cell arteritis**.<sup>6</sup>

For detailed explanations of headache classifications go to the International Headache Society Classification page (<http://ihs-classification.org/en/>).

### What findings increase the suspicion of intracranial pathology?

People with headache alone are unlikely to have serious underlying disease.<sup>22</sup> Serious intracranial pathology as the cause of headache is rare (e.g. space-occupying lesion <1%, idiopathic intracranial hypertension <1%, chronic meningitis <1% and giant cell arteritis <1%).<sup>6</sup>

The **SNOOP mnemonic** is a useful reminder of clinical features that may indicate a secondary headache with serious underlying cause.<sup>27,28</sup>

### History

Patients with increased intracranial pressure may report symptoms such as:

- a frontal headache that is worse after lying down, most notable in the morning and wakes the patient from sleep but improves during the day
- vomiting, particularly early morning and not associated with nausea
- blurred vision
- personality or behavioural changes.

In imaging studies, the following symptoms have been shown to increase the odds of finding a significant abnormality on neuroimaging: rapidly increasing headache frequency, history of dizziness or lack of coordination, history of subjective numbness or tingling, or history of headache causing awakening from sleep.<sup>21</sup>



### Physical examination

Examination of patients presenting with headache should include:<sup>20,22</sup>

- blood pressure
- examination of temporal arteries
- neck examination, including palpation for posterior cervical tenderness
- fundoscopy (where the doctor is experienced in its use)
- cranial nerve assessment, especially pupils, visual fields, eye movements, facial power and sensation, and bulbar function (soft palate, tongue movement)
- assessment of tone, power, reflexes and coordination in all four limbs
- plantar responses
- assessment of gait, including heel-toe walking.

There should be more detailed assessment if prompted by the history. The examination should be tailored to include any focal neurological symptoms.<sup>20</sup>

An abnormal neurological examination significantly increases the likelihood of finding an abnormality on neuroimaging.<sup>21</sup>

### Imaging choice

The choice between CT and MRI may depend on the situation. In emergency situations, CT is generally recommended.

SIGN suggests that MRI is the imaging modality of choice because of its greater sensitivity.<sup>20</sup>

MRI does appear to be more sensitive in finding white matter lesions and developmental venous anomalies than CT.<sup>20,21</sup> However, this greater sensitivity appears to be of little clinical importance in the evaluation of patients with chronic headache, as MRI may just be better at identifying incidental abnormalities.<sup>21</sup>

### Imaging issues, benefits and risks

The relative rarity of secondary headaches – compared with the large number of patients with primary headache – and the potential to reveal incidental abnormalities raise concerns about the balance between risk and benefits of neuroimaging studies (either CT or MRI) to exclude underlying causes of headache.<sup>21</sup>

The major benefit of neuroimaging is the detection of significant and treatable lesions that impact the quality of life.<sup>21</sup> The risk is finding incidental abnormalities that may cause anxiety and potential harm with further investigations and treatments. MRI, with its greater sensitivity, may be better at finding abnormalities – both significant and insignificant.

The ‘benefit’ of alleviating patient anxiety about having an underlying pathologic condition by obtaining a negative or normal scan does not appear to be a significant or sustained benefit.<sup>20,22</sup> A randomised controlled trial of 150 patients with chronic daily headache in a specialist clinic found that patients who received MRI had a decrease in anxiety levels at 3 months, but that the reduction in anxiety was not maintained at 1 year.<sup>20</sup>

Other risks include false reassurance from an inadequate study and the risk of over-sedation in claustrophobic patients having MRI scans.<sup>21</sup>



## MRI of the cervical spine

### Cervical radiculopathy

#### MBS item description

*Referral by a medical practitioner (excluding a specialist or consultant physician) for a scan of spine for a patient 16 years or older for suspected:*

- **cervical radiculopathy (R) (K) (Contrast) (Anaes.)**

#### Key information

- There is a lack of evidence that MRI has led to improved health outcomes for patients with cervical radiculopathy.
- GPs need to distinguish between patients with radicular signs and symptoms and those with musculoskeletal referred pain.
- Most cases of cervical radiculopathy settle over time and conservative therapies are preferred in most patients.
- Imaging studies often report findings that may have little to do with neck pain – incidental degenerative changes of the cervical spine may occur in 30–40% of asymptomatic young and middle-aged patients.
- Although MRI is regarded as the preferred modality, the reliability of MRI readings for common degenerative or other pathologic findings in the cervical spine is moderate at best and its value is highly dependent on careful interpretation of the images in the context of the patient's clinical presentation.

#### Recommendations

Recommendation	Reference/Source	Grade*
MRI is suggested for the confirmation of correlative compressive lesions <sup>†</sup> of the cervical spine in patients who have failed a course of conservative therapy and who may be candidates for interventional or surgical treatment	(29) NASS. Diagnosis and treatment of cervical radiculopathy from degenerative disorders, 2010	B
Consider MRI when cervical radiculopathy has been present for 6 weeks and is not improving	(30) NICE online: Neck pain – cervical radiculopathy, revised 2009	None given
Cervical X-rays and other imaging studies and investigations are not routinely required to diagnose or assess neck pain with radiculopathy	(30) As above	None given

\*Refer to [Appendix 1, Table 1.3](#), for an explanation of the Grade

<sup>†</sup>Disc herniation and spondylosis



## Background

Cervical radiculopathy is usually due to compression or injury to a nerve root by a herniated disc or degenerative changes. Levels C5 to T1 are the most commonly affected.<sup>30</sup> It is usually, but not always, accompanied by cervical radicular pain, a sharp and shooting pain that travels from the neck and down the upper limb and may be severe. This needs to be differentiated from pain referred from the musculoskeletal (somatic) structures in the neck, which may be aching rather than sharp, and is more severe in the neck than in the upper limb.

The **neurological signs** of cervical radiculopathy depend on the site of the lesion. The patient may have motor dysfunction, sensory deficits or alteration in tendon reflexes. While pain is a common presenting symptom, not all radiculopathies are painful (i.e. only motor deficits may be obvious).<sup>30</sup>

For most patients with cervical radiculopathy from degenerative disorders, it is likely that signs and symptoms will be self-limited and will resolve spontaneously over a variable length of time without specific treatment.<sup>29</sup> Patient education and discussion about options and expectations are important.

### What presenting symptoms suggest cervical radiculopathy?

#### History

Patients may report pain in the neck, shoulder and/or arm that is usually unilateral, but may be bilateral. The pain may be severe enough to wake the person at night.<sup>30</sup>

Neurological signs reported are altered sensation or numbness, or weakness in related muscles. Sensory symptoms are more common than motor symptoms.<sup>30</sup>

#### Physical examination

**Look for features suggestive of a serious spinal or other abnormality**, including compression of the spinal cord (myelopathy), cancer, severe trauma or skeletal injury, and vascular insufficiency. If these are present, arrange referral.

Examine for signs of cervical radiculopathy:

- Postural asymmetry: the head may be held to one side or flexed, as this decompresses the nerve root. If the asymmetry is long-standing, muscle wasting may be present.
- Neck movements: these may be restricted, or sharp pain may radiate into the arms (especially on extension or on bending or turning to the affected side).
- Dural irritation: assess with the Spurling test: the examiner extends the neck, sidebends it 30 degrees to the affected side and then applies axial compression to the head. The test is positive if this pressure causes the typical radicular arm pain.
- Neurological signs: for example, upper limb weakness, paraesthesiae, dermatomal sensory or motor deficit, or diminished tendon reflexes at the appropriate level. Nerve root symptoms should normally arise from a single nerve root: involvement of more than one nerve root suggests a more widespread neurological disorder.<sup>30</sup>

Manual provocation tests (e.g. Spurling), designed to elicit nerve root compression in the cervical spine, have high positive predictive value.<sup>31</sup>

It is suggested that the diagnosis of cervical radiculopathy be considered in patients with arm pain, neck pain, scapular or periscapular pain, and paraesthesias, numbness and sensory changes, weakness, or abnormal deep tendon reflexes in the arm.<sup>29</sup>



Cervical radiculopathy can also be considered in patients with atypical findings such as deltoid weakness, scapular winging, weakness of the intrinsic muscles of the hand, chest or deep breast pain, and headaches.<sup>29</sup>

### Imaging choice

Both CT and MRI have been used to assess cervical radiculopathy; however, neither is required for diagnosis of cervical radiculopathy and neither is indicated unless patients have failed a (6-week) course of conservative therapy.<sup>29,30</sup>

CT scanning cannot accurately demonstrate the commonest cause for cervical radiculopathy (disc herniation) without myelography, which requires hospital admission, lumbar puncture and the use of contrast.

The assessment of root compression of the cervical spine by CT scan has fair-to-moderate reliability.<sup>31</sup>

In patients with cervical radiculopathy, MRI is the imaging technique of choice for the detection of root compression by disc herniation and osteophytes.<sup>32</sup>

MRI allows the nerve roots to be directly visualised. However, imaging studies often report findings that may have little to do with neck pain and there may be a high prevalence of incidental neck abnormalities with MRI.<sup>33</sup> In one study of young, healthy volunteers, the prevalence of incidental neck abnormalities was 36.7%.<sup>34</sup> Incidental findings would be expected to increase with age.

### Imaging issues, benefits and risks

MRI allows visualisation of nerve root and the brachial plexus, which could be beneficial as brachial plexus signs mimic cervical radiculopathy. However, despite the potential advantages of MRI in detecting structural abnormalities, it does not appear to have any unique role, independent of the history and clinical examination, in detecting the cause of neck pain.<sup>31</sup>

There is no evidence that common degenerative changes on cervical MRI are strongly correlated with neck pain symptoms. Common degenerative changes are highly prevalent in asymptomatic subjects.<sup>33</sup>

In a 1990 study, approximately 30–40% of asymptomatic young and middle-aged patients had changes in the intervertebral discs, such as a protrusion or desiccation.<sup>35</sup>

Abnormal MRI findings of the cervical spine have also been found to increase with age.<sup>33</sup>

The indiscriminate use of imaging procedures for common and uncomplicated clinical presentations of the back and spine (e.g. chronic neck pain) has contributed to the perception of low value from these tests and to the high costs in managing these conditions.<sup>36</sup>

Combined with symptoms of radicular complaints and specific findings on examination, MRI may aid in determining the site and level of neurological compression. However, there is evidence that cervical MRI findings of disc or disc material extrusion through the cervical posterior longitudinal ligament do not correlate accurately with surgical findings.<sup>31</sup>





## Cervical spine trauma

### MBS item description

*Referral by a medical practitioner (excluding a specialist or consultant physician) for a scan of spine for a patient 16 years or older for suspected:*

- **cervical spine trauma (R) (K)**

### Key information

- There is a lack of evidence that MRI has led to improved health outcomes for patients with cervical trauma.
- CT is superior to MRI and X-ray at identifying cervical spine fractures – there is strong evidence to suggest fractures may be missed with cervical X-rays.
- MRI is not reliable for identifying cervical spine fracture.
- MRI is superior at identifying soft tissue injuries, such as spinal cord and ligamentous injury; however, it is unclear if all findings identified by MRI are clinically significant.
- A negative CT scan, when reviewed by an appropriate radiologist, is sufficient to cease spinal precautions.

### Recommendations

Recommendation	Reference/Source	Grade*
Cervical spine imaging is <b>not</b> indicated in awake, alert patients with trauma without neurological deficit or distracting <sup>†</sup> injury who have no neck pain or tenderness with full range of motion of the cervical spine	(37) Como JJ, Diaz JJ, Dunham CM, et al. Practice management guidelines for identification of cervical spine injuries following trauma, 2009	Level 2
If a cervical spine fracture is suspected, imaging with CT or X-ray is indicated	(38) Bussi�eres AE, Taylor JA, Peterson C, et al. Diagnostic imaging practice guidelines for musculoskeletal complaints in adults, 2008	B
MRI has a role where other imaging is contraindicated/inconclusive or where clinical or imaging findings suggest ligamentous injury, spinal cord injury and/or arterial injury	(38) As above (39) Daffner RH, Weissman BN, Angtuaco EJ, et al. ACR appropriateness criteria – suspected spine trauma, 2012	C

\*Refer to [Appendix 1, Table 1.4](#), for an explanation of the Grade

<sup>†</sup>A distracting injury is a condition that is thought to be producing pain sufficient to distract the patient from a second (cervical) injury (e.g. long bone fracture or burn)<sup>37</sup>



## Background

The major concern with cervical spine trauma is fracture. While injury to the cervical spine is common after trauma (such as motor vehicle accidents and falls), fractures of the cervical spine are uncommon. Because of the serious medical, psychological and financial consequences of missed fractures, the use of imaging of the cervical spine to exclude fracture is a routine part of the evaluation of the trauma patient.<sup>37,40</sup>

Fractures of the cervical spine may not be clinically obvious. Patients may be neurologically intact initially but, if not treated appropriately and promptly, may progress to severe neurological compromise. Delayed onset of paralysis occurs in as many as 15% of missed fractures, and death owing to unidentified cervical spine fracture is possible.<sup>37</sup>

Soft tissue injury (e.g. whiplash injury) may occur following sudden or excessive hyperextension, hyperflexion or rotation of the neck. Whiplash injury causes neck pain and other symptoms, which may be severe and persist for more than 6 months. Signs of whiplash injury include neck pain and stiffness extending to the shoulders and thoracic spine, persistent headache, dizziness, upper-limb paraesthesia and psychological and emotional symptoms.<sup>41</sup>

### Assessment of the patient with suspected cervical trauma

In the emergency room after blunt trauma to the neck, triage should be based on the [Canadian C-spine rule](#) or the [NEXUS criteria](#) to rule out the need for further imaging.<sup>31,33</sup>

In contrast, in ambulatory primary care, triage is usually based on history and physical examination alone.<sup>33</sup> In some situations, GPs may elect to use the Canadian C-spine rule and NEXUS criteria.

### Physical examination

Look for signs of muscular spasm, point tenderness and neurological problems in the upper or lower limbs.<sup>42</sup>

It is also safe to assess for range of neck movements if the person:

- does not have midline cervical tenderness (as this suggests a fracture or dislocation) or other serious injuries
- was involved in a simple rear-end collision
- is in a sitting position in the waiting room
- can walk about at any time after the injury
- has delayed onset of neck pain.<sup>42</sup>

Patients do not require cervical spine imaging if they are awake, alert, without neurological deficit and have no neck pain or tenderness with full range of motion of the cervical spine.<sup>37</sup>

## Imaging choice

There is no scientifically admissible evidence to support use of routine MRI as a screening tool in cervical trauma.<sup>33</sup>

### X-ray

There is strong evidence to suggest that use of routine cervical spine radiographs alone (compared to CT scans) may miss important injuries in the evaluation of patients with traumatic, high-risk neck injuries in emergency situations, and that CT scan should be used instead.<sup>31</sup>



Even when using a three-view X-ray series, there is evidence of missed injuries in up to 57% of high-risk patients and in 7–35% of patients overall. Additionally, the three-view series can be difficult to obtain, with reports of inadequate visualisation in 50–80% of initial and 25% of repeat radiographs.<sup>43</sup>

However, flexion–extension X-rays are still an important tool in the assessment of patients with cervical spine injuries, and may be useful in excluding dynamic instability, particularly in those patients who have sustained a significant ligamentous injury and no fracture.

## CT

CT scans have better validity than radiographs in assessing high-risk and/or multi-injured blunt trauma neck patients.<sup>31</sup> There is evidence that CT should be the preferred imaging modality, replacing plain films in the initial evaluation of suspected cervical spine injuries.<sup>43</sup>

CT is superior to MRI in identifying bony injuries such as osseous fracture, vertebral subluxation/dislocation and locked facets.<sup>37</sup>

Modern CT alone is sufficient to detect unstable cervical spine injuries in trauma patients. Adjuvant imaging is unnecessary when the CT scan is negative for acute injury.<sup>44</sup>

## MRI

MRI is not suitable for detecting fracture.

MRI is superior at identifying soft tissue injuries, such as spinal cord injury and ligamentous injury.<sup>37</sup> MRI is preferred for evaluating possible ligamentous injuries in acute cervical spine trauma and possible spinal cord injury.<sup>39</sup>

Note that role of MRI in evaluating ligamentous and membranous abnormalities in patients with whiplash-associated disorders is controversial.<sup>45</sup> There is evidence that MRI may not demonstrate soft tissue lesion in acute whiplash injury. MRI has been shown to reveal changes in the ligaments of the upper cervical spine in late stage whiplash injury; however, these findings may not be clinically significant, nor do they assist with treatment planning.<sup>31,45</sup>

MRI should be limited to patients in whom other studies are contraindicated or if the imaging fails to adequately clear the patient for suspected fracture.<sup>46</sup>

MRI is not required to clear the spine (rule out fracture) if a radiologist has reported a negative CT.<sup>44</sup>

## Imaging issues, benefits and risks

MRI is able to detect abnormalities not present with other imaging.<sup>47</sup> However, many findings will not be clinically significant.<sup>48</sup>

Despite its high sensitivity, in particular for soft tissue injury, MRI suffers from poor specificity in terms of determining clinically relevant information such as instability. It is thus rarely appropriate as a means of achieving cervical spine clearance.

The risk–benefit ratio of obtaining MRI in addition to CT is not clear and its use must be individualised.<sup>37</sup>



## MRI of the knee

### MBS item description

*Referral by a medical practitioner (excluding a specialist or consultant physician) for a scan of knee following acute knee trauma for a patient 16 years or older with:*

- **inability to extend the knee suggesting the possibility of acute meniscal tear (R) (K) (Contrast) (Anaes.); or**
- **clinical findings suggesting acute anterior cruciate ligament tear (R) (K) (Contrast) (Anaes.)**

### Key information

- MRI of the knee joint can lead to improved health outcomes by reducing (or eliminating) the need for diagnostic arthroscopy.
- In the majority of cases, clinical examination is as good as MRI for diagnosis.
- If a diagnosis is clear on clinical exam, confirmation with MRI is not routinely warranted.
- There is a role for MRI when the diagnosis is unclear and the level of patient disability/pain is such that surgery is being considered.
- Not all meniscal and anterior cruciate ligament (ACL) tears require surgery – low-grade injuries respond well to conservative therapies.

### Recommendations

Recommendation	Reference/Source	Grade*
MRI is indicated in the assessment of ACL injuries, but is not always necessary if the clinical diagnosis is clear	(49) New Zealand Guidelines Group. MRI guidelines for the diagnosis of soft tissue knee injuries, 2010	B
MRI is indicated for assessment of meniscal tears, but is not always necessary if a clear clinical diagnosis of meniscal tear has been made	(49) As above	B
Use MRI particularly in situations where there is doubt about diagnosis or patient management	(49) As above (50) Ryzewicz M, Peterson B, Siparsky PN, Bartz RL. The diagnosis of meniscus tears: the role of MRI and clinical examination, 2007	B Level II
Do not use MRI for the diagnosis of isolated medial collateral ligament injuries, except where there is concern about alternative pathology or if symptoms fail to settle after 6–8 weeks	(49) As above	C
Further testing is not immediately needed in patients with knee injury who have negative physical examination findings, although close follow-up is required	(51) Tuite MJ, Daffner RH, Weissman BN, et al. ACR appropriateness criteria – acute trauma to the knee, 2012	None given

\*Refer to [Appendix 1, Table 1.5](#), for an explanation of the Grade



## Background

Acute knee presentations are diagnosed by history, physical examination and plain X-ray (where indicated for suspected bony injury). Urgent further imaging is rarely indicated. Re-examination after a period of conservative management is recommended and at that time further imaging may be considered if it is likely to alter ongoing management.

### ACL injury

#### History

Patients may report a popping sensation, or a sensation that the knee ‘came apart’, during sudden deceleration, stopping or change of direction (with a fixed foot, or hyperextension or posteroanterior force to the tibia). People engaged in sport at the time typically need to be helped from the field. There may be significant swelling within a few hours of the injury.<sup>52</sup>

#### Physical examination

The acute swelling that can accompany injuries may make the initial physical examination difficult. If a fracture is unlikely, a repeat examination in 1–2 weeks is recommended.<sup>53</sup>

Tests for ACL injury include the [Lachman test](#), the pivot shift test and anterior drawer sign. The Lachman test, when correctly performed, is the most validated test for diagnosing ACL integrity and further imaging (with MRI) is unnecessary.<sup>53,54</sup>

### Meniscal injury

#### History

Meniscal injuries typically occur during twisting or pivoting, and there may be no or minimal force required to cause a tear in middle-aged and older people. Patients may describe locking and/or catching of the knee, although these are not specific for meniscal injuries. Swelling is usually mild to moderate and takes hours (up to 36) to appear. The swelling may recur during the weeks following the injury.<sup>52</sup>

#### Physical examination

There may be an effusion, joint line tenderness and a block to full extension.<sup>52</sup>

Tests for meniscal injury include the [Thessaly test](#) (pain on twisting on the knee while standing with it bent at 5 and 20 degrees of flexion), the Apley test, joint line tenderness and McMurray test. The Thessaly test at 20 degrees of knee flexion can be used safely and effectively as a first-line screening test for the diagnosis of both medial and lateral meniscal tears.<sup>55</sup>

Combined findings from the history and physical examination are more clinically helpful than any one examination manoeuvre alone, and a thorough examination can be as accurate as MRI.<sup>53,56</sup>



## Imaging choice

### X-ray

The [Ottawa Knee Rules](#) are highly sensitive for identifying knee fractures and should be used to determine which patients with acute knee injury require radiography.<sup>51,57</sup>

X-rays are not indicated for soft tissue injury assessment of the knee.

### Ultrasound

Ultrasound is not recommended for evaluation of menisci or cruciate ligament injuries.<sup>49</sup>

### MRI

MRI is the imaging of choice for internal knee derangement.<sup>51</sup> However, its use should be confined to more doubtful, difficult and complex knee injuries.<sup>56</sup>

### Imaging issues, benefits and risks

Clinical examination, when combined with MRI, provides the most accurate non-invasive source of information currently available for pathological findings in the menisci and the ACL.<sup>58</sup>

When comparing MRI and diagnostic arthroscopy for ACL and meniscal tears, MRI is superior and offers the health benefit of avoiding invasive surgery.<sup>50</sup> In one study, almost half of patients presenting with an acutely locked knee had their management changed from surgical to conservative based on MRI findings.<sup>51</sup>

However, careful evaluation by an experienced examiner identifies patients with surgically treatable meniscus and ACL tears with equal (or better) reliability than MRI.<sup>50,53,54</sup>

The ACL can regain continuity after partial or complete rupture.<sup>59</sup> Hence, the relative efficacy of surgical reconstruction and rehabilitation for the short-term and long-term outcomes after ACL rupture is debated. Results of a 2013 randomised controlled trial encourage doctors to consider rehabilitation as a primary treatment option following an acute ACL tear in young adults.<sup>60</sup>

MRI studies have higher false positive than false negative results.<sup>54,58</sup> MRI shows lesions in the knee joint in most (almost 90%) middle-aged and elderly people in whom knee radiographs do not show any features of osteoarthritis, regardless of pain.<sup>61</sup>

MRI has been shown to have a false positive rate of 65% for identifying medial meniscal tears and 43% for lateral meniscus tears when compared with surgical findings.<sup>62</sup>

MRI of the knee is often performed in cases where a diagnosis is uncertain, and abnormal findings, such as meniscal tears, could be suspected to be the cause of the symptoms. However, incidental meniscal findings are common on MRI within the general population. For example in one study, 19% of women aged 50–59 years and 56% of men aged 70–90 years had asymptomatic meniscal injuries on MRI. Meniscal findings have been shown to increase with age.<sup>63</sup>

Additionally, no conclusion can be drawn about the natural course of meniscal injury seen at MRI imaging.<sup>59</sup> A period of conservative management and re-evaluation is warranted in most cases.



MRI is not effective at detecting all forms of injury of the knee. For example:

- radial meniscal injuries are difficult to visualise on MRI and account for a large number of tears missed by MRI<sup>58</sup>
- MRI is not the most reliable tool for diagnosing recurrent meniscal tears, detecting only 66% compared with 88% with arthrography<sup>58</sup>
- the accuracy of MRI decreases in patients with multiple injuries.<sup>64</sup>

MRI is the method of choice for the non-invasive diagnosis of meniscal and ACL tears. Despite the high performance of this method, some cases are challenging and the criteria described in the literature are not sufficient to reach a diagnosis.<sup>65</sup>



## Appendix 1: Recommendation tables including explanation of grades

As described in the *Preamble*, the recommendation tables throughout the guidance include the references and sources of recommendations and the recommendation grade. The detailed tables below include further information on the evidence grade, where available.

**Table 1.1 Recommendations table for MRI of the head – unexplained seizures**

Recommendation	Reference/Source	Grade
Brain imaging with CT or MRI should be considered as part of the routine neurodiagnostic evaluation of adults presenting with an apparent unprovoked first seizure	(7) Krumholz A, Wiebe S, Gronseth G, et al. Practice parameter: Evaluating an apparent unprovoked first seizure in adults, 2007	B – Probably effective, ineffective or harmful (or probably useful/predictive or not useful/predictive) for the given condition in the specified population. (Level B rating requires at least one Class I study or at least two consistent Class II studies.)
CT has a role in the urgent assessment of seizures, or when MRI is contraindicated or unavailable	(8) SIGN. Diagnosis and management of epilepsy in adults: a national clinical guideline, 2003	D – Evidence level 3 or 4 (non-analytic studies or expert opinion) or Extrapolated evidence from studies rated as 2+ (well-conducted case-control or cohort studies with a low risk of confounding or bias and a moderate probability that the relationship is causal)
MRI is the imaging investigation of choice for most unexplained seizures	(9) NICE. The epilepsies: diagnosis and management of the epilepsies in adults in primary and secondary care, 2012	None given





**Table 1.2 Recommendations table for MRI of the head – unexplained chronic headache**

Recommendation	Reference/Source	Grade
Neuroimaging should be considered in patients with headache and an unexplained abnormal finding on the neurological examination	(20) SIGN. Diagnosis and management of headache in adults, 2008	B – High-quality systematic reviews of case-control or cohort studies, directly applicable to the target population, and demonstrating overall consistency of results or Extrapolated evidence from high quality meta-analyses, systematic reviews of randomised controlled trials (RCTs), or RCTs with a very low risk of bias or well conducted meta-analyses, systematic reviews, or RCTs with a low risk of bias.
Neuroimaging could be considered for headache worsened by Valsalva manoeuvre, headache causing awakening from sleep, new headache in an older patient, or progressively worsening headache*	(21) Frishberg BM, Rosenberg JH, Matchar DB, et al. Evidence-based guidelines in the primary care setting: neuroimaging in patients with nonacute headache, 2000	C The US Headache Consortium achieved consensus on the recommendation in the absence of relevant RCTs
Neuroimaging is not indicated for people diagnosed with tension-type headache, migraine, cluster headache or medication overuse headache <b>solely for reassurance</b>	(22) NICE. Headaches: diagnosis and management of headaches in young people and adults, 2012	None given

\*While these may indicate a higher likelihood of significant intracranial pathology, as reported in several small studies, the evidence is insufficient to make specific recommendations regarding neuroimaging in the presence or absence of neurological symptoms.<sup>21</sup>



**Table 1.3 Recommendations table for MRI of the cervical spine – cervical radiculopathy**

Recommendation	Reference/Source	Grade
MRI is suggested for the confirmation of correlative compressive lesions* of the cervical spine in patients who have failed a course of conservative therapy and who may be candidates for interventional or surgical treatment	(29) NASS. Diagnosis and treatment of cervical radiculopathy from degenerative disorders, 2010	B Fair evidence (Level II or III studies with consistent findings) for or against recommending intervention  For more information on levels of evidence see the US National Guideline Clearinghouse at <a href="http://www.guideline.gov/content.aspx?id=23938#Section420">www.guideline.gov/content.aspx?id=23938#Section420</a>
Consider MRI when cervical radiculopathy has been present for 6 weeks and is not improving	(30) NICE online: Neck pain – cervical radiculopathy, revised 2009	None given
Cervical X-rays and other imaging studies and investigations are not routinely required to diagnose or assess neck pain with radiculopathy	(30) As above	None given

\*Disc herniation and spondylosis



Recommendation	Reference/Source	Grade
Cervical spine imaging is not indicated in awake, alert patients with trauma without neurological deficit or distracting* injury who have no neck pain or tenderness with full range of motion of the cervical spine	(37) Como JJ, Diaz JJ, Dunham CM, et al. Practice management guidelines for identification of cervical spine injuries following trauma, 2009	Level 2 – The recommendation is reasonably justifiable by available scientific evidence and strongly supported by expert opinion. This recommendation is usually supported by Class II data or a preponderance of Class III evidence.  Class II: clinical studies in which data were collected prospectively or retrospective analyses based on clearly reliable data (20 references)  Class III: studies based on retrospectively collected data (32 references)
If a cervical spine fracture is suspected then imaging with CT or X-ray is indicated	(38) Bussi�eres AE, Taylor JA, Peterson C, et al. Diagnostic imaging practice guidelines for musculoskeletal complaints in adults, 2008	B – A body of evidence including studies rated as 2++ directly applicable to the target population and demonstrating overall consistency of results  or  Extrapolated evidence from studies rated as 1++ or 1+  1++ High quality meta-analyses, systematic reviews of RCTs, or RCTs with a very low risk of bias  1+ Well-conducted meta-analyses, systematic reviews of RCTs, or RCTs with a low risk of bias
MRI has a role where other imaging is contraindicated/inconclusive or where clinical or imaging findings suggest ligamentous injury, spinal cord injury and/or arterial injury	(38) As above   (39) Daffner RH, Weissman BN, Angtuaco EJ, et al. ACR appropriateness criteria – suspected spine trauma, 2012	C – A body of evidence including studies rated as 2+ directly applicable to the target population and demonstrating overall consistency of results  or  Extrapolated evidence from studies rated as 2++  2+ Well-conducted case–control or cohort studies with a low risk of confounding, bias or chance and a moderate probability that the relationship is causal  2++ High-quality systematic reviews of case–control or cohort studies  or  High quality case–control or cohort studies with a very low risk of confounding, bias, or chance and a high probability that the relationship is causal



Table 1.5 Recommendations table for MRI of the knee

Recommendation	Reference/Source	Grade
MRI is indicated in the assessment of ACL injuries, but is not always necessary if the clinical diagnosis is clear	(49) New Zealand Guidelines Group. MRI guidelines for the diagnosis of soft tissue knee injuries, 2010	B - The recommendation is supported by fair evidence (consistent results from multiple studies, but with some risk of bias).
MRI is indicated for assessment of meniscal tears, but is not always necessary if a clear clinical diagnosis of meniscal tear has been made	(49) As above	B – As above
Use MRI particularly in situations where there is doubt about diagnosis or patient management	(49) As above (50) Ryzewicz M, Peterson B, Siparsky PN, Bartz RL. The diagnosis of meniscus tears: the role of MRI and clinical examination, 2007	B – As above Level II – Systematic review
Do not use MRI for the diagnosis of isolated medial collateral ligament injuries, except where there is concern about alternative pathology or if symptoms fail to settle after 6–8 weeks	(49) As above	C – The recommendation is supported by expert opinion only, based on level 4 evidence in the text, and the expertise within the multidisciplinary team.
Further testing is not immediately needed in patients with knee injury who have negative physical examination findings, although close follow-up is required	(51) Tuite MJ, Daffner RH, Weissman BN, et al. ACR appropriateness criteria – acute trauma to the knee, 2012	None given



## Appendix 2: Internal document hyperlink repository

### Bookmarks for seizures

**Table 2.1 Generalised seizures**

Types of generalised seizures include: <sup>9</sup>
<ul style="list-style-type: none"> <li>• <b>tonic</b> seizures, which cause impairment of consciousness and stiffening; the trunk may be either straight or flexed at the waist</li> <li>• <b>clonic</b> seizures, which cause jerking and impairment of consciousness</li> <li>• <b>tonic-clonic</b> seizures, which cause stiffening and jerking and impairment of consciousness</li> <li>• typical <b>absence</b> seizures, which begin in childhood and are therefore outside of this guidance</li> <li>• <b>myoclonic</b> seizures, which cause brief, shock-like contraction of the limbs, without apparent impairment of consciousness</li> <li>• <b>atonic</b> seizures, which cause sudden brief attacks of loss of tone associated with falls and impairment of consciousness.</li> </ul>

**Secondary generalised seizures** start with a focal seizure before spreading to cause a generalised seizure.<sup>8</sup>

**Table 2.2 Focal (partial seizures)**

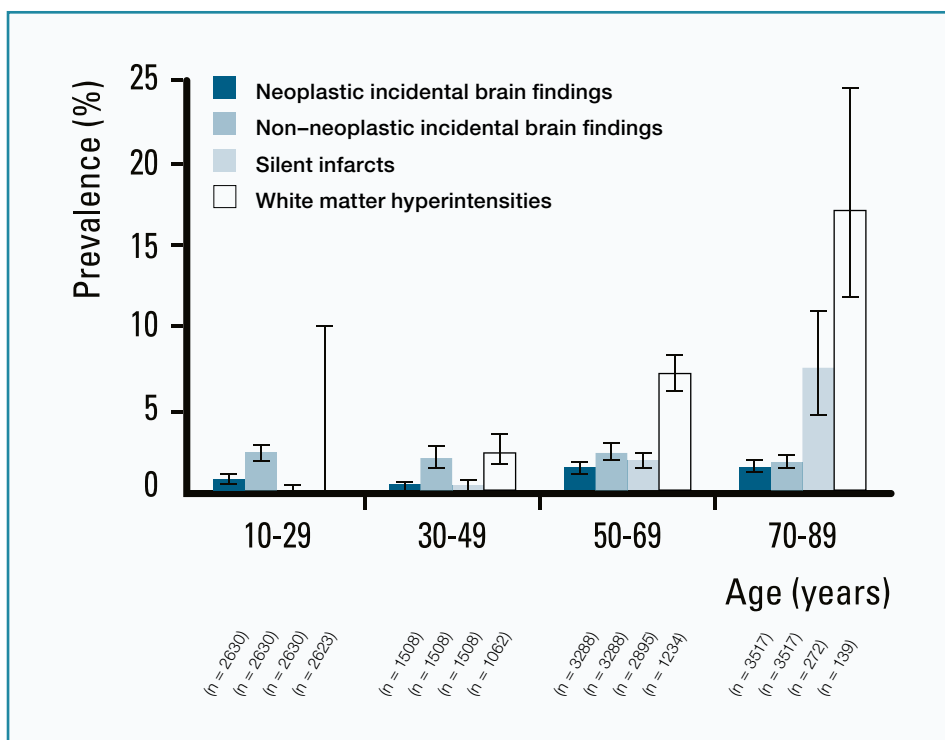
Types of focal (partial seizures) include: <sup>9</sup>
<ul style="list-style-type: none"> <li>• <b>focal motor</b> seizures, which cause a jerking movement that typically begins in the face or in one hand and spreads to involve the limbs. Focal motor seizures may also present with apparently purposeful movements such as turning the head, eye movements, smacking the lips, mouth movements, drooling, or rhythmic muscle contractions in a part of the body. Weakness of the limb may occur for several hours after the seizure</li> <li>• <b>focal sensory</b> seizures, including temporal lobe seizures, where consciousness may be fully retained (simple partial seizures) or associated with impaired consciousness (complex partial seizures) during an attack. These may cause sensory, autonomic, emotional, cognitive or other changes.</li> </ul>

**Table 2.3 Factors associated with intracranial pathology on neuroimaging after first seizure**

Factors associated with intracranial pathology on neuroimaging after first seizure include: <sup>11,14</sup>
<ul style="list-style-type: none"> <li>• alcohol abuse</li> <li>• bleeding disorders or anticoagulation therapy</li> <li>• focal seizure or new focal deficit</li> <li>• history of or current cysticercosis (or recent travel to endemic area)</li> <li>• history of stroke or malignancy</li> <li>• human immunodeficiency virus infection/AIDS</li> <li>• hydrocephalus or recent cerebrospinal fluid shunt surgery</li> <li>• neurocutaneous disorders</li> <li>• patient older than 65 years or younger than 6 months</li> <li>• persistent altered mental status</li> <li>• recent head trauma</li> <li>• sickle cell disease.</li> </ul>



Figure 2.1 Prevalence of incidental findings in various age categories



Reproduced with permission from British Medical Journal Publishing Group Ltd from Morris et al. Incidental findings on brain magnetic resonance imaging: systematic review and meta-analysis. BMJ 2009;339:b3016 doi:10.1136/bmj.b3016.



## Bookmarks for headaches

**Table 2.4 Clinical patterns of primary headaches**

Headache feature	Tension-type headache		Migraine (with or without aura)		Cluster headache	
Pain location <sup>a</sup>	Bilateral		Unilateral or bilateral		Unilateral (around the eye, above the eye and along the side of the head/face)	
Pain quality	Pressing/tightening (non-pulsating)		Pulsating (throbbing or banging in young people aged 12–17 years)		Variable (can be sharp, boring, burning, throbbing or tightening)	
Pain intensity	Mild or moderate		Moderate or severe		Severe or very severe	
Effect on activities	Not aggravated by routine activities of daily living		Aggravated by, or causes avoidance of, routine activities of daily living		Restlessness or agitation	
Other symptoms	None		<p>Unusual sensitivity to light and/or sound or nausea and/or vomiting</p> <p><b>Aura<sup>b</sup></b></p> <p>Aura symptoms can occur with or without headache and:</p> <ul style="list-style-type: none"> <li>• are fully reversible</li> <li>• develop over at least 5 minutes</li> <li>• last 5–60 minutes.</li> </ul> <p>Typical aura symptoms include visual symptoms such as flickering lights, spots or lines and/or partial loss of vision; sensory symptoms such as numbness and/or pins and needles; and/or speech disturbance.</p>		<p>On the same side as the headache:</p> <ul style="list-style-type: none"> <li>• red and/or watery eye</li> <li>• nasal congestion and/or runny nose</li> <li>• swollen eyelid</li> <li>• forehead and facial sweating</li> <li>• constricted pupil and/or drooping eyelid.</li> </ul>	
Duration of headache	30 minutes – continuous		4–72 hours in adults 1–72 hours in young people aged 12–17 years		15–180 minutes	
Frequency of headache	< 15 days per month	≥ 15 days per month for more than 3 months	< 15 days per month	≥ 15 days per month for more than 3 months	1 every other day to 8 per day <sup>b</sup> , with remission <sup>d</sup> > 1 month	1 every other day to 8 per day <sup>c</sup> , with a continuous remission <sup>d</sup> < 1 month in a 12 month period



Diagnosis	Episodic tension-type headache	Chronic tension type headache <sup>e</sup>	Episodic migraine (with or without the aura)	Chronic migraine <sup>f</sup> (with or without aura)	Episodic cluster headache	Chronic cluster headache
<p><sup>a</sup> Headache pain can be felt in the head, face or neck.</p> <p><sup>b</sup> See recommendations 1.2.2, 1.2.3 and 1.2.4 for further information of migraine with aura.</p> <p><sup>c</sup> The frequency of recurrent headaches during a cluster bout.</p> <p><sup>d</sup> The pain-free period between cluster headache bouts.</p> <p><sup>e</sup> Chronic migraine and chronic tension-type headache commonly overlap. If there are any features of migraine, diagnose chronic migraine.</p> <p><sup>f</sup> NICE has developed technology appraisal guidance on Botulinum toxin type A for the prevention of headaches in adults with chronic migraine (headaches on at least 15 days per month of which at least 8 days are with migraine).</p>						

Reproduced with permission from National Institute for Health and Care Excellence (NICE) from Diagnosis of tension-type, migraine and cluster headache, from Headaches: diagnosis and management of headaches in young people and adults. National Clinical Guideline Centre. p 44.

**Table 2.5 Intracranial tumours**

Intracranial tumours
<p>Intracranial tumours only present as headache in 3–4% of cases. Typically they do not cause headache until they are quite large, although pituitary tumours are an exception.<sup>24</sup></p> <p>The incidence of headache with brain tumour is the same as the incidence of headache in the general population.<sup>15</sup></p> <p>Brain tumours are more common in males and with increasing age. Most malignant tumours are fatal, but approximately 30% are benign (e.g. meningioma) and grow slowly.<sup>15</sup></p> <p>Raised intracranial pressure is apparent in the history and epilepsy is a cardinal symptom of intracerebral space-occupying lesions. Loss of consciousness should be viewed very seriously.<sup>24</sup></p> <p>Most patients with brain tumour present with seizures or focal neurological signs rather than headache.<sup>24,66</sup></p>

**Table 2.6 Giant cell arteritis**

Giant cell arteritis
<p>Giant cell arteritis (GCA) is the result of inflammation of the cranial arteries, especially branches of the external carotid artery.<sup>67</sup></p> <p>The variability in symptoms is such that any recent persisting headache in a patient over 60 years of age should raise the suspicion of GCA. Headache is the best known symptom but it is very variable and not always present. When present, it is likely to be persistent, worse at night and it can be severe. It is localised to the temple(s) in only a minority of cases.<sup>24</sup></p> <p>Patients with GCA may be systemically unwell. Jaw claudication may be absent, but when it is present, it is highly suggestive of GCA.<sup>67</sup> Most but not all patients have temporal artery tenderness and/or diminished pulsation.</p> <p>Because of the risk of blindness due to anterior ischaemic optic neuropathy, high-dose oral steroids should commence urgently and before waiting for temporal artery biopsy.</p> <p>MRI does not detect GCA.</p>





**Table 2.7 The SNOOP-4 mnemonic**

The SNOOP-4 mnemonic <sup>28</sup>
<b>S</b> ystemic symptoms (fever, weight loss) or secondary risk factors (HIV, cancer)
<b>N</b> eurological symptoms or abnormal signs (confusion, impaired alertness or consciousness)
<b>O</b> nset – sudden, abrupt or split second ('thunderclap')
<b>O</b> lder – new onset or progressive headache, especially in patients older than 50 years (giant cell arteritis)
<b>P</b> revious headache history – first headache or different headache (change in attack frequency, severity or clinical features)
<b>P</b> ostural or positional aggravation
<b>P</b> recipitated by a Valsalva manoeuvre or exertion
<b>P</b> apilloedema

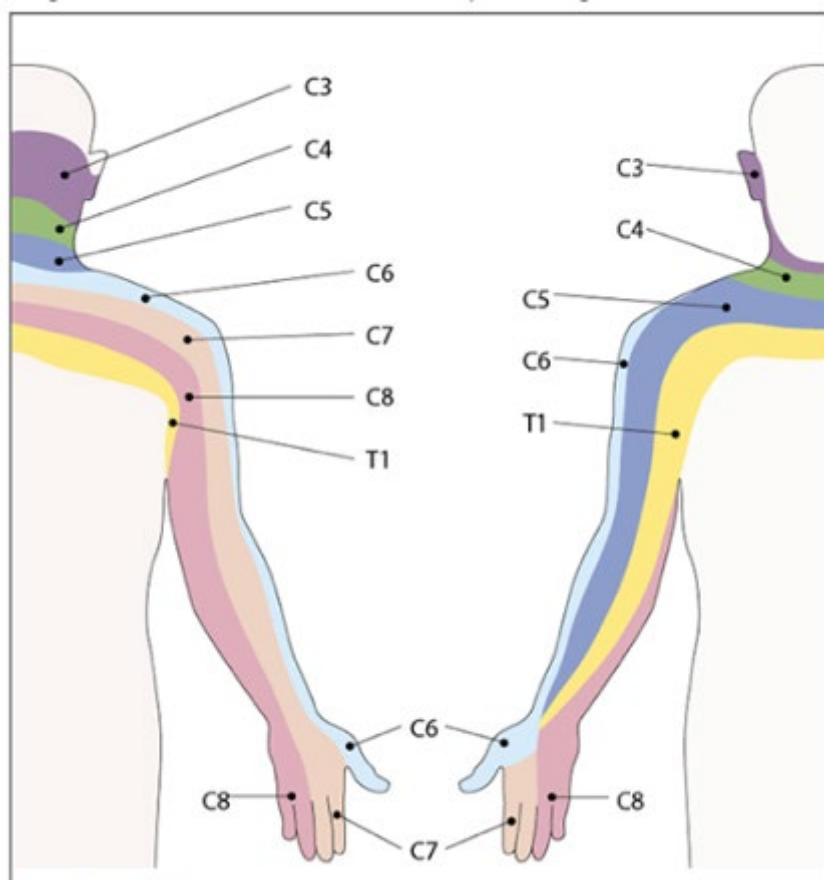
## Bookmarks for cervical radiculopathy

**Table 2.8 Neurological features associated with cervical radiculopathy**

Nerve root	Muscle weakness	Reflex changes	Sensory changes
C5	Shoulder abduction and flexion Elbow flexion	Biceps	Lateral arm
C6	Elbow flexion Wrist extension	Biceps Supinator	Lateral forearm Thumb Index finger
C7	Elbow extension Wrist flexion Finger extension	Triceps	Middle finger
C8	Finger flexion	None	Medial side lower forearm Ring and little fingers
T1	Finger abduction and adduction	None	Medial side lower forearm Lower arm

Reproduced with permission from British Medical Journal Publishing Group Ltd, from Barry M, Jenner JR. ABC of rheumatology. Pain in neck, shoulder, and arm. BMJ 1995; 310(6973):183–6.



**Figure 2.2 Upper limb dermatomes**

Reproduced with permission from Continuing Medical Education (CME) from Mogere E, Morgado T, Welsh D. An approach to the painful upper limb. Continuing Medical Education 2013;31(3). Available at [www.cmej.org.za/index.php/cmej/rt/prINTERfriendly/2708/2829](http://www.cmej.org.za/index.php/cmej/rt/prINTERfriendly/2708/2829)

**Table 2.9 Signs of serious spinal or other abnormalities**

**Signs of serious spinal or other abnormalities include:<sup>30</sup>**

- compression of the spinal cord (myelopathy) – neurological symptoms and signs such as gait disturbance, clumsy or weak hands; sensory changes for example loss of vibration
- cancer, infection or inflammation – malaise, fever, unexplained weight loss, unremitting pain affecting sleep, lymphadenopathy, bony tenderness
- severe trauma or skeletal injury – a history of violent trauma, neck surgery, risk factors for osteoporosis
- vascular insufficiency – dizziness and blackouts on movement and extension of the neck or drop attacks.

Note there is insufficient available evidence to confirm the utility of conventional 'red flag symptom' for triaging non-acute neck patients, although their use has been strongly encouraged.<sup>31</sup>



# Bookmarks for cervical trauma

Table 2.10 NEXUS criteria

The presence of all five criteria indicates no risk of cervical spine fracture, and cervical radiography is not necessary.
1. Absence of posterior midline tenderness
2. Absence of focal neurological deficit
3. Normal level of alertness
4. No evidence of intoxication
5. Absence of painful distracting injury

Adapted and reproduced with permission from the New England Journal of Medicine from Hoffman J, Mower W, Wolfson A, et al. Validity of a set of clinical criteria to rule out injury to the cervical spine in patients with blunt trauma. N Engl J Med 2000;343:94–9.

# Bookmarks for the knee

Table 2.11 The Ottawa knee rules

The Ottawa knee rules
Knee X-ray indicators after acute and knee injury;
<ul style="list-style-type: none"><li>• aged 55 years or over</li><li>• tenderness at the head of the fibula</li><li>• isolated tenderness of the patella</li><li>• inability to flex knee to 90 degrees</li><li>• inability to bear weight (defined as an inability to take four steps, i.e. two steps on each leg, regardless of limping) immediately and at presentation.</li></ul>

Reproduced with permission from The Royal Australian College of General Practitioners from Yao K, Haque T. The Ottawa knee rules: a useful clinical decision tool. Aust Fam Physician 2012;41(4):223–4.



## References

1. Chou R, Qaseem A, Owens DK, Shekelle P. Clinical Guidelines Committee of the American College of Physicians. Diagnostic imaging for low back pain: advice for high-value health care from the American College of Physicians. *Ann Intern Med* 2011;154(3):181–89.
2. Brito JP, Morris JC, Montori VM. Thyroid cancer: zealous imaging has increased detection and treatment of low risk tumours. *BMJ* 2013;347:f4706.
3. Royal Australian and New Zealand College of Radiologists (RANZCR). Radiology written report guideline, (short) version 5 (final). Sydney: RANZCR, 2011.
4. Lehnert BE, Bree RL. Analysis of appropriateness of outpatient CT and MRI referred from primary care clinics at an academic medical center: how critical is the need for improved decision support? *J Am Coll Radiol* 2010;7(3):192–97.
5. Moynihan R, Doust J, Henry D. Preventing overdiagnosis: how to stop harming the healthy. *BMJ* 2012;344:e3502.
6. Royal Australian and New Zealand College of Radiologists (RANZCR). Guidance for GP referrals for MRI studies. Sydney: RANZCR, 2013.
7. Krumholz A, Wiebe S, Gronseth G, et al. Practice parameter: Evaluating an apparent unprovoked first seizure in adults (an evidence-based review): report of the quality standards subcommittee of the American Academy of Neurology and the American Epilepsy Society. *Neurology* 2007;69(21):1996–2007.
8. Scottish Intercollegiate Guidelines Network (SIGN). Diagnosis and management of epilepsy in adults: a national clinical guideline. Edinburgh: SIGN, 2003.
9. National Institute for Health and Clinical Excellence (NICE). The epilepsies: diagnosis and management of the epilepsies in adults in primary and secondary care. London: NICE, 2012.
10. King MA, Newton MR, Jackson GD, et al. Epileptology of the first-seizure presentation: a clinical, electroencephalographic, and magnetic resonance imaging study of 300 consecutive patients. *Lancet* 1998;352(9133):1007–11.
11. Wilden JA, Cohen-Gadol AA. Evaluation of first nonfebrile seizures. *Am Fam Physician* 2012;86(4):334.
12. Berg AT. Risk of recurrence after a first unprovoked seizure. *Epilepsia* 2008;49:13–18.
13. Pohlmann-Eden B, Beghi E, Camfield C, Camfield P. The first seizure and its management in adults and children. *BMJ* 2006;332(7537):339–42.
14. Adams SM, Knowles PD. Evaluation of a first seizure. *Am Fam Physician* 2007;75:1342–47.
15. Hamilton W, Kernick D. Clinical features of primary brain tumours: a case-control study using electronic primary care records. *Br J Gen Pract* 2007;57(542):695–9.
16. Harden CL, Huff JS, Schwartz TH, et al. Reassessment: Neuroimaging in the emergency patient presenting with seizure (an evidence-based review): report of the therapeutics and technology assessment subcommittee of the American Academy of Neurology. *Neurology* 2007;69(18):1772–80.
17. Smirniotopoulos JG, Wippold FJ, Cornelius RS, Angtuaco EJ, Broderick DF, Brown DC. Expert panel on neurologic imaging. ACR appropriateness criteria – seizures and epilepsy [Online publication]. Reston, VA: American College of Radiology (ACR), 2011.
18. Morris Z, Whiteley WN, Longstreth WT, et al. Incidental findings on brain magnetic resonance imaging: systematic review and meta-analysis. *BMJ* 2009;339:b3016.
19. Vattipally VR, Bronen RA. MR imaging of epilepsy: strategies for successful interpretation. *Neuroimaging Clin N Am* 2004;14(3):349–72.
20. Scottish Intercollegiate Guidelines Network (SIGN). Diagnosis and management of headache in adults. A national clinical guide. Edinburgh: NHS Scotland, 2008.
21. Frishberg BM, Rosenberg JH, Matchar DB, et al. Evidence-based guidelines in the primary care setting: neuroimaging in patients with nonacute headache. *The American Academy of Neurology*, 2000.
22. National Clinical Guideline Centre. Headaches: diagnosis and management of headaches in young people and adults. Methods, evidence and recommendations. London: NICE, 2012.
23. Nunes VD, Sawyer L, Neilson J, Sarri G, Cross JH. Diagnosis and management of the epilepsies in adults and children: Summary of updated NICE guidance. *BMJ* 2012;344:e281.
24. Steiner TJ, MacGregor EA, Davies PTG. Guidelines for all healthcare professionals in the diagnosis and management of migraine, tension-type, cluster and medication-overuse headache. *British Association for the Study of Headache* 2007;2007:1–52.
25. Bogduk N. The anatomical basis for cervicogenic headache. *Journal of Manipulative and Physiological Therapeutics* 1992;15(1):67–70.



26. Carville S, Padhi S, Reason T, Underwood M. Diagnosis and management of headaches in young people and adults: summary of NICE guidance. *BMJ* 2012;345:e5765 doi:10.1136/bmj.e5765.
27. Davies MB. How do I diagnose headache? *J R Coll Physicians Edinb* 2006;36(4):336.
28. Zagami AS, Goddard SL. Recurrent headaches with visual disturbance. *Med J Aust* 2012;196(3):178–83.
29. North American Spine Society (NASS). Diagnosis and treatment of cervical radiculopathy from degenerative disorders. Burr Ridge, Ill: NASS, 2010.
30. National Institute for Health and Clinical Excellence (NICE). Clinical knowledge summaries: neck pain – cervical radiculopathy. Revised January 2009. Available at <http://cks.nice.org.uk/neck-pain-cervical-radiculopathy#!topicsummary>.
31. Nordin M, Carragee EJ, Hogg-Johnson S, et al. Assessment of neck pain and its associated disorders. *Eur Spine J* 2008;17(1):101–22.
32. Kuijper B, Beelen A, van der Kallen BF, et al. Interobserver agreement on MRI evaluation of patients with cervical radiculopathy. *Clin Radiol* 2011;66(1):25–29.
33. Guzman J, Haldeman S, Carroll LJ, et al. Clinical practice implications of the bone and joint decade 2000-2010 task force on neck pain and its associated disorders: from concepts and findings to recommendations. *J Manipulative Physiol Ther* 2009;32(2 Suppl):S227–S43.
34. Reneman L, de Win MM, Booi J, et al. Incidental head and neck findings on MRI in young healthy volunteers: prevalence and clinical implications. *Am J Neuroradiol* 2012;33(10):1971–74.
35. Boden SD, Davis DO, Dina TS, Patronas NJ, Wiesel SW. Abnormal magnetic-resonance scans of the lumbar spine in asymptomatic subjects. A prospective investigation. *J Bone Joint Surg Am* 1990;72(3):403–8.
36. Medical PA Criteria Proposal. MRI of cervical spine. ACS Heritage, 2005.
37. Como JJ, Diaz JJ, Dunham CM, et al. Practice management guidelines for identification of cervical spine injuries following trauma: update from the Eastern Association for the Surgery of Trauma Practice Management Guidelines Committee. *J Trauma* 2009;67(3):651–59.
38. Bussi eres AE, Taylor JA, Peterson C. Diagnostic imaging practice guidelines for musculoskeletal complaints in adults – an evidence-based approach. Part 3: Spinal disorders. *J Manipulative Physiol Ther* 2008;31(1):33–88.
39. Daffner RH, Weissman BN, Angtuaco EJ, et al. ACR appropriateness criteria® – suspected spine trauma [Online publication]. Reston, VA: American College of Radiology, 2012.
40. Blackmore CC. Evidence-based imaging evaluation of the cervical spine in trauma. *Neuroimaging Clinics of North America* 2003;13(2):283–91.
41. National Institute for Health and Care Excellence (NICE). Clinical knowledge summaries: neck pain – whiplash injury. Available at <http://cks.nice.org.uk/neck-pain-whiplash-injury#!backgroundsub>.
42. National Institute for Health and Care Excellence (NICE). Clinical knowledge summaries: neck pain – non-specific. Available at <http://cks.nice.org.uk/neck-pain-non-specific#!diagnosis>.
43. Greenbaum J, Walters N, Levy PD. An evidence-based approach to radiographic assessment of cervical spine injuries in the emergency department. *J Emerg Med* 2009;36(1):64–71.
44. Blackham J, Benger J. Clearing the cervical spine in the unconscious trauma patient. *Trauma* 2011;13(1):65–79.
45. Kongsted A, Sorensen JS, Andersen H, Keseler B, Jensen TS, Bendix T. Are early MRI findings correlated with long-lasting symptoms following whiplash injury? A prospective trial with 1-year follow-up. *Eur Spine J* 2008;17(8):996–1005.
46. Horn EM, Lekovic GP, Feiz-Erfan I, Sonntag VK, Theodore N. Cervical magnetic resonance imaging abnormalities not predictive of cervical spine instability in traumatically injured patients: invited submission from the joint section meeting on disorders of the spine and peripheral nerves. *J Neurosurg Spine* 2004;1(1):39–42.
47. Muchow RD, Resnick DK, Abdel MP, Munoz A, Anderson PA. Magnetic resonance imaging (MRI) in the clearance of the cervical spine in blunt trauma: a meta-analysis. *J Trauma Acute Care Surg* 2008;64(1):179–89.
48. Schuster R, Waxman K, Sanchez B, et al. Magnetic resonance imaging is not needed to clear cervical spines in blunt trauma patients with normal computed tomographic results and no motor deficits. *Arch Surg* 2005;140(8):762.
49. New Zealand Guidelines Group. MRI guidelines for the diagnosis of soft tissue knee injuries: internal derangements updated by ACC. Auckland: Accident Compensation Corporation; 2010.
50. Ryzewicz M, Peterson B, Siparsky PN, Bartz RL. The diagnosis of meniscus tears: the role of MRI and clinical examination. *Clin Orthop Relat Res* 2007;455:123–33.
51. Tuite MJ, Daffner RH, Weissman BN, et al. ACR appropriateness criteria® – acute trauma to the knee. *J Am Coll Radiol* 2012;9(2):96–103.
52. National Institute for Health and Care Excellence (NICE). Clinical knowledge summaries: knee pain – assessment. Available at <http://cks.nice.org.uk/knee-pain-assessment>.
53. Grover M. Evaluating acutely injured patients for internal derangement of the knee. *Am Fam Physician* 2012;85(3):247–52.



54. Benjaminse A, Gokeler A, van der Schans CP. Clinical diagnosis of an anterior cruciate ligament rupture: a meta-analysis. *J Orthop Sports Phys Ther* 2006;36(5):267–88.
55. Karachalios T, Hantes M, Zibis AH, Zachos V, Karantanas AH, Malizos KN. Diagnostic accuracy of a new clinical test (the Thessaly test) for early detection of meniscal tears. *J Bone Joint Surg* 2005;87(5):955–62.
56. Mohan BR, Gosal HS. Reliability of clinical diagnosis in meniscal tears. *Int Orthop* 2007;31(1):57–60.
57. Yao K, Haque T. The Ottawa knee rules – a useful clinical decision tool. *Aust Fam Physician* 2012;41(4):223–24.
58. Crawford R, Walley G, Bridgman S, Maffulli N. Magnetic resonance imaging versus arthroscopy in the diagnosis of knee pathology, concentrating on meniscal lesions and ACL tears: a systematic review. *Br Med Bull* 2007;84:5–23.
59. Boks SS, Vroegindeweij D, Koes BW, Hunink MG, Bierma-Zeinstra SM. Follow-up of posttraumatic ligamentous and meniscal knee lesions detected at MR imaging: systematic review. *Radiology* 2006;238(3):863–71.
60. Frobell RB, Roos HP, Roos EM, Roemer FW, Ranstam J, Lohmander LS. Republished research: Treatment for acute anterior cruciate ligament tear: five year outcome of randomised trial. *Br J Sports Med* 2013;47(6):373.
61. Guermazi A, Niu J, Hayashi D, et al. Prevalence of abnormalities in knees detected by MRI in adults without knee osteoarthritis: population based observational study (Framingham Osteoarthritis Study). *BMJ* 2012;345:e5339.
62. Ben-Galim P, Steinberg EL, Amir H, Ash N, Dekel S, Arbel R. Accuracy of magnetic resonance imaging of the knee and unjustified surgery. *Clin Orthop Relat Res* 2006;447:100–4.
63. Englund M, Felson DT, Guermazi A, et al. Risk factors for medial meniscal pathology on knee MRI in older US adults: a multicentre prospective cohort study. *Ann Rheum Dis* 2011;70:1733–39.
64. Behairy NH, Dorgham MA, Khaled SA. Accuracy of routine magnetic resonance imaging in meniscal and ligamentous injuries of the knee: comparison with arthroscopy. *Int Orthop* 2009;33(4):961–67.
65. Oldrini G, Teixeira PG, Chanson A, et al. MRI appearance of the distal insertion of the anterior cruciate ligament of the knee: an additional criterion for ligament ruptures. *Skeletal Radiol* 2012;41(9):1111–20.
66. Grant R. Overview: brain tumour diagnosis and management/Royal College of Physicians guidelines. *J Neurol Neurosurg Psychiatry* 2004;75(Suppl 2):ii18–23.
67. Headache Classification Committee of the International Headache Society. The international classification of headache disorders, 3rd edition (beta version). *Cephalalgia* 2013;33(9):629–808.





Healthy Profession.  
Healthy Australia.

