

**Patrick J Phillips**

MBBS, MA(Oxon), FRACP, MRACMA, GDipHlthEcon(UNE), is Senior Director, Department of Endocrinology, The Queen Elizabeth Hospital, South Australia. patrick.phillips@nwahs.sa.gov.au

Warren Weightman

MBBS, FRACP, FACD, is Director of Dermatology, The Queen Elizabeth Hospital, Woodville, South Australia.

More than just dry skin

Case study

'I know there's something wrong with him. Over the past 6 months his skin has become dry as a bone, and he's puffy around the eyes. His hair is coarse, thick and dry like a broom, the skin on his hands is thick like leather and looks yellow in the sun. His voice is croaky. I've tried to stop him drinking but he still has his six 'stubbies' a night. I'm worried he's getting cirrhosis or cancer'.

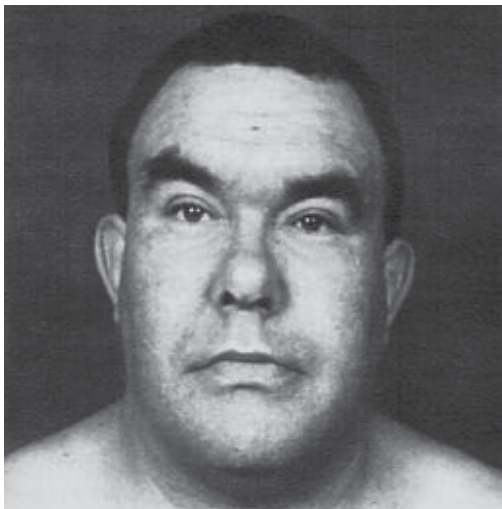


Table 1. Autoimmune endocrine and metabolic cluster

- Hypo- and hyper-thyroidism
- Pernicious anaemia
- Addison disease
- Hypogonadism
- Vitiligo and premature greyness
- Hypoparathyroidism

■ **Harriet is worried about her husband George. You don't see George very often but he certainly looks different. Apart from the changes described by Harriet, George has put on a lot of weight (from 97 to 112 kg since his last 'weigh in' 14 months ago). George is in his early 40s and in the past has been an active, quickly moving man despite his size (height 194 cm). Now he seems listless and lethargic.**

Examination confirms Harriet's observations. George's urinalysis is negative for bile, his blood pressure 166/102 (14 months ago 145/82). On two occasions you have to speak louder and you check his ears. His external canals and drums are clear but he does have an obstructive deafness on testing. George tells you he feels fine apart from numb fingers in the morning, which get better as the day goes on. His past history includes appendicectomy and tonsillectomy as a child and a partial thyroidectomy for Graves disease at age 35 years.

Question 1

What endocrine causes could be responsible for his skin signs?

Question 2

What other skin changes might be present?

Question 3

What other clinical features might be present?

Question 4

What tests are indicated?

Question 5

What other problems might George be prone to?

Answer 1

George is hypothyroid. However, sometimes patients with acromegaly have some of the changes affecting George: thick skin, coarsened features, and signs of nerve entrapment (eg. carpal tunnel syndrome). Type 2 diabetes is less likely to be confused, as it is associated with overweight, thickened skin (the so called cheiroarthropathy),¹ and nerve damage (generalised and entrapment).

However, given George's history of autoimmune thyroid disease (Graves disease), which is associated with antibodies that destroy as

well as stimulate the thyroid, and his partial thyroidectomy which reduced the amount of functioning thyroid tissue, a positive clinical diagnosis of hypothyroidism can confidently be made.

Answer 2

Skin changes reflect decreased sebaceous gland activity causing dryness of the skin and the hair. Build up of fluid containing mucopolysaccharides (myxoedema fluid) occurs, particularly in loose tissues such as those around the eyes. Accumulation of carotene in the epidermis, turning the skin yellow is seen, particularly where the skin is thick (eg. palms or soles). Carotene in foods such as carrots or brassica is usually converted to vitamin A but this conversion is slowed in hypothyroidism and leads to accumulation of carotene. The life cycle of body hair is also slowed and hair may be lost, usually in the outer eyebrows. An asteatotic eczema and brittle and striated nails can also develop.

Answer 3

Hypothyroidism is characterised by three general problems:

- fluid accumulation causing nonpitting oedema in the tissues (as above) and in body cavities: middle ear, peritoneal, pleural, joint and bursae. The fluid accumulation may also increase pressure on nerves as they pass through bony tunnels; most commonly the median nerve as it passes through the carpal tunnel at the wrist with pressure causing tingling, numbness and pain in the thenar eminence, thumb and first two fingers. George's deafness and morning hand discomfort were probably caused by fluid accumulation
- changed metabolism:
 - a decrease in metabolic rate causes the classic symptoms of cold intolerance, weight gain, constipation and slow metabolism. More subtle affects can also occur:
 - medication: clearance may be affected, increasing medication effect, and causing toxicity at usual doses. Paradoxically, more warfarin is needed because, although warfarin clearance is reduced, the clearance of clotting factors is even more reduced
 - body chemistry: as noted, carotene levels rise because of decreased conversion of vitamin A. Similarly the clearance of both cholesterol and creatine kinase are reduced and raised levels may lead to inappropriate treatment with a statin or misplaced concern about myocardial infarction. Hypercholesterolaemia may be associated with xanthelasmata and/or tender or tuberous xanthomas. Haemopoiesis is slowed causing anaemia and macrocytosis. Changes in sex hormone metabolism and protein binding may cause irregular periods and menorrhagia in women
 - neuromuscular abnormalities: from 'top to toe': 'myxoedema' madness, cerebral, cerebellar, and spinal cord syndromes; neuropathy and muscle cramps. A common clinical sign is 'hung up' reflexes where the usual quick relaxation following the twitch caused by tapping the tendon is markedly slowed

- thyroid enlargement: this is not likely in George given his thyroidectomy but potentially causes cosmetic concern, discomfort (particularly in certain positions) and thoracic outlet obstruction with pressure on the trachea, veins and oesophagus. Potential obstruction can be assessed by checking retrosternal resonance on percussion and for neck vein distension on raising the arms above the head (Pemberton sign).

Answer 4

Possible thyroid tests are:

- tests of thyroid function (thyroid hormone levels, thyroid stimulating hormone [TSH] and radionuclide scan)
- anatomy (ultrasound and radionuclide scan) autoimmunity (antibodies)
- blood flow (colour Doppler)
- thoracic outlet (computerised tomography [CT]), and
- histology (fine needle aspiration).

If there was clinical suspicion of thoracic outlet obstruction, a CT would confirm its presence and define its effects. Otherwise the appropriate tests for George are thyroid hormone levels (free T4) the pituitary's response (TSH) and auto-antibodies.

If a goitre was present, some doctors might do a baseline thyroid ultrasound against which to assess future changes in size. However, the management of any goitre associated with hypothyroidism would be thyroxine replacement and any monitoring should focus on the adequacy of this replacement.

Radionuclide scan in hypothyroidism is not useful and can be misleading as normal, decreased or even increased uptake can occur (the increased uptake is driven by high levels of TSH but does not result in increased thyroxine production because of a metabolic defect [abnormal conversion of iodide to iodine]).

Answer 5

There is a cluster of autoimmune endocrine disorders that may occur alone or together in family members (*Table 1*). George has had hyperthyroidism and now has hypothyroidism (Hashimoto disease). His mother might have had premature menopause, a sister might have type 1 diabetes, and other relatives might have other elements of the cluster. The most likely autoimmune endocrine problems for George's family are those related to the thyroid. George may like to let his relatives know that this might be an issue for them, now or in the future.

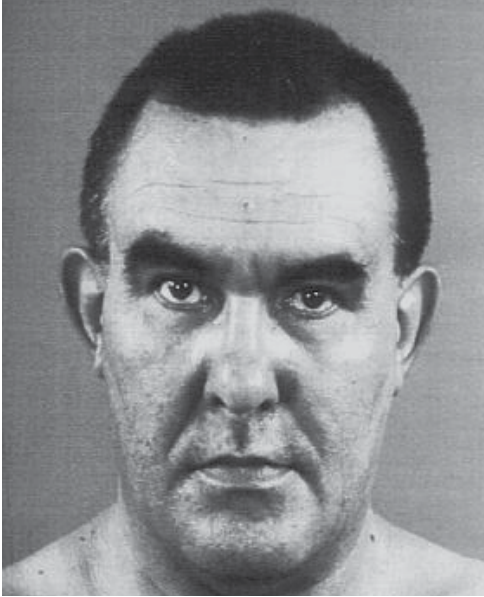
In George's case, checking for appropriate auto-antibodies is indicated:

- gastric parietal cell (to define risk of future atrophic gastritis)
- endomysial and transglutaminase (checking for propensity to coeliac disease), and
- intrinsic factor (which might be associated with pernicious anaemia).

Less commonly one might consider checking for risk of type 1 diabetes (glutamic acid decarboxylase antibodies) and antibodies

Case follow up

Six months later George and Harriet present. George has lost weight, regained his hearing and his energy. His skin is less yellow, his voice less husky and his morning hand symptoms are gone. A recent TSH was 1.7 mu/L (RR 0.3–3 on thyroxine 200 µg/day).



to the adrenal and pituitary. The autoimmune endocrine metabolic cluster may also be associated with other autoimmune conditions such as rheumatoid arthritis.

Thyroxine therapy will increase George's metabolic rate and increase his heart rate and cardiac output. Even before his hypothyroidism George had high blood pressure and his lifestyle is far from ideal. Both predispose him to cardiovascular disease. Moreover his hypothyroidism has been present for some time.

Rapid thyroxine replacement could precipitate a cardiovascular event (myocardial infarct, tachyarrhythmia). 'Starting low and going slow' would be wise: eg. 25 µg/day to start and increase by 25 µg increments every 1–2 months if no problems arise. Remember that the half life of thyroxine is 1 week, so it takes 6–8 weeks to reach a steady state after a change in dose.

Resources

- Thyroid Australia Ltd – www.thyroid.org.au
- Australian Thyroid Foundation – www.thyroidfoundation.com.au.

Conflict of interest: none declared.

Reference

1. Phillips P, Weightman W. Diabetes and the skin. Part 3: diabetic cheiroarthropathy. *Aust Fam Physician* 2005;34:1037–8.