



**Anthony Dixon**

MBBS, FACRRM, is dermatologist and Director of Research, Skin Alert Skin Cancer Clinics and Skincanceronly, Belmont, Victoria. anthony@skincanceronly.com

# Rare skin cancers in general practice

**Case study**

Mr LA has long been troubled with actinic damage to his skin, especially his face. He has had many squamous cell carcinomas (SCCs) removed and many solar keratoses managed.

On this occasion Mr LA had two actinic lesions on his left cheek that failed to respond to cryotherapy (Figure 1). A biopsy of each site produced a surprise. Histology of the superior lesion revealed sebaceous carcinoma (Figure 2). This is an uncommon yet aggressive cutaneous malignancy derived from sebaceous glands. The 5 year survival rate is 60–70%.

The tumour was widely excised with a minimum 10 mm margin. A multidisciplinary approach resulted in a decision not to proceed to adjunctive radiotherapy. The wound was well healed by 8 weeks (Figure 3). Four years on there is no sign of local or regional recurrence (Figure 4).

**Many sebaceous carcinomas occur on the eyelids where the outcome is often poor;<sup>1</sup> and some patients are prone to multiple other cutaneous SCCs.**

There is also a rare syndrome called Muir-torre of visceral neoplasms associated with sebaceous carcinoma on the skin.<sup>2</sup> As this is an autosomal dominant condition, family history and counselling is an essential part of management (enquire about family history of internal malignancies). A family member's diagnosis can be important for other family members and offers screening for internal and cutaneous malignancies.

Mr LA's tumour reminds us that among the basal cell carcinomas (BCCs), SCCs and melanomas removed in large numbers in Australia every day, there are unusual malignancies that we may come across from time-to-time. While we have large studies comparing management options in the more common cutaneous malignancies, it is rarely possible to have large management trials of tumours that none of us see frequently. Treatment is less clear and needs several good minds working together.

The relative severity of some of the rare tumours is tiered and summarised in Table 1. Sarcomas generally have among the poorest outcomes.<sup>3</sup>

**Summary of important points**

- Rare tumours don't get diagnosed clinically. They are invariably diagnosed as a 'surprise' on the histology report.<sup>3</sup>

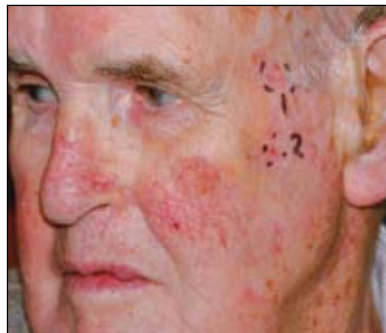

Figure 1. Two actinic lesions on the left face have failed to respond to cryotherapy

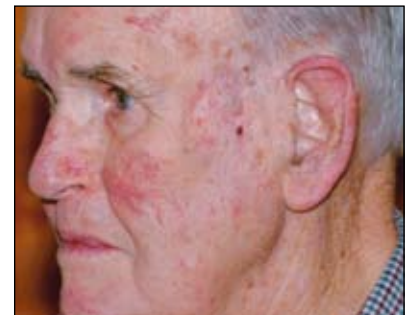

Figure 3. Satisfactory healing 8 weeks following wide excision of sebaceous carcinoma

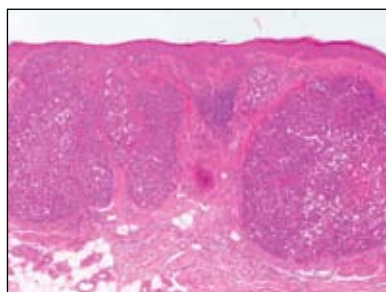


Figure 2. Within the dermis are lobules of epithelial cells showing cytoplasmic vacuolation, mitoses, and nuclear atypia characteristic of sebaceous carcinoma  
Photo courtesy Melbourne Skin Pathology

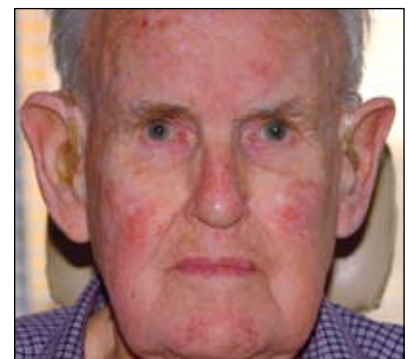

Figure 4. Four years postsurgery there is no regional recurrence

- Consider biopsy of the atypical or recalcitrant actinic keratoses before proceeding to another 'freeze'.
- Send every specimen to the histologist, not the bin. A clinical sebaceous cyst, wart, seborrheic keratosis

**Table 1. Some rare skin malignancies and management considerations (tumours are ordered from the most to least fatal)**

Tumour	5 year survival	Clinical characteristics	Surgery involved	Chemotherapy involved	Radiation involved
Cutaneous angiosarcoma (AS) <sup>5,6</sup>	15%	Mostly on face, scalp, or breast. Local recurrence and metastatic spread frequent, especially to lung. Can occur in postradiation scar	Very wide local excision	Often	Often
Merkel cell carcinoma (MCC) <sup>7-9</sup>	40-68%	Local recurrence common even after very wide surgery. Mostly on head and neck. Spontaneous regression can occur	Mohs or very wide surgery	Occasionally	Often
Sebaceous carcinoma (SC) <sup>1,2,10</sup>	60-70%	Often subcutaneous, often on eyelids or scalp. Can be associated with visceral tumours	Very wide local excision	No	Often
Dermatofibrosarcoma protuberans (DFSP) <sup>9,11-13</sup>	93+%	Local recurrence/destruction in 50-75% of cases; can be fatal. <5% metastasise. Can look like a morphoeic BCC. Often extends well beyond apparent borders. Typically in young/middle aged with predilection for pectoral and pelvic regions	Mohs surgery ideal	Limited	Some
Digital papillary adenocarcinoma <sup>14</sup>	95%	Occurs on the digits. Often looks encapsulated and hence less aggressive than the reality. Metastasises frequently to lungs	Amputate digit	Some	Often
Microcystic adnexal carcinoma (MAC) <sup>5,9</sup>	99%	Behaves like aggressive BCC. High local recurrence risk. 90% are on head and neck	Mohs surgery ideal	Some	Some
Eccrine adenocarcinoma <sup>15,16</sup>	99+%	Behaves like aggressive BCC. Many around eye. Many subtypes. High local recurrence risk	4 mm margin excision	No	No
Atypical fibroxanthoma (AFX) <sup>17-19</sup>	99+%	Low grade sarcoma. Behaves like a BCC. Metastasis very rare. Most occur on elderly, sun damaged head and neck skin. Can occur in old radiation scars	4 mm margin excision	No	No
Kaposi sarcoma (KS) <sup>20,21</sup>	Death from other cause	Three subtypes: • elderly of Jewish/Mediterranean descent • immunosuppressed (eg. postrenal transplant) • HIV/AIDS related	No	Often	Usual

or lipoma can sometimes lead to such a 'surprise'.<sup>4</sup>

- Consult with colleagues and consider involving multidisciplinary experts in management of that surprise unusual tumour. Management predominantly involves surgery but can involve adjunctive radiotherapy or chemotherapy (*Table 1*).
- Unusual tumours are often diagnosed late and many have poor prognoses.

- Sometimes a small biopsy may not provide the answer and complete local excision is required for histologic diagnosis.<sup>3</sup>
- Check whether there are management trials for possible enrolment of your patient with an unusual tumour.

Conflict of interest: none.

**References**

1. de Giorgi V, Massi D, Brunasso G, Mannone F, Soyer HP, Carli P. Sebaceous carcinoma arising from nevus seba-

ceus: a case report. *Dermatol Surg* 2003;29:105-7.  
 2. Nishizawa A, Nakanishi Y, Sasajima Y, Yamazaki N, Yamamoto A. Muir-torre syndrome with intriguing squamous lesions: a case report and review of the literature. *Am J Dermatopathol* 2006;28:56-9.  
 3. Topping A, Wilson GR. Diagnosis and management of uncommon cutaneous cancers. *Am J Clin Dermatol* 2002;3:83-9.  
 4. Dixon AJ, Hall RS. Managing skin cancer: 23 golden rules. *Aust Fam Physician* 2005;34:669-71.  
 5. Awada A, Gil T, Sales F, et al. Prolonged schedule of temozolomide (Temodal) plus liposomal doxorubicin (Caelyx) in advanced solid cancers. *Anticancer Drugs* 2004;15:499-502.

6. Catena F, Santini D, Di Saverio S, et al. Skin angiosarcoma arising in an irradiated breast: case report and literature review. *Dermatol Surg* 2006;32:447–55.
7. Connelly TJ, Cribier B, Brown TJ, Yanguas I. Complete spontaneous regression of Merkel cell carcinoma: a review of the 10 reported cases. *Dermatol Surg* 2000;26:853–6.
8. Suarez C, Rodrigo JP, Ferlito A, Devaney KO, Rinaldo A. Merkel cell carcinoma of the head and neck. *Oral Oncol* 2004;40:773–9.
9. Sei JF, Chaussade V, Zimmermann U, et al. [Mohs' micrographic surgery: history, principles, critical analysis of its efficacy and indications]. *Ann Dermatol Venereol* 2004;131:173–82.
10. Bordea C, Wojnarowska F, Millard PR, Doll H, Welsh K, Morris PJ. Skin cancers in renal transplant recipients occur more frequently than previously recognized in a temperate climate. *Transplantation* 2004;77:574–9.
11. Billings SD, Folpe AL. Cutaneous and subcutaneous fibrohistiocytic tumours of intermediate malignancy: an update. *Am J Dermatopathol* 2004;26:141–55.
12. Snow SN, Gordon EM, Larson PO, Bagheri MM, Bentz ML, Sable DB. Dermatofibrosarcoma protuberans: a report on 29 patients treated by Mohs micrographic surgery with long-term follow up and review of the literature. *Cancer* 2004;101:28–38.
13. Mehrany K, Swanson NA, Heinrich MC, et al. Dermatofibrosarcoma protuberans: a partial response to imatinib therapy. *Dermatol Surg* 2006;32:456–9.
14. Duke WH, Sherrod TT, Lupton GP. Aggressive digital papillary adenocarcinoma (aggressive digital papillary adenoma and adenocarcinoma revisited). *Am J Surg Pathol* 2000;24:775–84.
15. Mehregan AH, Hashimoto K, Rahbari H. Eccrine adenocarcinoma. A clinicopathologic study of 35 cases. *Arch Dermatol* 1983;119:104–14.
16. Durairaj VD, Hink EM, Kahook MY, Hawes MJ, Paniker PU, Esmali B. Mucinous eccrine adenocarcinoma of the periocular region. *Ophthalm Plast Reconstr Surg* 2006;22:30–5.
17. Kram A, Stanczyk J, Woyke S. Atypical fibrous histiocytoma and atypical fibroxanthoma: presentation of two cases. *Pol J Pathol* 2003;54:267–71.
18. Ly H, Selva D, James CL, Huilgol SC. Superficial malignant fibrous histiocytoma presenting as recurrent atypical fibroxanthoma. *Australas J Dermatol* 2004;45:106–9.
19. Seavolt M, McCall M. Atypical fibroxanthoma: review of the literature and summary of 13 patients treated with Mohs micrographic surgery. *Dermatol Surg* 2006;32:435–41; discussion 439–41.
20. Moloney FJ, Comber H, O'Lorcain P, O'Kelly P, Conlon PJ, Murphy GM. A population based study of skin cancer incidence and prevalence in renal transplant recipients. *Br J Dermatol* 2006;154:498–504.
21. Babal P, Pec J. Kaposi's sarcoma: still an enigma. *J Eur Acad Dermatol Venereol* 2003;17:377–80.