



## MRI for cervical radiculopathy

### MBS item description

Referral by a medical practitioner (excluding a specialist or consultant physician) for a scan of spine for a patient 16 years or older for suspected:

- **cervical radiculopathy** (R) (K) (Contrast) (Anaes.)

There is insufficient evidence to suggest imaging for cervical radiculopathy improves outcomes.

Most cases will settle over time without specific treatment.

MRI is suggested for patients who have failed a course of conservative therapy and who may be candidates for interventional or surgical treatment.

### About cervical radiculopathy

Radiculopathy refers to signs and symptoms, not just pain.

Most patients also experience radicular pain, which is sharp and shooting and travels from the neck down the upper limb. In contrast, pain referred from the musculoskeletal structures in the neck is often an aching, and is worse in the neck than the arm.

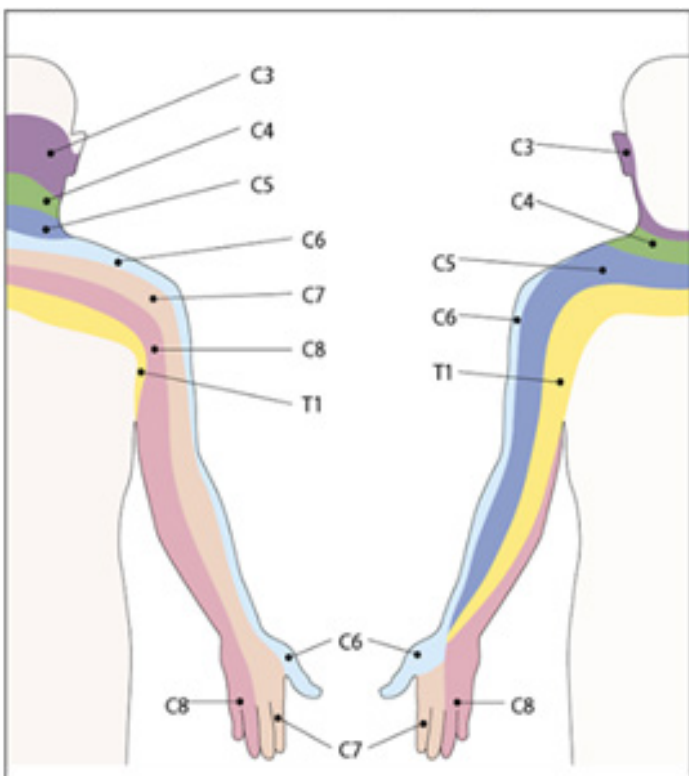


Figure 1. Upper limb dermatomes

### Cervical radiculopathy and MRI

Imaging is not required for the diagnosis of cervical radiculopathy.

Neuroimaging is considered where conservative therapy has failed and surgery is being considered.

In these patients, MRI is preferred. MRI has advantages over CT in that it can demonstrate the nerve root and disc herniation without myelography.

Any cervical imaging commonly detects degenerative changes. These may have little to do with neck pain as 30–40% of asymptomatic young and middle-aged patients have such changes. Abnormal MRI findings also increase with age.

The reliability of MRI readings is highly dependent on careful interpretation in the context of the patient's clinical presentation.

Not all MRI findings correlate well with surgical findings or symptoms.

Figure 1 reproduced with permission from Continuing Medical Education (CME) from Mogere E, Morgado T, Welsh D. An approach to the painful upper limb. Continuing Medical Education 2013;31(3). Available at [www.cmej.org.za/index.php/cmej/rt/prINTERnET/2708/2829](http://www.cmej.org.za/index.php/cmej/rt/prINTERnET/2708/2829)