



# A case of asbestosis?

Peter Trembath, MD, FRACP, FCCP, is a Respiratory Physician Epworth Medical Centre, Richmond, Victoria.

John is a 55 year old carpenter, who recently had a pre-employment chest X-ray. The report reads 'the heart size is normal, the lung fields are clear, there are areas of pleural thickening (Figure 1a, b) in the right and left hemithorax, the latter demonstrates slight calcification. Calcification is noted on the right hemidiaphragm'.

John has no respiratory symptoms such as chest pain, shortness of breath, fevers, sweats or cough, and he has never smoked. John has worked as a carpenter throughout his adult life, and has been particularly involved in bathroom renovations. In the course of his employment he has often been required to demolish areas containing asbestos cement sheet, and on occasion, has used power tools to cut through asbestos cement sheet. The clinical examination is unremarkable, and in particular there is no clubbing of the fingers and the chest is quite clear.

## Question 1

Could these X-ray changes represent asbestosis? If not, what is the likely explanation for the changes?

## Question 2

What is the prognosis of this condition?

## Question 3

Are there any other complications that can occur with this type of occupational exposure?

## Question 4

What other respiratory conditions can occur in carpenters?

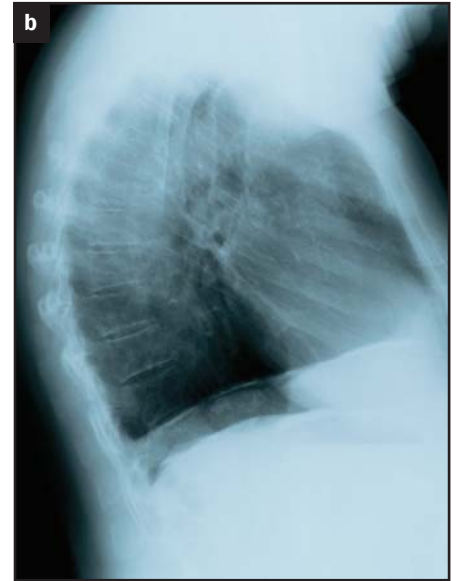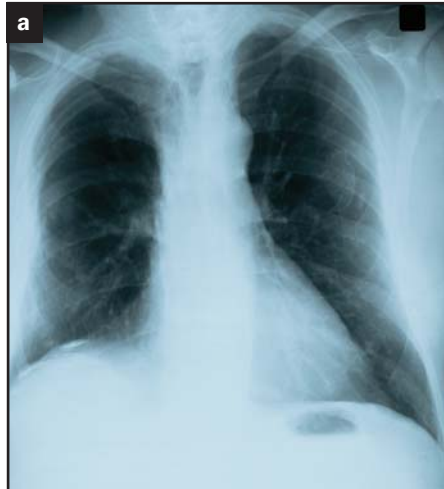


Figure 1a, b. Images supplied by Jonathan Burdon, Mercy Private Hospital, Melbourne

## Answer 1

The term asbestosis is sometimes inappropriately used as a 'shorthand' description. The changes described represent pleural plaques secondary to asbestos exposure. Asbestosis, on the other hand, refers to the pulmonary parenchymal disease where there is fibrosis. This generally implies there is substantial fibrotic change resulting in symptoms. There are associated basal crackles as the condition progresses and a reduction of vital capacity and reduced gas diffusion on lung function testing. Asbestosis is now far less commonly encountered due to improvements in occupational hygiene over the past 30 years.

## Answer 2

Pleural plaques in most cases carry a very favourable prognosis. The risk of mesothelioma in workers exposed to asbestos is no different in workers with similar exposure, who have no pleural plaques compared to those who do. Smoking does not add to the risk of

mesothelioma but does add to the risk of lung cancer.

## Answer 3

Asbestos exposure can also result in benign pleural effusion, mesothelioma and lung cancer.

## Answer 4

Occupational asthma is another factor that needs to be considered in carpenters presenting with cough, particularly at night time. A number of sawdusts can be causative, particularly the exotic timbers such as western red cedar, blackbean, blackwood and mahogany.

Asthma may also occur in carpenters with exposure to glues that may be used in the lamination process of timbers or other surface materials. Composite woods such as chipboard and medium density fibreboard (MDF) may also cause occupational asthma because of the chemicals contained in them especially formaldehyde.

AFP