


Tinnitus

John Tonkin



John Tonkin, AM, MBBS, DLO, FRCS, FRACS, is visiting medical officer, St Vincent's Private Hospital, Sydney, New South Wales.

More can be done than most GPs think

BACKGROUND Tinnitus is the appreciation of sound arising from an internal source. The sound may be pulsating and arising from a vascular cord near the ear or it may arise from pathology in the inner ear. When pathology in the inner ear is the cause of the tinnitus, the tinnitus is nonpulsating, continuous and may have variable frequencies and intensity.

OBJECTIVE This article aims to outline the diagnostic features of tinnitus to determine causes and aggravators, and provide an overview of treatment.

DISCUSSION Assessment of tinnitus involves distinguishing objective from nonobjective tinnitus, pulsatile from nonpulsatile tinnitus and the investigation of features that will determine the cause of tinnitus and any aggravating factors. Management of the condition involves the treatment of the underlying cause, attention to any contributing aggravators and the control of symptoms.

Tinnitus is the hearing of sound (or noise) generated from within the head.

Assessment

The initial assessment of tinnitus, as with most medical conditions involves a thorough history and physical examination. This enables the classification of tinnitus as either objective or nonobjective, and pulsatile or nonpulsatile which is necessary in determining aetiology. It will also assist in identifying the presence of coexisting conditions that could cause or aggravate the tinnitus.

Examination of the ears should include an assessment of the condition of the external canal and the tympanic membrane looking for evidence of past or present infection, actual perforation or healed perforation. Movement of the tympanic membrane with swallowing (with closure of the nose - Toynbee's sign) should be observed. This is an excellent indicator of Eustachian tube dysfunction and noted in conjunction with tympanometry.

Patients with tinnitus also require a professional audiological examination by an audiologist. The assessment of the audiogram plus tympanometry and speech discrimination is not only useful diagnostically but also helps determine management. Further investigations are dependent on the

findings of the initial history and examination.

Objective tinnitus

Tinnitus may be objective in which case an observer (the physician) can also hear the sound, especially with a stethoscope. These sounds are frequently pulsating and may be due to a vascular tumour such as a glomus tumour, or due to an anterior-venous fistula. Careful examination and the use of magnetic resonance imaging (MRI) will reveal the cause and dictate management.

Uncommonly, the objective tinnitus may be a continuous clicking noise which is clearly heard by the physician. It is due to a chronic (spasmodic) contraction of the stapedius muscle or the tensor tympani muscle. It may be associated with a chronic spasmodic contraction of the soft palate.

Nonobjective tinnitus

The more common nonobjective tinnitus is only heard by the patient. It is mainly nonpulsatile. The source of the nonpulsatile tinnitus is called the tinnitus generator. Considerable evidence supports the view that tinnitus aurium may arise from aberrant spontaneous neural activity in the auditory pathways. Abnormally elevated spontaneous discharge rates in single neurons are often observed

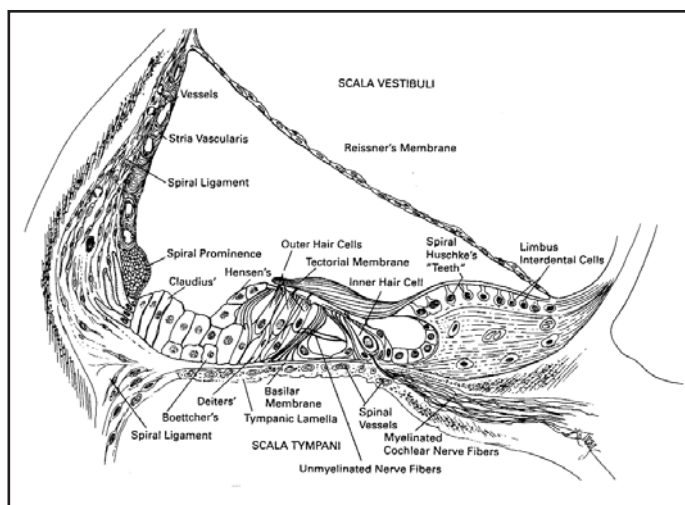


Figure 1. Structures of the cochlear duct³

in cochlear (sensori-neural) noise damage, when damage is confined to the outer hair cells (OHCS) leading to a aberrant discharge levels - possibly from partial decoupling of damaged OHCS from the tectorial membrane.¹

It may be the cochlea itself, the cochlear nerve or the neurones of the dorsal or ventral cochlear nucleus of the brain stem.² Structures of the cochlear duct are shown in Figure 1. The cause of the abnormal signals are called the initiators and may originate from:

- injury
- infection
- tumours
- degeneration
- Meniere's disease.

Causes

Injury

Injury to the temporal bone (concussion or actual fracture) causing damage to the cochlea will frequently result in significant tinnitus. This may be accompanied by sensori-neural hearing loss. The injury may cause an escape of perilymph into the middle ear, either directly through the round window membrane or via a rupture of the oval ligament around the footplate of the stapes. The escape of perilymph may be continuous or intermittent. Hearing loss, with perilymph fistula may be minimal or significant, either conductive or sensori-neural or mixed. The conduction deafness, in perilymph fistula is probably due to the presence of a bubble of air under the footplate of the stapes,

limiting its movement.

The fracture of the temporal bone may be very severe causing a total deafness, even dividing the cochlear nerve. In cases of total deafness, severe tinnitus may be present. It is important to try and demonstrate that the cochlear nerve is functional by using electrical stimulation of the promontory. If the cochlear nerve is functional, the possibility of cochlear implantation may be considered as this technique would most likely result in abolition of the tinnitus when the cochlear implant is 'turned on'. Approximately 85% of cochlear implant cases completely lose their tinnitus.⁴

Tinnitus is very common after exposure to the loud noise of a rock band, lasting 48 hours or so in the majority of listeners. Occasionally exposure to loud noise is a common cause of damage to the cochlea. The sound of pressure (SPL) of 90 decibels or more will, over time, cause permanent damage. Occasionally one night of loud noise will result in permanent damage and significant tinnitus.

Infection

Viral cochleitis is not rare. The various viruses that can invade the cochlear include mumps virus, herpes zoster or herpes simplex, adenoviruses, rubella, and the measles virus. It may result in a silent total hearing loss as in mumps or a variable sensori-neural hearing loss. Tinnitus may be severe or moderate, but is almost invariably absent in mumps deafness invasion.

Invasion of the cochlear in a bacterial otitis media may be via the round window membrane, eg. exotoxins permeating the membrane or via an

actual bacterial infection of the cochlea, that is a true labyrinthitis. A true infective bacterial labyrinthitis almost always results in a very severe and almost total deafness accompanied by severe tinnitus.

Tumours

The most common cause of the unilateral tinnitus caused by a tumour is an acoustic tumour. It is mandatory to perform an MRI on every case of unilateral nonpulsatile tinnitus. Removal of the tumour may not result in abolition or improvement in the tinnitus. If the acoustic tumour is removed with a hearing preservation operation, the tinnitus is likely to continue. Other tumours in the internal auditory meatus eg. facial neuroma or meningioma may also give rise to unilateral tinnitus.

Degenerative diseases

Otosclerosis is a common condition arising in young adults giving rise to deafness and tinnitus. Occasionally tinnitus is the major presenting symptom before deafness is a major problem to the patient. The tinnitus and deafness do not fluctuate and rarely is vertigo a serious accompanying symptom. Stapedectomy, an operation to cure deafness very often abolishes or significantly reduces the tinnitus. However, occasionally a good hearing result is not accompanied by a reduction in the tinnitus. In those cases where a stapedectomy operation is followed by sensori-neural deafness, significant tinnitus is always an accompaniment, frequently more intense than before the operation. Paget's disease of the temporal bone also gives rise to deafness and tinnitus. Attempts to cure the deafness by means of a stapedectomy procedure is far less likely to be successful and therefore does not relieve the tinnitus.

Degeneration of the inner ear from reduction in the blood supply from arteriosclerotic disease of the internal auditory artery may give rise to deafness and tinnitus. Hypertension and diabetes are known precursors of this type of arterial disease.

Meniere's disease

Tinnitus is a major component of the symptoms of Meniere's disease. Other symptoms are episodic vertigo and fluctuant deafness and fullness or blocking sensation in the affected ear. In some patients the most significant symptom is tinnitus.

In fact, in some patients the physician must enquire as to whether the patient has fluctuant deafness and mild episodic (rarely occurring) vertigo. The tinnitus may be significant despite the mildness of other symptoms of Meniere's disease. The tinnitus in Meniere's disease frequently is a low pitched, continuous sound but varies in intensity before an attack of vertigo. The tinnitus frequently increases in intensity and slowly returns to its usual intensity as the attack of vertigo wears off. In the later stages of Meniere's disease the frequency of the tinnitus may be high pitched and unrelenting.

Aggravators

Aggravators are conditions which are not thought to cause tinnitus but contribute to its exacerbation. Aggravators of tinnitus include:

- temporomandibular joint disorder (TMJ)
- malocclusion
- injury
- arthritis
- middle ear disease
 - serous otitis media
 - Eustachian tube dysfunction
 - tympanosclerosis
- allergic rhinitis and sinusitis
- stress
- depression.

Management

Management of tinnitus initially involves the diagnosis and treatment of the underlying cause and aggravating factors. Often however, there is no definitive cause and the aim of management becomes the minimisation and control of symptoms rather than cure. In these cases the management of tinnitus should be holistic. Generally no one approach is sufficient. It is important at this stage to reassure the patient that the tinnitus is nearly always amenable to treatment.

Mineral supplements such as zinc and magnesium are frequently used in the medical treatment of tinnitus. In patients with more severe tinnitus clonazepam 0.5 mg given in the evenings can be helpful.^{5,7}

Additional management of tinnitus by means of a hearing aid in the affected ear is a potent option in treating the condition. Frequently the tinnitus

that sometimes accompanies a moderate deafness will be successfully treated with a hearing aid. Audiological assessment plus tympanometry and speech discrimination will help determine the suitability of the patient for a hearing aid.

Occasionally treatment by a clinical psychologist is necessary in the management of tinnitus. This may involve tinnitus retraining therapy, cognitive behaviour therapy and even hypnosis. Tinnitus retraining therapy aims to effect a reversal of negative thoughts about tinnitus and encourages the central nervous system, by habituation, to alleviate the impact of the tinnitus preferably to the point where it is no longer of significance.

Cognitive behavioural therapy also aims to habituate the central nervous system to the tinnitus, reducing it to insignificance, although this may only be of value in certain rare cases.^{5,7}

References

1. Hughes G, Pensak M. Clinical Otology. New York, Stuttgart: Thieme, 1997; 462.
2. Shulman A. Tinnitus models: a basis for the evaluation of the pathophysiology of tinnitus. In: Shulman A, ed. Tinnitus: Diagnosis and treatment. Philadelphia: Lea & Febiger, 1991; 67-98.
3. Hughes G, Pensak M. Structures of the cochlear duct. Clinical Otology. New York, Stuttgart: Thieme, 1997; 12.
4. Ruckenstein M J, Hedgepeth C, Rafter K O, Montes M L, Bigelow D C. Tinnitus suppression in patients with cochlear implants. Otol Neurotol 200; 22(2):200-204.
5. Goodey R. Drugs in the treatment of tinnitus. In: Ciba Foundation Symposium 85. London: Pitman, 1981; 163-173.
6. Shulman A. Tinnitus models: a basis for the evaluation of the pathophysiology of tinnitus. In: Shulman A, ed. Tinnitus: Diagnosis and treatment. Philadelphia: Lea & Febiger, 1991; 67-98.
7. Shulman A. Medical methods, drug therapy, and tinnitus control strategies. In: Shulman A, ed. Tinnitus: Diagnosis and treatment. Philadelphia: Lea & Febiger, 1991; 453-489.

AFP

REPRINT REQUESTS

John Tonkin
354 Victoria Street
Darlinghurst, NSW 2010
Email: jptonkin@bigpond.com