



Skin and Cushing syndrome



Patrick J Phillips

MBBS, MA(Oxon), FRACP, MRACMA, GradDipHealth Econ(UNE), is Senior Director, Department of Endocrinology, The Queen Elizabeth Hospital, South Australia. phillips@nwhs.sa.gov.au

Warren Weightman

MBBS, FRACP, FACD, is Director of Dermatology, The Queen Elizabeth Hospital, Woodville, South Australia.

'I feel like a traffic light stuck on red. My friends ask me if I'm having hot flushes but this isn't flushes, it's permanent and I'm still having periods.' Carol is describing her facial appearance (*Figure 1*). She is 42 years of age, has had trouble controlling her weight all her life and has gained 10 kg over the past 2–3 years.

On direct questioning Carol explains that the 'flushes' have become progressively worse over the past year or so and that her periods have changed from being 'regular as clockwork' to irregular.

Examination confirms her overweight: 75 kg, height 160 cm, body mass index (BMI) 29.3 kg/m². Carol has had hypertension for 10 years but her blood pressure has increased from 145/85 to 160/95 over the past 2 years.

What underlying endocrine cause should be excluded?

Carol's history is not very specific – facial flushing, irregular periods – but the progressive weight gain and hypertension make it important to exclude Cushing syndrome.

What other skin changes can occur and what causes them?

The skin manifestations of Cushing syndrome (excess cortisol) reflect the excess of glucocorticoids. This causes accumulation of fatty tissue in a characteristic distribution (facial, truncal and cervical) causing the 'moon face', 'lemon on stick' appearance and 'buffalo hump'. Glucocorticoids also increase catabolism of proteinaceous tissues such as collagen, causing skin atrophy fragility with striae and easy bruising (*Table 1*).

In Cushing disease, the excess cortisol is stimulated by pituitary adrenocorticotrophic hormone (ACTH) which also stimulates androgen production. Androgens can cause hirsutism, male pattern alopecia, polycythaemia and flushing and an acneiform eruption. In contrast with acne vulgaris, the pustules are uniform and comedones and cysts are absent.

If ectopic ACTH is driving the pituitary, ACTH levels can be high and can cause excess pigmentation because of the similarity of ACTH to melanocyte stimulating hormone.

If an adrenal tumour is responsible, the full range of adrenal hormones (cortisol, aldosterone, androgens) may be produced in excess, with the mineralocorticoids adding hypertension, cardiac failure and oedema to the clinical picture.



Figure 1. Carol at presentation

Table 1. Skin features of Cushing syndrome

Cortisol	ACTH	Androgens	Mineralocorticoids
Fatty tissue*	Pigmentation ³	Polycythaemia	Oedema*
'Moon face'		Hirsutism*	
'Lemon on matchsticks'		Acne	
'Buffalo hump'			
Protein catabolism			
Atrophy			
Red face ^{1*}			
Striae ^{2*}			
Fragility			
Bruising*			
Poor wound healing			

* In the 'top 10' clinical signs of Cushing syndrome. Others include decreased libido, menstrual change, hypertension, lethargy and/or depression

1. Thin skin + polycythaemia
2. Purple not white or pale pink (stretch marks)
3. Exposed and pressure areas

What are the other clinical signs and symptoms?

Other common clinical features (Table 1) also reflect the excess cortisol, which suppresses the hypothalamic pituitary gonadotrophin axis and causes a reduction in the level of sex hormones, amenorrhoea, and loss of libido. Interestingly, the hormonal profile of Cushing syndrome (excess cortisol) resembles that of

depression, and symptoms of depression are common in patients who have the syndrome.

Other clinical problems associated with the metabolic consequences of excess cortisol include abnormal glucose metabolism leading to prediabetes or diabetes, excess bone breakdown with osteopenia and osteoporosis, and excess protein breakdown with myopathy.

How would you confirm your diagnosis?

Cushing syndrome is categorised by high cortisol levels which do not respond to the normal physiological controls – however a morning cortisol level by itself is not a good screening test. The simplest test is a 24 hour urine free cortisol which provides evidence of excess free cortisol levels. However, two common conditions can also be associated with excess cortisol: obesity and depression.

Carol is overweight but not obese and is annoyed and frustrated rather than depressed. An overnight dexamethasone suppression test would determine if she has normal feedback of the pituitary adrenal axis. Dexamethasone (1 mg taken orally at midnight) should suppress the serum cortisol at 9.00 am the next day to <50 nmol/L in normal individuals. Serum cortisol will fail to suppress if there is autonomous secretion from the pituitary or adrenal tumour. Further investigations would be indicated if dexamethasone did not suppress cortisol levels. (Pseudo-Cushing syndrome associated with excess ethanol is uncommon but can also cause hypercortisolaemia which does not suppress normally. Advice from an endocrinologist might be useful if this is suspected).

If this confirms your diagnosis, what further investigations are indicated?

In principle, the causes of Cushing syndrome are easily separated: pituitary causes, adrenal causes and ectopic production of ACTH

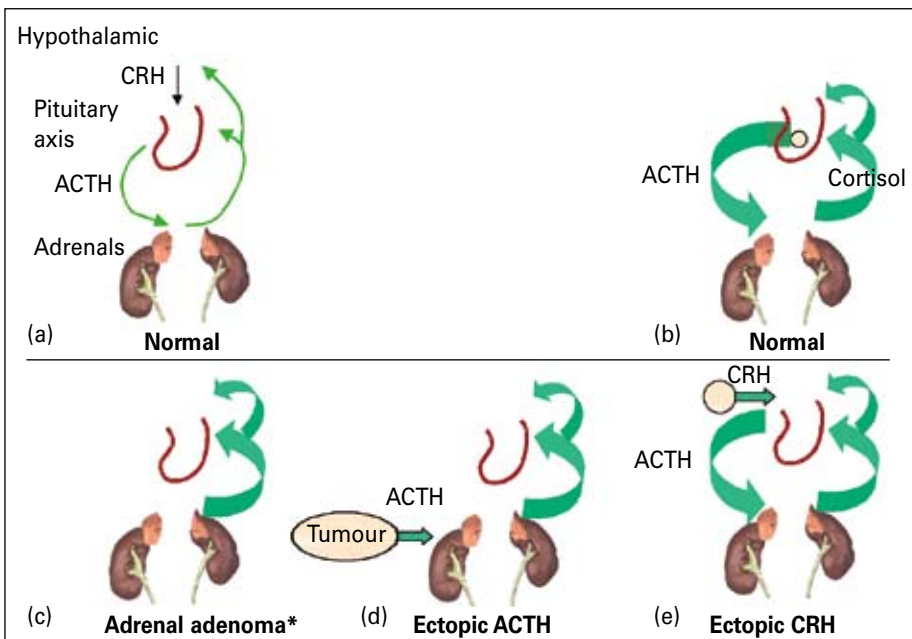


Figure 2. Pathophysiology of Cushing syndrome

- a. Feedback loop with cortisol suppressing CRH and ACTH secretion
- b. Autonomous pituitary ACTH production
- c. Autonomous adrenal cortisol production suppressing CRH and ACTH
- d. Ectopic ACTH production with cortisol suppressing CRH and pituitary ACTH
- e. Ectopic CRH production stimulating pituitary ACTH

* Other adrenal causes include unilateral adenoma or carcinoma and bilateral hyperplasia

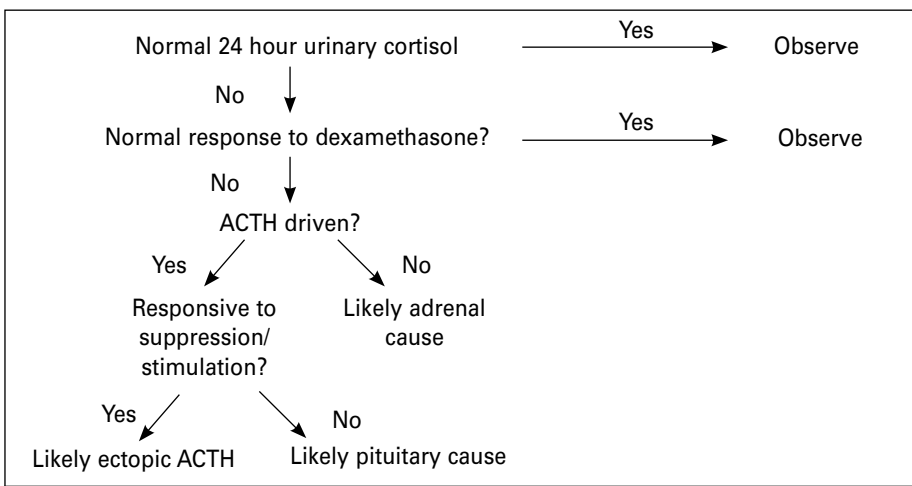


Figure 3. Investigation of Cushing syndrome



Figure 4. Carol 5 years later

(Figure 2). In practice, definitive diagnosis can be difficult.

Having confirmed hypercortisolaemia and/or lack of response to overnight dexamethasone suppression test, the next step is to check if the excess cortisol is driven by ACTH. If not, an adrenal cause is likely and computerised tomography/magnetic resonance imaging (CT/MRI) of the abdomen is indicated.

If ACTH is responsible, the next step is to check if ACTH levels can be suppressed by high doses of dexamethasone or stimulated by corticotropin releasing hormone (CRH). If so, a pituitary cause is likely and a CT/MRI of the pituitary is indicated. If not, an ectopic origin of ACTH is likely and a CT scan of the chest will check if the likely small cell carcinoma of the lung is responsible.

A CRH secreting tumour stimulating the pituitary is rarely responsible. Sampling the right and left inferior petrosal sinuses draining the pituitary might identify the unilateral (adenoma in Cushing disease) or bilateral (possible CRH related) origin of the ACTH.

Postscript

Carol had a pituitary microadenoma which was successfully removed by transnasal hypophysectomy. Five years later Carol 'feels great' (Figure 4).

Conflict of interest: none declared.

Reference

1. Phillips PJ. Is it simple obesity and hypertension, or Cushing's disease? *Medicine Today* 2002;3:83–4.