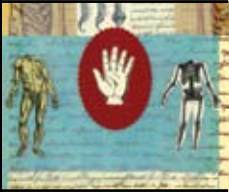

THEME

Musculoskeletal
medicine



Geoff Harding

MBBS, FAFMM, GDipMusMed, is the Australian Academic Coordinator, the University of Otago Postgraduate Diploma in Musculoskeletal Medicine, New Zealand, and a musculoskeletal physician, Sandgate, Queensland.

Michael Yelland

MBBS, PhD, FRACGP, FAFMM, GDipMusMed, is Associate Professor in Primary Health Care, Griffith University, and a general practitioner and musculoskeletal medicine practitioner, Daisy Hill, Queensland. m.yelland@griffith.edu.au

Back, chest and abdominal pain

Is it spinal referred pain?

BACKGROUND

In patients with pain in the back, chest or abdomen, it may be difficult to differentiate nonmusculoskeletal causes from musculoskeletal causes.

OBJECTIVE

This article discusses the mechanisms of musculoskeletal referred pain and the key clinical features that help the practitioner differentiate such pain from nonmusculoskeletal pain, thereby informing appropriate management.

DISCUSSION

Patterns of pain referred from musculoskeletal structures in the back have been well documented from experimentally induced pain. The key features on history that point to spinal referred pain are pain on movement, tenderness and tightness of musculoskeletal structures at a spinal level supplying the painful area, and an absence or paucity of symptoms suggestive of a nonmusculoskeletal cause. Radiological investigations are often of little value in confirming a musculoskeletal cause. A positive response to therapy directed at the musculoskeletal source supports – but does not prove – a diagnosis of musculoskeletal referred pain.

Every general practitioner is familiar with the phenomenon of referred pain – jaw pain combined with left arm pain is almost pathognomonic of cardiac ischaemia. This example of viscerosomatic pain referral is well understood, however the patterns of pain referred from spinal somatic structures (bones, ligaments, joint capsules, tendons, intervertebral discs, muscles) are less well recognised. This article outlines the patterns of spinal referred pain – referred into the chest and abdomen and within the back – and discusses methods for diagnosing and treating such pain.

Mechanisms and patterns of spinal referred pain

The phenomenon of spinal referred pain has been explained by the convergence theory. This theory maintains that afferent nerve fibres from one region converge in the spinal cord with afferent nerve fibres from another region onto a common second order neuron, thereby allowing misinterpretation of the source of pain by the

central nervous system.¹ In a refinement of this theory, called the 'hyperexcitability theory', the referred pain occurs through cross connections between second order neurons supplying the different regions, but only when the input reaches a certain threshold.² The classic papers of Kellgren³ and Feinstein⁴ show common patterns of pain referral following irritation of thoracic and lumbar spinal somatic structures (*Figure 1*). Although these pain referral maps have been available to the medical community for over 50 years they are, we believe, still underutilised in clinical practice. Pain is referred outward and downward from its source, in predictable patterns, as far anteriorly as the anterolateral chest and abdomen. Moreover, the pain is usually felt as deep and dull, or aching, and is diffuse in its distribution. This differs from the sharp and burning pain felt in a well defined dermatomal distribution with irritation of a dorsal root ganglion.

Clinical features

Patients often find it difficult to describe their pain, and so it is the job of the doctor to focus on the description of

the pain in great detail to characterise it. Giamberardino said: 'Only careful study of the clinical history, accurate physical examination and complete sensory evaluation of the painful areas can help toward diagnostic orientation, an indispensable step in the institution of a therapeutic strategy that is not merely symptomatic'.⁵

A prime role of the GP in any consultation is to exclude serious or life threatening conditions as a cause of the presenting complaint. The history, examination and investigations need also to explore the possibility of spinal referred pain as a source. The key features on history, examination and investigation that differentiate nonmusculoskeletal pain from spinal referred pain in the back, chest and abdomen are outlined in *Table 1*. No single feature is diagnostic of either cause.

History

Both nonmusculoskeletal pain and spinal referred pain can be diffuse and aching in nature. Both can cause autonomic symptoms such as sweating, nausea and tachycardia (see *Case study 1, 2*). However, pain of musculoskeletal origin is more likely to be triggered by movement of the affected part. Nonmusculoskeletal pain of visceral origin is more likely to be colicky and unrelated to movement. There may also be associated features of fever, malaise, loss of appetite or urinary symptoms. Nonmusculoskeletal pain of neural origin is typically sharp, burning and felt in a segmental distribution. If due to herpes zoster, a vesicular eruption may ensue.

Examination

Examination for nonmusculoskeletal causes should be directed by the history and performed to a sufficient depth to rule in or rule out pathology in the chest or abdomen.

Finding the exact source of musculoskeletal referred pain, eg. a disc or a facet joint, is not usually possible nor necessary for good outcomes, especially for acute, self limiting pain syndromes. It is more useful for the examination to screen for a disturbance in function or 'dysfunction' of a spinal segment that is consistent with the area of pain. Signs of dysfunction include pain and restriction with global movements and restriction, tightness and tenderness of musculoskeletal structures at a segmental level⁸ (see *Case study 1-3*). An association, but not a causal link, has been shown between thoracic spinal dysfunction and atypical chest/abdominal pain⁹ (see *Case study 2*). If signs of dysfunction are found at a level not consistent with the site of the pain, or are absent, the history should be revisited to consider a nonmusculoskeletal source as primary strains of the abdominal or chest musculature are

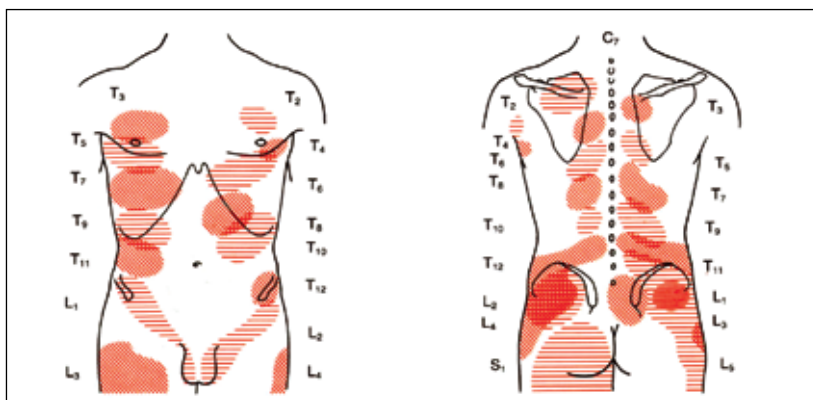


Figure 1. Patterns of referred pain from deep somatic structures of the thoracic and lumbar spinal segments based on experiments by Kellgren et al³ and Feinstein et al⁴ in which spinal and paraspinous structures were injected with hypertonic saline
Source: Dvorak J, Dvorak V. Manual medicine diagnostics. Stuttgart, New York: Georg Thieme Verlag, 1990

Table 1. Features on history, examination and investigation which affect the likelihood of nonmusculoskeletal and musculoskeletal causes of pain in the back, chest and abdomen

Feature	Nonmusculoskeletal pain more likely	Spinal referred pain more likely
Past history of nonmusculoskeletal cause ⁵	Yes	No
Current systemic symptoms (eg. fever, nausea, dyspnoea) ^{5,6}	Yes	Only with severe pain
Symptoms associated with cardiovascular, respiratory, or genitourinary systems or skin	Yes	No
Pain related to active movement ⁷	No	Yes
Deep tenderness in abdomen	Yes	No, although iliopsoas may be tender
Positive musculoskeletal signs consistent with the site of pain ⁷	No	Yes
Rapid response to therapy directed at a musculoskeletal cause ⁸	No	Yes
Radiological tests for spine and ribs ⁹	Negative	May be positive, but question significance of changes

rare. Displacement of a lower rib, called the 'slipping rib syndrome' has been proposed as a cause of abdominal pain and visceral symptoms, but the incidence is unknown.¹¹

The familiar paradigm of 'look, move, feel' provides the basis of the examination of the spine for sources

of musculoskeletal referred pain. However, added information can be gained by modifying the traditional approach to:

- look
- move – active and passive global movements
- feel (palpate) all tissues – segmentally, and
- compare both sides.

Details of spinal examination tests and their interpretation are shown in *Table 2*. The use of passive movements, with overpressure toward the end of range, can elicit pain when active movements do not. Segmental palpation is an important tool of the examination process because it locates tenderness (*Figure 2*). Eliciting tenderness in the relevant tissues both aids the diagnostic process and importantly, affirms the patient's symptoms. This can be a powerful part of the dynamic between patient and doctor in the discipline of musculoskeletal medicine. It increases

the patient's confidence in the doctor's ability to examine, and increases the doctor's confidence in his/her ability to locate the pain generator. Note that paraspinal tenderness is commonly found slightly above the site of the pain (pain refers outward and downward from the thoracic and lumbar spines).³ This is because the dorsal rami of spinal nerves come to the skin surface about three vertebral levels below their exit from the spine.

Comparison of the other side is important – the term 'lateralising' is used when symptoms or signs show a preference for one side or the other. Thus, lateralising is an important sign in musculoskeletal medicine, as it suggests a nonsystemic (noncentral) process as the cause of the pain. Incidentally, it is important to visualise what tissues are being palpated (*Figure 3*). Tenderness with light palpation might imply skin tenderness, whereas muscle tenderness

Case study 1

History: A woman, 78 years of age, presented with a 2 year history of recurrent upper chest tightness and discomfort, predominantly right sided. With each episode, she had dyspnoea, tachycardia, fatigue and feelings of doom about having a heart attack. She often presented to hospital emergency departments with these symptoms where ECGs, cardiac enzymes and chest X-rays were always normal. Coronary artery disease had been further excluded with stress tests, echocardiography and coronary angiography. Further history revealed no clear precipitants for these episodes. Her chest tightness and discomfort were not related to exertion, deep breathing or to neck and upper back movements.

Examination: Testing of all cervical and thoracic spinal movements, even with overpressure, did not cause pain. However she did have tenderness over the T3-5 spines, in the tight paraspinal muscles to the right of these spines and over the right third and fourth sternocostal junctions. Her cervical spine was not tight or tender.

Assessment and treatment: Her symptoms were diagnosed as being referred from T3-5 intervertebral dysfunction and a 'diagnostic' manipulation of these levels was performed giving rapid relief of her chest symptoms. This was followed with four further manipulations in the following month. Subsequent recurrences of her symptoms were considerably less frequent and severe over the ensuing 6 months. She was greatly reassured by her response to treatment.

Comment: This case illustrates how chest tightness and discomfort may arise from dysfunction of the upper thoracic spine and associated ribs. This part of the spine is usually quite stiff and not affected by movement. Tenderness of the T3-5 spinous processes is common, however unilateral tenderness at these levels on the side of her symptoms, and the exclusion of cardiac and respiratory causes, supports a diagnosis of spinal referred pain.

Case study 2

History: A man, 55 years of age, presented with a 6 month history of episodic vague upper abdominal pain and nausea. His episodes occurred almost daily for several hours and were not related to meals. During this period his appetite had decreased and he had lost 3 kg. He liked his beer, drinking 12 cans per day on weekends and four cans per day on weekdays. He was a nonsmoker. He had a past history of low back pain and occasional panic attacks.

As part of an assessment by a general surgeon, he had undergone an upper gastrointestinal endoscopy, upper abdominal ultrasound and abdominal CT scan, all of which were normal. Trials of omeprazole and domperidone had made no difference to his symptoms. A full blood count, ESR and liver function tests were all normal. Further history revealed that he had had frequent, low grade interscapular pain for the past 9 months. This pain was aggravated by twisting of his upper body when backing out his car.

Examination: Abdominal examination was normal. His interscapular pain was reproduced on examination by rotation, side bending and extension of his thoracic spine. He was tender over the T6-8 spines and the adjacent paraspinal muscles. X-rays of his thoracic spine were normal.

Assessment and treatment: This clinical picture was consistent with referred pain and associated nausea arising from mid thoracic spinal dysfunction. A trial of mid thoracic manipulation gave rapid relief of his symptoms, so was followed by further manipulation weekly for 3 weeks. His symptoms were then controlled for 3 months. Occasional relapses in the ensuing year were also treated with manipulation.

Comment: A diagnosis of spinal referred pain was based on four features: the poor relationship between food and his symptoms; the negative abdominal and thoracic spinal investigations; the presence of spinal pain and tenderness at a spinal level which innervates the upper abdomen; and the good response to manipulation. Reliance on only one or two of these features increases the risk of missing pathological causes in the abdomen and spine.

Table 2. Spinal examination tests useful for the detecting signs of pain referred from the spine⁷

Test	Look for	Comment
Inspection from: <ul style="list-style-type: none"> • front • behind • side 	Altered posture, scoliosis, muscle spasm, bony prominences	Major postural abnormalities likely to indicate pain avoidance
Gross active movements	Decreased range, pain provocation, site of pain produced, compare sides	Usually (but not always) gross active ranges will be restricted to some extent
Gross passive movements	Pain reproduction at end range, question altered 'end range feel', ie. not the usual 'springiness'	Applying overpressure at end range increases sensitivity of detecting end range pain if active movements normal
Segmental palpation		
Skin	Abnormal areas of dry or moist skin, altered texture (peau d'orange) Abnormal tenderness	Tenderness common in referred pain zones Autonomic signs common in referred pain states
Muscles <ul style="list-style-type: none"> • tone • trigger points 	Spasm in body of the muscles, general tenderness Trigger points – areas of taut, tender bands in localised areas of a muscle	Muscles supplied by affected spinal segment often show signs of dysfunction
Bones and joints <ul style="list-style-type: none"> • spinous processes • facet joints • costo-transverse joints in thoracic spine 	Tenderness, decreased mobility (hypomobility) Using light, moderate and heavy pressure helps determine 'irritability'	Dysfunctional intervertebral joints will generally have signs elicited by palpation

usually comes into play before visceral tenderness. The case studies illustrate the value of a detailed examination.

Investigations

A lack of understanding of musculoskeletal referred pain can entice us to resort to the use of precision investigations such as computerised tomography (CT) or magnetic resonance imaging (MRI) in an effort to find the precise structure involved. Understanding the many mechanisms of pain will give us the confidence to avoid these investigations in the first instance and save their use for those presentations which do not resolve within a reasonable time.

Investigations are often important in the assessment of nonmusculoskeletal causes of pain, eg. the use of resting and stress electrocardiogram (ECG) for chest pain and endoscopy for abdominal pain. Radiological investigations and blood tests are useful for ruling out 'red flag' conditions in the spine such as fractures, tumours and infections (see *Case study 1, 2*). Fortunately these are rare (approximately 1% of cases).⁶ Radiological investigations are less useful in the assessment of spinal sources of pain particularly with respect to disc protrusions and degenerative changes, as the high prevalence of these changes in pain free individuals limits the specificity of

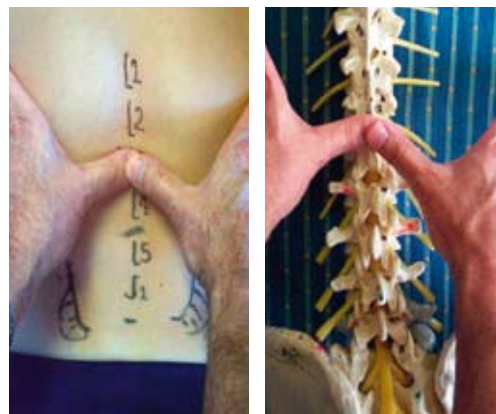


Figure 2. Segmental palpation of the lumbar spine commencing with central palpation of the spinous processes

these investigations.^{12,13} They add little to the physical examination in showing segmental dysfunction. The most accurate investigations for spinal referred pain are local anaesthetic blocks of facet joints¹⁴ but their role is limited to difficult chronic pain problems.

Treatment

Having made a diagnosis of musculoskeletal referred pain, treatment begins with four elements: explanation, reassurance, activation and analgesia.

Explanation

A positive diagnosis of musculoskeletal referred pain needs to be discussed with the patient. The pain is referred from an area of 'dysfunction' or 'disturbed function' in the spine; these terms are not well understood so the term 'strain' may be preferable. The concept of referred pain is difficult to explain, so the use of an analogy is helpful. Referred pain is likened to 'crossed telephone lines' within the spinal cord

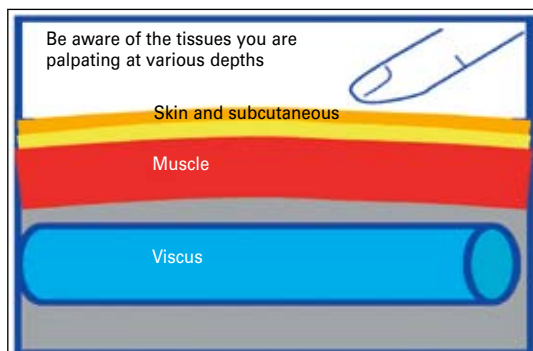


Figure 3. Palpation of the body layers

Case study 3

History: A 74 year old male retiree who participates in veteran athletics (javelin and sprinting) presents with a history of right groin pain which often radiates into the right testicle. It has been present for the past 2 months. There is no known injury but he has been training more frequently for international championships. He is otherwise well and has seen his GP who felt that he might have a small inguinal hernia, although the surgeon disagrees. He admits to some right loin pain (although he is not sure if this pain is related to the groin pain).

The pain is intermittent, lasts about 1 hour and at times is deep, aching and ill defined. His pain diagram shows the back pain as being in the right loin area. The pain is worse with movement (especially bending and twisting) and better with lying down. There are no urinary symptoms or fever.

Examination: Restriction of active lumbar forward flexion and active left side bending – this increases both his loin and groin pain. Hyperalgaesia to pinch rolling of the skin in the right loin in a narrow band and similar hyperalgaesia in the right groin. Palpable, tender trigger points in the right erector spinae muscles at about the L2 level, tenderness to palpation of the intervertebral joints at the thoracolumbar junction generally.

Assessment: This pattern of pain is consistent with somatic pain referred from the thoracolumbar junction. The absence of 'systemic' symptoms and signs makes a 'visceral' source less likely. Findings of restricted range of movement and tenderness in the spine make the diagnosis of spinal referred pain from the thoracolumbar junction more likely. The absolute source of the pain is not important at this stage. A trial of therapy will usually confirm or not, the diagnosis of spinal referred pain.

Treatment: Mobilisation was applied to the thoracolumbar junction. This was followed on the same visit by a manipulation. The patient experienced an immediate increase in left side bending – which was now painless. He later reported relief of the groin pain. He had recurrence 3 months later, which was treated in the same manner with the same effect. Home exercises were given with the aim of mobilising the joints at the thoracolumbar junction.

between the nerves coming from the painful structures and the nerves at the same level supplying any other structures. Therefore the brain becomes unsure where the pain is coming from and interprets the pain as coming from the other structures. Patients often want to know the exact structure that is causing the pain, however it is usually not possible – nor is it essential – to label an exact structure to guide treatment.

Reassurance

Reassure the patient that the condition is not 'serious', ie. not life threatening or requiring surgery and that it has a good outcome in most patients. It is also reassuring to tell patients they can return for review within a week or so if the pain is not settling or if they are still concerned.

Activation

This is the concept that remaining active, or restoring normal physical activity, is beneficial for recovery.¹⁵ Explain to patients that they should continue to perform as many of their activities of daily living as possible and try to 'work through' the pain. (Remember that we are talking about the non-'red flag' conditions here).

Analgesia

It is important to relieve pain enough to enable activation. Start with paracetamol and increase to combination analgesics as necessary. Stress the importance of taking medications on a time contingent basis rather than ad hoc. Nonsteroidal anti-inflammatories might be given a trial – but if not providing benefit after several days, cease them.

Other treatments

More specific treatment of the origin of the pain may then include manual therapy, including mobilisation (gentle rhythmic movement) and manipulation (high velocity, low amplitude thrust – which often produces a 'crack'), or injection therapy applied to the affected segment can be very effective in reducing movement restriction – and pain.¹⁶ These simple treatments were used in all three case studies to good effect.

Training and referral

Many GPs throughout Australia have attended musculoskeletal workshops and their feedback evaluations report consistently high ratings when asked if they have found the acquired skills to be useful tools in their armamentarium for treating musculoskeletal conditions.¹⁷ The Australian Association of Musculoskeletal Medicine runs these workshops for GPs from time-to-time. Otherwise, the next best thing is an informed referral, to a GP colleague

skilled in manual therapy, a physiotherapist, osteopath or chiropractor, asking them to perform manual therapy directed at the affected segmental level. It is helpful to be familiar with the approach used by the manual therapist.

Conflict of interest: none declared.

References

1. Bogduk N. Mechanisms of musculoskeletal pain. *Australasian Musculoskeletal Medicine* 2006;11:6–18.
2. Arendt-Nielsen L, Svensson P. Referred muscle pain: basic and clinical findings. *Clin J Pain* 2001;17:11–9.
3. Kellgren JH. On the distribution of pain arising from deep somatic structures with charts of segmental pain areas. *Clin Sci* 1939;4:35–46.
4. Feinstein B, Langton JNK, Jameson RM, Schiller F. Experiments of pain referred from deep somatic tissues. *J Bone Joint Surg Am* 1954;36-A:981–97.
5. Giamberardino M. Muscle pain, referred pain. In: *Encyclopaedia of pain*. Berlin Heidelberg New York: Springer-Verlag, 2007;1222–6.
6. Deyo RA, Diehl AK. Cancer as a cause of back pain: frequency, clinical presentation, and diagnostic strategies. *J Gen Intern Med* 1988;3:230–8.
7. Deyo RA, Rainville J, Kent DL. What can history and physical examination tell us about low back pain? *JAMA* 1992;268:760–5.
8. Kenna C, Murtagh J. Patterns of spinal pain. In: *Back pain and spinal manipulation*. 1st edn. Sydney: Butterworths, 1989;1–10.
9. Yelland MJ. Back, chest and abdominal pain. How good are spinal signs at identifying musculoskeletal causes of back, chest or abdominal pain? *Aust Fam Physician* 2001;30:908–12.
10. Yelland M. Diagnostic imaging for back pain. *Aust Fam Physician* 2004;33:415–9.
11. Abbou S, Herman J. Slipping rib syndrome. *Postgrad Med* 1989;86:75–8.
12. Magora A, Schwartz A. Relation between the low back pain syndrome and x-ray findings. I. Degenerative findings. *Scand J Rehab Med* 1976;8:115–26.
13. Wiesel SW, Tsourmas N, Feffer HL, Citrin CM, Patronas N. A study of computer assisted tomography. I. The incidence of positive CAT scans in an asymptomatic group of patients. *Spine* 1984;9:549–51.
14. Schwarzer AC, Wang SC, Bogduk N, McNaught PJ, Laurent R. Prevalence and clinical features of lumbar zygapophysial joint pain: a study in an Australian population with chronic low back pain. *Ann Rheum Dis* 1995;54:100–6.
15. Harding GA. Activation/reassurance. In: *Scmidt RF, Willis WD, editors. Encyclopaedia of pain*. New York: Springer, 2007;9–10.
16. McGuirk B, King W, Govind J, Lowry J, Bogduk N. Safety, efficacy, and cost effectiveness of evidence-based guidelines for the management of acute low back pain in primary care. *Spine* 2001;26:2615–22.
17. Harding GA. Evaluation report. Musculoskeletal health workshop. In: *Sunshine Coast: Health Workforce Qld*, October, 2006.