



Christopher Hoe-Kong Chui
MBBS, MRCSed, MMed(Surg),
is Medical Officer (trainee),
Department of Hand Surgery,
Singapore General Hospital,
Singapore. chkchui@gmail.com

Jonathan Yi-Liang Lee
MBBCh, BAO, MRCSed,
MMed(Surg), FAMS, is
Associate Consultant,
Department of Hand Surgery,
Singapore General Hospital,
Singapore.

Diagnostic dilemmas in unusual presentations of gout

BACKGROUND

Gout is known to mimic conditions as diverse as joint and soft tissue infections, skin malignancies, nerve compression syndromes and soft tissue tumours. Upper limb involvement is unusual.

OBJECTIVE

We discuss four cases of gout in the hand and wrist masquerading as a soft tissue tumour, nodular extensor tenosynovitis, septic arthritis of the wrist and acute and chronic median nerve compression. These cases illustrate that gout in the hand and wrist can resemble more sinister conditions, often posing a diagnostic challenge even to the experienced clinician.

DISCUSSION

In the management of hand and wrist pain, swelling and neuropathy, emphasis must be placed on actively excluding limb and life threatening conditions such as septic arthritis and neoplasia. Laboratory and radiological investigations cannot accurately distinguish these pathologies from gout. Invasive surgical exploration or tissue sampling is often needed to establish the correct diagnosis.

Gout has been known as a 'great mimicker' since ancient Greek times when Hippocrates attempted to differentiate it from rheumatoid arthritis.¹ It has been reported to mimic joint² and soft tissue infections,³ skin malignancies,⁴ nerve compression syndromes⁵⁻⁶ and soft tissue tumours.⁷

Discussion

Gout is caused by hyperuricaemia and subsequent precipitation and deposition of monosodium urate crystals.⁸ In the hand and wrist it can present as pain, swelling or neuropathy and can pose a diagnostic challenge. Gout is confirmed by identification of urate crystals in joint fluid or tophi. A clinical diagnosis can be made if certain criteria are met⁹ (Table 1).

Gout classically causes acute, episodic monoarticular arthritis of the first metatarsophalangeal joint (podagra). Upper limb involvement is more unusual but has been described, especially when there is extensive involvement elsewhere in the body or a long history of gout.¹⁰ A high index of suspicion and familiarity with the various presentations of gout are needed if it is to be accurately diagnosed clinically.

Gouty arthritis is characterised by agonising pain, swelling, erythema, warmth and tenderness of the affected joint. Differentiation from rheumatoid arthritis, osteoarthritis, septic arthritis or pseudogout is difficult. It

is essential to exclude septic arthritis early as destruction of articular cartilage occurs within days of onset.^{11,12} Readily available laboratory investigations are unable to distinguish a septic joint from inflammatory arthritis.^{12,13} Serum inflammatory markers, erythrocyte sedimentation rate (ESR) and C-reactive protein, are variably raised in both but lack adequate specificity to be diagnostic.^{12,13}

Table 1. American Rheumatism Association criteria for the diagnosis of gout⁹

- Urate crystals in either joint fluid or a tophus, and/or
- Six of the following 12 criteria:
 - maximum inflammation within the first day
 - more than one attack of acute arthritis
 - monoarticular arthritis
 - redness observed over joints
 - first metatarsal joint pain attack
 - unilateral metatarsal joint attack
 - unilateral tarsal joint attack
 - suspected tophus
 - hyperuricaemia
 - asymmetric swelling within a joint on X-ray
 - subcortical cysts with no erosions on X-ray
 - negative bacterial culture of joint fluid

Case study 1

Acute monoarthritis with acute carpal tunnel syndrome

A cleaner, 45 years of age, presented with 2 days of left dorsal hand and wrist pain, swelling and erythema. He had a history of diabetes mellitus (DM), hypertension, hepatitis C, and renal transplant 15 years prior for which he was receiving immunosuppressive therapy, but no history of gout. His temperature was 37.4°C. The left wrist (*Figure 1a*) was diffusely swollen and warm, movement was limited by severe pain. Numbness was reported over the left palm.

Serum uric acid was mildly elevated at 500 µmol/L. Full blood examination (FBE) showed a raised total WCC of 14.78 with left shift. Erythrocyte sedimentation rate was raised at 96 mm/hr. Plain X-ray (*Figure 1b*) showed erosion of the dorsal surface of the lunate.

Septic arthritis with acute carpal tunnel syndrome was suspected. Intravenous antibiotics were started before surgery. At surgery, acute synovitis in the wrist joint and extensor compartments were found, but there was no purulent material. Chalky deposits were found within all the intercarpal ligaments, radiocarpal and midcarpal joints. Erosion of the capitate and lunate were also present. The carpal tunnel was released and the joint washed. Microbiological cultures were negative. Histology was consistent with gout.

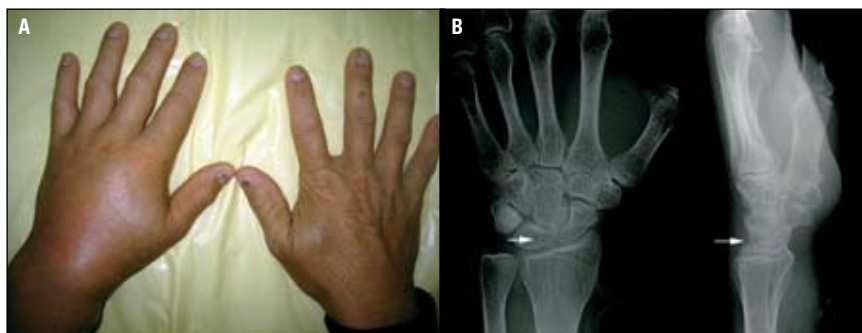

Figure 1a. Both hands showing diffuse swelling and erythema of the dorsum of the left hand and wrist
Figure 1b. Plain X-ray of left wrist demonstrating erosion of the posterior surface of the lunate (white arrows)

The white cell count (WCC) is elevated in less than 50% of patients with septic arthritis in the hand or wrist.¹¹ Butbul-Aviel et al¹⁴ found only mild elevation of procalcitonin in 27.2% of children with septic arthritis and concluded it was not a useful investigation in this setting.¹⁴ The serum uric acid (UA) is often normal even in an acute attack of gouty arthritis and is not diagnostic. Clinical signs are also not reliable indicators of the presence or absence of sepsis. Almost half of patients with septic arthritis will not present with fever¹² and 33.3% of patients with concomitant septic and gouty arthritis will be afebrile.¹⁵ Although there is no evidence regarding range of motion to identify a septic joint,¹² the finding of severely restricted active movement may help to distinguish from inflammatory arthritis. Early identification and treatment of septic arthritis is essential for a good outcome. The constellation of clinical and laboratory findings must be interpreted together to reach a diagnosis. Surgical exploration or joint aspiration is advocated if the diagnosis is in doubt.

Tophi develop an average of 12 years after the initial attack of gout¹⁶ and present as soft tissue lumps, ulcerative skin lesions, nerve compression and/or joint destruction leading to functional and cosmetic deformity.

Case study 2

Carpal tunnel syndrome secondary to tophaceous gout

A man, 55 years of age, with a 5 year history of gout and hypertension complained of numbness in his right hand for 1 year. This was associated with right wrist swelling. Wrist circumference was 18.5 cm compared to 17 cm on the left side. Tinel and Phalen signs were positive. Plain X-ray showed erosion in the distal radius (*Figure 2a*). Nerve conduction studies confirmed the diagnosis of carpal tunnel syndrome.

At operation, a large tophaceous mass arising from the volar aspect of the radiocarpal joint extending into the scapholunate, lunotriquetral and midcarpal articulations was found compressing the median nerve in the carpal tunnel (*Figure 2b*). Erosion into the distal radius and scaphoid waist was found. The tophus (*Figure 2c*) was excised and transverse carpal ligament released. Histology was consistent with gouty tophus. Postoperative recovery was uneventful, however numbness in the tip of the middle finger was still present 10 months later.

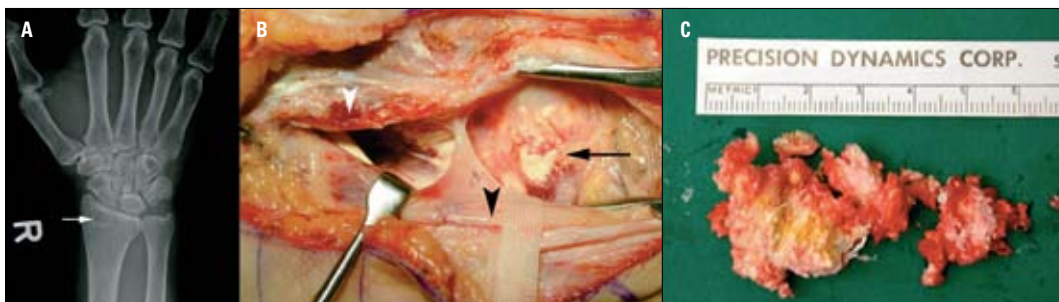


Figure 2a. X-ray of right wrist demonstrating erosion into the distal radius (white arrow)
Figure 2b. Photo showing divided transverse carpal ligament (white arrowhead), the median nerve (black arrowhead) and a tophaceous deposit (black arrow) compressing the median nerve
Figure 2c. Excised tophaceous deposit

Case study 3 Hand tumour

A man, 22 years of age, was noted to have a 3 cm lump at the neck of the left little finger metacarpus (*Figure 3a*) slowly increasing in size over 1 year. He reported mild pain when gripping objects and it was mildly tender to palpation. Questioning revealed a history of recurrent attacks of bilateral ankle pain 6 monthly for the past 3–4 years. He had never been prescribed hypouricaemic therapy, but had used colchicine to treat acute episodes. Plain X-ray of the left hand was unremarkable. Magnetic resonance imaging (MRI) showed acute synovitis involving the left fifth metacarpophalangeal (MCP) joint with marked proliferative synovitis and surrounding oedema (*Figure 3b–d*). The hypervascular and infiltrative nature of the lesion could not be distinguished from a malignant lesion.

A yellowish chalky-white lesion measuring 3x2.5 cm encircling the metacarpal neck (*Figure 3e*) was excised. Histology was consistent with gout. Serum UA was found to be high at 674 $\mu\text{mol/L}$ and the patient was prescribed allopurinol.

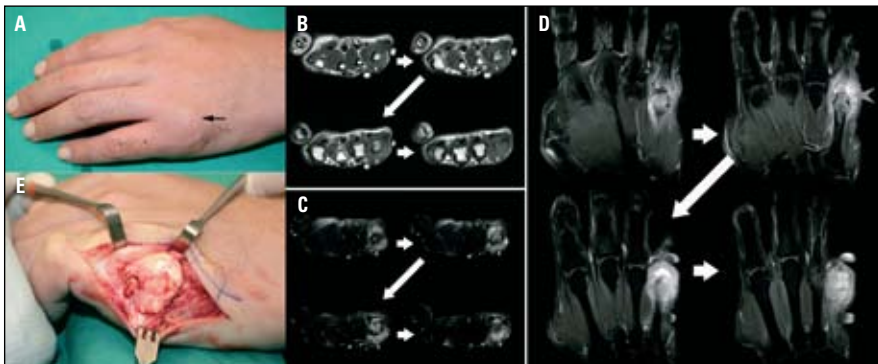


Figure 3a. Photo of left hand of Case 3 showing a lump at the neck of the metacarpus of the little finger (black arrow)

Figure 3b. T1W MRI of left hand without contrast showing a lesion encircling the fifth metacarpus with homogeneous intense signal intensity (white arrowhead)

Figure 3c. Fat suppressed T2W MRI of same lesion (white arrowhead) without contrast showing heterogeneous signal intensity within the lesion

Figure 3d. Coronal, contrast enhanced, fat suppressed T1W MRI of left hand showing contrast enhancement of the lesion and possible bony infiltration (grey arrowhead)

Figure 3e. Tophaceous deposit encircling the neck of left little finger metacarpus

Differentiation of tophaceous gout from malignancy can be difficult. Both can present with a mass with or without pain, night pain, or neurologic compromise from nerve involvement or compression. Plain radiographs are usually not helpful in making a diagnosis. Classic radiologic findings of gout, such as para-articular erosions,¹⁷ cannot be distinguished from tumour infiltration with certainty. Calcification can be seen in both gouty tophi and malignant tumours.¹⁸ Magnetic resonance imaging features of malignant soft tissue tumours include:

- size >3 cm
- ill defined/irregular margins
- infiltration of adjacent muscle or bone, and
- a homogenous signal intensity on T1 weighted (W) images with heterogeneity on T2W images.

The MRI appearance of tophaceous gout and

malignancy can be similar. Tophi have a low to intermediate homogeneous signal intensity on T1W images but show variable heterogeneous signal intensity on T2W images^{25,26} due to its varied composition of crystals, hemosiderin, protein and fibrous tissue.¹⁹ Tophi do not have a well defined margin, can erode adjacent bone and infiltrate soft tissue such as muscle, tendons (see *Case 4*) and nerves. As demonstrated in *Case 3*, a neoplastic process cannot be safely excluded using MRI, however MRI is a useful adjunct to surgical planning in assessing the precise location and extent of the lesion. Biopsy can confirm the diagnosis.

Functional deficits caused by gout include decreased joint movement and neurovascular compression. *Case 1* and *2* illustrate different presentations of compressive neuropathy secondary to gout. Gouty involvement of the flexor tendons or sheaths within the carpal tunnel, carpal tunnel floor, transverse carpal ligament, or median nerve itself have been reported in the medical literature as a cause of carpal tunnel syndrome.²⁰ Surgical decompression is advocated.⁶

Gout in the hand and wrist can mimic more sinister conditions. It is vital to exclude these before making a diagnosis of gout. Surgery is required in certain circumstances for histological diagnosis or decompression but may be complicated by poor wound healing,

Case study 4 Nodular tenosynovitis

A taxi driver, 58 years of age, with previous traumatic right index and middle finger amputations presented with painful lumps on the right middle finger stump and dorsal surface of the MCP joints of the middle and index fingers (*Figure 4*). He had a history of gout, hypertension and hyperlipidaemia. Examination revealed a 1 cm tophus at the right middle finger stump and tophi within the extensor tendons on the dorsal surface of the middle finger and index finger MCP joints. Joint movement was not restricted.

At surgery, gouty tophi infiltrating the extensor digitorum communis tendons of the index and middle fingers were excised while preserving the tendons. Histology was consistent with gouty tophi. Wounds healed without delay and movement of the digits were unaffected.

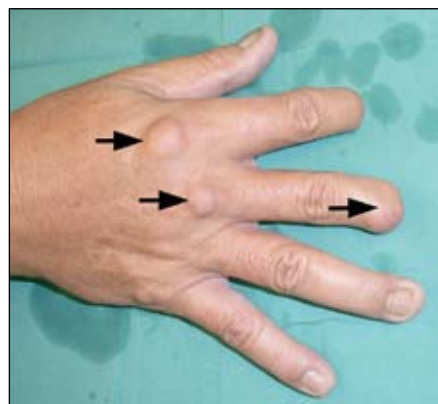

Figure 4. Right hand of Case 4 showing tophaceous deposits in the extensor digitorum communis tendons of the index and middle fingers as well as the stump of the middle finger

wound infection and anaesthetic complications, especially in patients with gout who often have associated hypertension, renal insufficiency, cardiovascular disease, DM or obesity.²⁰ Minimally invasive investigations such as joint aspiration or fine needle aspiration cytology avoid surgical morbidity, and may confirm the diagnosis of gout,⁸ as well as excluding infection. However, aspiration of the small joints of the hand and wrist can be difficult to perform and sampling error can give false negative results. Surgical exploration not only confirms the diagnosis of gout but more importantly definitively excludes sinister differentials and should be considered early to establish the correct diagnosis.

Summary of important points

- Gout can be a benign mimicker of sinister conditions.
- Monoarthritis should be regarded as infectious until proven otherwise. Serum inflammatory markers cannot reliably identify a septic joint.
- Analysis of joint fluid and soft tissue swellings for uric acid crystals may verify the diagnosis of gout and at the same time exclude infective processes.
- Tophi can have a 'malignant' MRI appearance and biopsy may be required for definitive diagnosis.
- Tophi can cause compressive neuropathy, surgical decompression is desirable.

Conflict of interest: none declared.

Acknowledgment

Thanks to A/Prof Agnes Tan, A/Prof Teoh Lam Chuan, Dr Yong Fok Chuan and Dr Andrew Yam of the Department of Hand Surgery, Singapore General Hospital for contributing cases for this article.

References

1. Copeman WSC. A short history of gout. Berkeley, CA: University of California Press, 1964.
2. Sack K. Monoarthritis: differential diagnosis. *Am J Med* 1997;102:30S-4.
3. Louis DS, Jebson PJ. Mimickers of hand infections. *Hand Clin* 1998;14:519-29.
4. Dacko A, Hardick K, McCormack P, Szaniawski W, Davis I. Gouty tophi: a squamous cell carcinoma mimicker? *Dermatol Surg* 2002;28:636-8.
5. Tan G, Chew W, Lai CH. Carpal tunnel syndrome due to gouty infiltration of the lumbrical muscles and flexor tendons. *Hand Surg* 2003;8:121-5.
6. Tsai CY, Yu CL, Tsai ST. Bilateral carpal tunnel syndrome

- secondary to tophaceous compression of the median nerves. *Scand J Rheumatol* 1996;25:107-8.
7. Shapiro PS, Seitz WH Jr. Non-neoplastic tumors of the hand and upper extremity. *Hand Clin* 1995;11:133-60.
 8. Nicol KK, Ward WG, Pike EJ, Geisinger KR, Cappellari JO, Kilpatrick SE. Fine needle aspiration biopsy of gouty tophi: lessons in cost effective patient management. *Diagn Cytopathol* 1997;17:30-5.
 9. Wallace SL, Robinson H, Masi AT, Decker JL, McCarty DJ, Yu TF. Preliminary criteria for the classification of the acute arthritis of primary gout. *Arthritis Rheum* 1977;20:895-900.
 10. Weniger FG, Davison SP, Risin M, Salyapongse AN, Manders EK. Gouty flexor tenosynovitis of the digits: report of three cases. *J Hand Surg [Am]* 2003;28:669-72.
 11. Murray PM. Septic arthritis of the hand and wrist. *Hand Clin* 1998;14:579-87.
 12. Margaretten ME, Kohlwes J, Moore D, Bent S. Does this adult patient have septic arthritis? *JAMA* 2007;297:1478-88.
 13. Li SF, Henderson J, Dickman E, Darzynkiewicz R. Laboratory tests in adults with monoarticular arthritis: can they rule out a septic joint? *Acad Emerg Med* 2004;11:276-80.
 14. Butbul-Aviel Y, Koren A, Halevy R, Sakran W. Procalcitonin as a diagnostic aid in osteomyelitis and septic arthritis. *Pediatr Emerg Care* 2005;21:828-32.
 15. Yu KH, Luo SF, Liou LB, et al. Concomitant septic and gouty arthritis: an analysis of 30 cases. *Rheumatology (Oxford)* 2003;42:1062-6.
 16. Kelley WN, Schumacher HR Jr. Crystal associated synovitis. In: Kelley WN, editor. *Textbook of rheumatology*. 4th edn. Philadelphia: Saunders, 1993:1291-336.
 17. Pacheco G, Cavallasca JA. Images in clinical medicine. Deforming gout. *N Engl J Med* 2005;353:e20.
 18. Terek RM, Brien EW. Soft tissue sarcomas of the hand and wrist. *Hand Clin* 1995;11:287-305.
 19. Jbara M, Patnana M, Kazmi F, Beltran J. MR imaging: arthropathies and infectious conditions of the elbow, wrist, and hand. *Radiol Clin North Am* 2006;44:625-42.
 20. Ene-Stroescu D, Gorbien MJ. Gouty arthritis. A primer on late onset gout. *Geriatrics* 2005;60:24-31.