



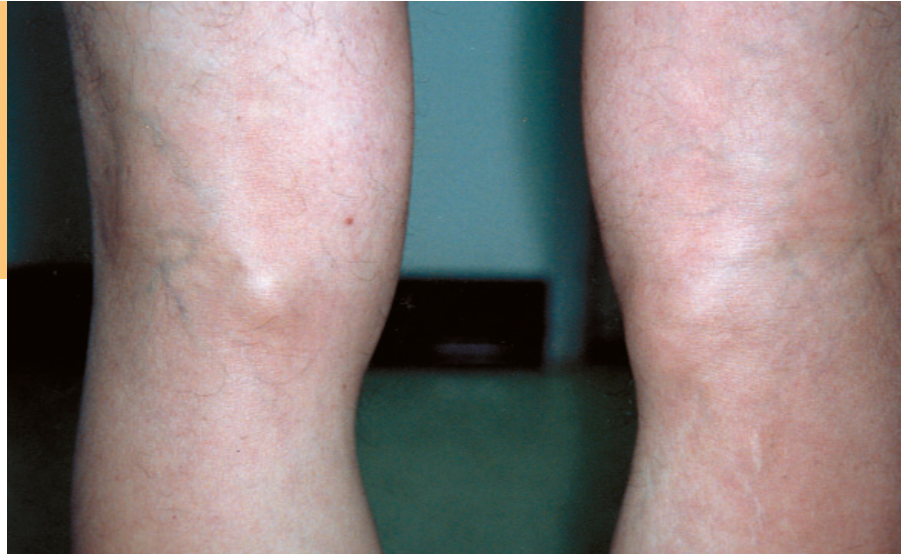
Knee swelling

Jerzy K Pawlak, MBBS, MSc, PhD, is a general practitioner, Winnipeg, Canada.



Case history

A 48 year old man presented with swelling at the back of his left knee which had appeared 2 weeks previously. He has intermittent pain that interferes with his daily activities. On examination, a soft cystic bulge near the midline at the back of the knee was noted.



Question 1

What is the diagnosis?

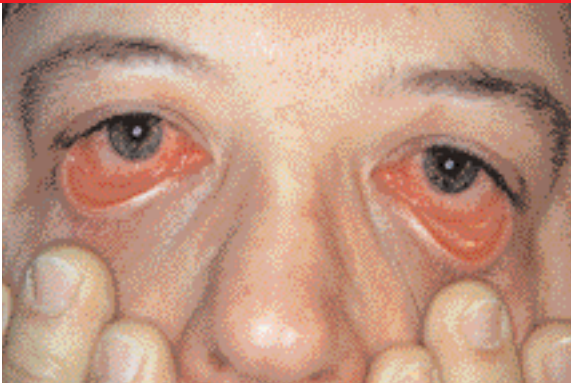Question 2

What is the cause of this problem?

Question 3

What is the treatment?

ANSWERS TO JUNE BRAIN TEASER



Send your answers to arrive by 20 July. A prize of 12 months subscription to 'eTG complete' valued at \$240 will be donated by Therapeutic Guidelines Ltd to the first correct entry drawn. The winner will be notified by mail and the answers published in the August issue.

Email entries to: afp@racgp.org.au
OR mail to: July Brain Teaser
Australian Family Physician
1 Palmerston Crescent
South Melbourne Victoria 3205



Freecall 1800 061 260

Answer 1

Viral conjunctivitis.

Answer 2

Adenovirus conjunctivitis is characterised by redness, tearing and a variable degree of photophobia. It is highly contagious for up to 10 days.

Answer 3

Cultures are unnecessary, as diagnosis is based on clinical evaluation.

Answer 4

Cold compresses can be applied for patient comfort. Children should stay away from school for 7-10 days. Prophylactic precautions should be observed by the patient's family members and friends.

The winner of the June Brain teaser is **Dr Nick Hallebone**, Deer Park, Vic