



TEST YOUR KNOWLEDGE: Brain teaser

An itchy skin lesion

A 28 year old man presents with a series of slightly raised pigmented plaques over the trunk, complaining of itching in one lesion which is situated in the epigastrium.

Question 1

What is the probable nature of the lesion?

Question 2


What is the cause of the lesion?

Question 3

What is the cause of the itching?

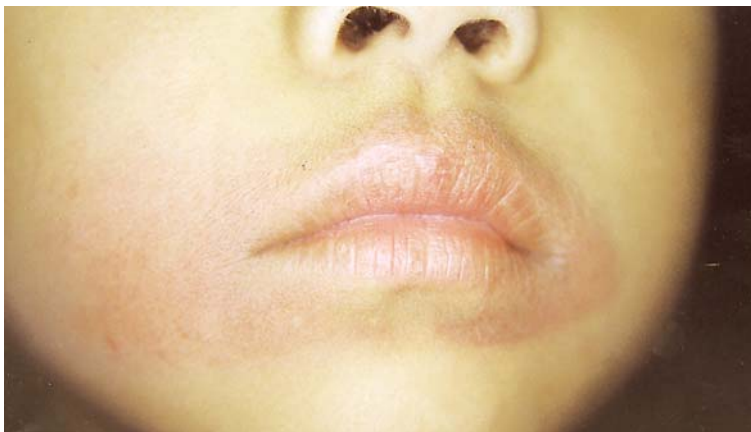Question 4

What action should be taken?



Gordon Clunie

Answer to last month's brain teaser



Answer 1

D. This patient has lip lickers dermatitis.

Answer 2

Lip lickers dermatitis is commonly seen in children and is caused by repeatedly licking the lips and the adjacent skin surrounding the vermilion. This leads to the classic distribution of the eruption with erythema and scaling around the mouth. The condition is clinically known as irritant dermatitis caused by saliva.

Answer 3

Treatment consists of liberal use of a bland emollient, such as petroleum. Cases of severe inflammation can be treated with a short course of topical low potency corticosteroids such as 1% hydrocortisone ointment. Patients and parents should be made aware that habitual lip licking will perpetuate the problem and that efforts to minimise or cease the licking will greatly improve the dermatitis.

AFP

Send your answers to arrive by 5 January. A voucher for medical books or medical equipment to the value of \$100 will be awarded for the first correct entry drawn. The winner will be notified by mail and the answer published in the January 2003 issue of AFP.

Address entries to:
December Brain Teaser
Australian Family Physician
1 Palmerston Crescent
South Melbourne
Victoria 3205

The winner of the October Brain teaser is Dr Francis T W Chung, Banksia, NSW