

**Catherine E Scarff**

MBBS, MMed, FACD, is a dermatologist,  
Skin and Cancer Foundation, Carlton, Victoria.  
cescarff@mac.com



# Sweaty, smelly hands and feet

**Background**

Palmoplantar hyperhidrosis, with or without offensive odour (bromhidrosis), can have a devastating effect on a patient's life. The condition usually begins in childhood or adolescence and can impact greatly on education, career choices and social development.

**Objective**

This article describes the presentation, investigation and management options for palmoplantar hyperhidrosis.

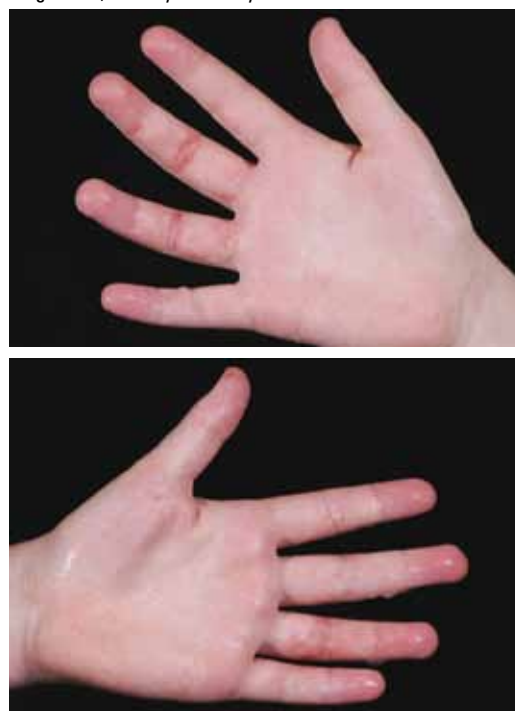
**Discussion**

Clinical history and examination is often sufficient to make a diagnosis of palmoplantar hyperhidrosis. Fortunately, there are successful treatments available that can provide relief of symptoms.

**Case study – Sally**

Sally is a cleaner, 44 years of age, who lives alone. She has suffered from sweaty palms and soles since her teens. She recalls being called out in front of the class in primary school to explain why her homework was 'smudged and ruined – again'. She left school early and started work as a cleaner. She has few friends, and a limited social network. She likes her work as she spends a lot of the day by herself. She has developed a large number of techniques to avoid shaking hands with others and other forms of physical contact. She has taken weeks to pluck up the courage to come and see you regarding her sweaty palms (*Figure 1a, b*) and soles. Her brother is getting married soon and as part of the bridal party, Sally knows she will have to hold hands and dance with her partner. She sits in front of you, shy and embarrassed. What do you do?

Figure 1a, b. Sally's sweaty hands





■ While by no means a life threatening condition, palmoplantar hyperhidrosis can be life destroying. Palmoplantar hyperhidrosis is a relatively common medical condition, although it often takes a long time to be recognised as such and for patients to then present for treatment.<sup>1</sup> Many texts report a tendency to spontaneous resolution after the mid 20s,<sup>2</sup> but patients such as Sally, who have put up with symptoms well into adult life, are not rare. Fortunately, there are successful treatments, which if instituted early, can have the condition under control before it has too great an impact on the patient's social life and development.

Sweating can be broadly divided into:

- apocrine, and
- eccrine

with eccrine glands being distributed widely over the body and numbering over 2 million.<sup>3</sup>

Eccrine gland function is primarily thermoregulatory and activity may alter in response to thermal, osmotic, mental and gustatory factors.<sup>2</sup> The hypothalamic sweat centre, which controls the palms and soles, is separate from the rest of the hypothalamic sweat centres. It is activated mainly by emotional and mental stimuli, and less so by thermoregulatory stimuli.<sup>2,4</sup>

Eccrine bromhidrosis may be associated with hyperhidrosis as the maceration of keratin by the sweat can lead to increased odour, especially of the soles. Pitted keratolysis of the feet is a bacterial infection of the stratum corneum due to infection with *Micrococcus sedentarius*. It occurs in the setting of hyperhidrosis and presents with numerous small pits over the web spaces and plantar surfaces of the feet. Fungal infections and intertrigo can also contribute to smell.

## Clinical presentation

Hyperhidrosis can be considered as primary or secondary and this article focuses on the former. Primary palmoplantar hyperhidrosis usually begins in childhood or early adolescence and all ethnic groups are affected.<sup>3</sup> The sweating is usually persistent throughout the seasons.<sup>2</sup> Hornberger<sup>5</sup> has defined the condition as being present as focal, visible, excessive sweating of at least 6 months duration without apparent cause, with at least two of the following features: bilateral and relatively symmetric, impairing daily activities, at least one episode per week, onset before 25 years of age, positive family history, and cessation of focal sweating during sleep. This occurs in the absence of symptoms or signs of secondary hyperhidrosis such as generalised sweating, fever, weight loss, anorexia, diarrhoea, palpitations, the use of certain medications, and night sweats (Table 1).<sup>2,3,5</sup>

As sweating may be episodic, the degree of sweating noted on examination may vary from minimal to obvious, with sweat dripping on the floor in severe cases. The temperature of the hands and feet are often lower, feeling cold and clammy. The feet may show the presence of small pits if pitted keratolysis is present and the 'cheesy'

Table 1. Aetiology of secondary hyperhidrosis<sup>2,3</sup>

<b>Cardiorespiratory</b>	Acute myocardial infarction Cardiac failure Respiratory failure
<b>Drugs</b>	Alcohol (chronic and acute intoxication) Aspirin Insulin Antidepressants (eg. fluoxetine) Amphetamines
<b>Endocrine</b>	Hyperthyroidism Diabetic autonomic neuropathy Hypoglycaemia Gout Pheochromocytoma Hyperpituitarism Carcinoid syndrome Menopause Obesity
<b>Infection</b>	Tuberculosis Malaria Infectious endocarditis Brucellosis HIV
<b>Malignancy</b>	Lymphoma Leukaemia Solid malignancies
<b>Neurological</b>	Post spinal injury Stroke Parkinson disease Peripheral neuropathies

smell is characteristic. Evidence of a dermatosis may be present with scaling of the skin or intertrigo.

An assessment of the impact of the condition on the patient's life is warranted. Though uncommon, some patients are so distressed by their condition that reactive depression and suicidal tendencies may be present (anecdotal).

## Investigations

When the history is typical, clinical history and examination are sufficient to diagnose primary hyperhidrosis. If abnormalities of the skin are present, bacterial swabs and scrapes for fungi may be taken to identify pathogens. If any features suggestive of secondary hyperhidrosis are present, or if the presentation is not typical (eg. unilateral or asymmetric symptoms) then targeted investigations should be performed. These may include thyroid function testing for hyperthyroidism, full blood count, and relevant imaging if a



neoplastic, infectious or neurological cause is suspected. Referral for further opinion may also be warranted.

## Initial management

The first line treatment for primary palmoplantar hyperhidrosis should be with antiperspirants. Topical aluminium chloride hexahydrate 20% (available over-the-counter at chemists for less than \$20) should be trialled at night until euhidrosis is achieved. The frequency can then be decreased to several times per week. The effect is thought to be due to an occlusive action of aluminium containing particles in the upper epidermis and change in ionic transport within secretory cells.<sup>6</sup> However, this is generally effective in only the mildest cases. Irritation, which can occur when the preparation is applied to other sites, is much less of a problem when used on the thicker acral skin.

Oral anticholinergics, such as propantheline, may be tried, but these usually require doses that cause intolerable side effects, including dry eyes, dry mouth and throat, and urinary retention, before they have any real benefit on the sweating.<sup>5,7</sup>

The presence of a fungal infection requires treatment. Topical creams may be tried initially (terbinafine, the azole group) but if extensive, a short course of an oral preparation may be required. The identification of the pathogen is useful in helping to decide between terbinafine and the cheaper preparation, griseofulvin. The presence of pitted keratolysis similarly requires treatment. An antibacterial wash in the shower, such as benzoyl peroxide 5%,<sup>8</sup> is an important first step; but inform the patient to make sure this is washed away well as it has bleaching properties. Otherwise, topical antibiotics such as clindamycin 1% or erythromycin 2%, or a combination product containing benzoyl peroxide 5% and clindamycin 1%, could be used. The azole antifungals may also give good results.<sup>9</sup> If unsuccessful, a course of oral antibiotics such as erythromycin for 7–10 days may be required.

It is also important to pay attention to the patient's footwear. Occlusive and rubber shoes often exacerbate the problem by increasing sweating. Patients should change their socks frequently and alternate the shoes they wear each day to allow the shoes to dry out. Fungi can survive for 30 days off the body, so shoes and socks can be a reservoir for re-infection.

Patient education is also important and a useful website for patients to learn more about their condition is [www.sweathelp.org](http://www.sweathelp.org). Symptoms of depression should be looked for and managed as necessary.

## Further management

Unfortunately, topical antiperspirants are generally ineffective. Iontophoresis is generally the next line of treatment. This technique uses a local electric current to force the ions of a substance into tissues. This can be done with tap water alone<sup>7</sup> or with anticholinergic drugs. At the Skin and Cancer Foundation (Victoria), the patient places their unilateral hand and foot into trays containing solution (either tap water alone or an anticholinergic drug) and a current is applied for 10 minutes. The process is then repeated for the other side of the body. Patients sometimes elect to purchase

their own iontophoresis units for use in their own homes with tap water. Treatment is required several times a week initially, then on an ongoing basis. Pregnancy and a history of metallic implants such as orthopaedic prostheses and cardiac pacemakers are contraindications to this treatment. Iontophoresis using an anticholinergic solution, such as glycopyrrolate is superior to tap water.<sup>9,10</sup> Some systemic absorption of the drug occurs, resulting in anticholinergic side effects for a day or so after treatment. This is generally limited to a dry throat, although it may also include blurred vision and dry eyes. The treatment is available only in specialised centres as the use of the drug in this manner is 'off label'.

Botulinum toxin for the management of palmoplantar hyperhidrosis is well reported.<sup>11–13</sup> The toxin inhibits the release of acetylcholine from presynaptic nerve endings. When successful, this treatment has the advantage of long duration of symptom relief, often for at least 6 months in most patients,<sup>13</sup> although a longer period of time has been reported.<sup>12</sup> Side effects include pain from the multiple injections required (the toxin diffuses approximately 1 cm from the point of injection and some form of analgesia is usually required, eg. methoxyflurane inhalation, nerve block, or in some cases, general anaesthesia), weakness of the intrinsic muscles of the hands,<sup>12,13</sup> and cost. Neutralising antibodies were once thought to limit the long term use of this treatment. However, Gordon et al<sup>14</sup> report this is not a clinical issue for most patients undergoing long term treatment with botulinum toxin type A. Botulinum toxin contains the blood product human albumin and its use may be unacceptable to some patients. Botulinum toxin may interact with medications that affect neuromuscular transmission including aminoglycosides and curare-like compounds, and this may last 3–6 months after administration.<sup>15</sup> A limited number of dermatologists offer this service, often in specialised clinics.

Surgical treatments for primary palmar hyperhidrosis are generally limited to those for whom noninvasive therapies fail or are contraindicated. Endoscopic thoracic sympathectomy is the most common procedure currently performed. The thoracic sympathetic ganglia are ligated or cauterised and the sweat ducts thus denervated.<sup>1,16–18</sup> The effect is immediate and often permanent. Perhaps the biggest drawback of this procedure is compensatory hyperhidrosis. In some patients, this is as troublesome as the initial palmar hyperhidrosis.

## Summary

Palmoplantar hyperhidrosis, with or without bromhidrosis, can have a devastating effect on a patient's self esteem. Fortunately, as both patients and doctors are more aware of the condition and the options for management, treatment can be started early enough to limit the effect this condition has on patients' life. Sally's (see *Case study*) life may have been very different had she been treated when the condition first developed.

Conflict of interest: none declared.



## Acknowledgment

The author would like to thank Kathy Teagno, medical photographer at the Skin & Cancer Foundation, for her assistance in providing the clinical photographs.

## References

1. Malone PS, Cameron AEP, Rennie JA. The surgical treatment of upper limb hyperhidrosis. *Br J Dermatol* 1986;115:81–4.
2. Coulson IH. Disorders of sweat glands. In: Burns T, Breathnach S, Cox N, Griffiths C, editors. *Rook's textbook of dermatology*. 7th edn. Vol 3; Chp 45. Blackwell Science Ltd, 2004;1–23.
3. Roberts H, Dolianitis C, Sinclair R. Overview of hyperhidrosis. *Medicine Today* 2007;8:47–52.
4. Goldsmith LA. *Fitzpatrick's dermatology in general medicine*. 6th edn. New York: McGraw-Hill, 2003;699–704.
5. Hornberger J, Grimes K, Naumann M, et al. Recognition, diagnosis and treatment of primary focal hyperhidrosis. *J Am Acad Dermatol* 2004;51:274–86.
6. McWilliams SA, Montgomery I, McEwan Jenkinson D, Elder HY, Wilson SM, Sutton AM. Effects of topically-applied antiperspirant on sweat gland function. *Br J Dermatol* 1987;117:617–26.
7. Stolman LP. Treatment of excess sweating of the palms by iontophoresis. *Arch Dermatol* 1987;123:893–6.
8. Lee PK, Zipoli MT, Weinberg AN, Swartz MN, Johnson RA. *Fitzpatrick's dermatology in general medicine*. 6th edn. New York: McGraw-Hill, 2003;1875–6.
9. Dolianitis C, Scarff CE, Kelly J, Sinclair R. Iontophoresis with glycopyrrrolate for the treatment of palmo-plantar hyperhidrosis. *Australas J Dermatol* 2004;45:208–12.
10. Abell E, Morgan K. The treatment of idiopathic hyperhidrosis by glycopyrronium bromide and tap water iontophoresis. *Br J Dermatol* 1974;91:87–91.
11. Naumann M, Flachenecker P, Brocker E-B, Toyka KV, Reiners K. Botulinum toxin for palmar hyperhidrosis. *Lancet* 1997;349:252.
12. Shelley WB, Talanin NY, Shelley ED. Botulinum toxin therapy for palmar hyperhidrosis. *J Am Acad Dermatol* 1998;38:227–9.
13. Saadia D, Voustantiounk A, Wang AK, Kaufmann H. Botulinum toxin type A in primary palmar hyperhidrosis: Randomized, single-blind, two-dose study. *Neurology* 2001;57:2095–9.
14. Gordon MF, Barron R. Effectiveness of repeated treatment with botulinum toxin type A across different conditions. *South Med J* 2006;99:853–61.
15. Scheinberg A. Clinical use of botulinum toxin. *Aust Prescr* 2009;32:39–42.
16. Drott C, Göthberg G, Claes G. Endoscopic transthoracic sympathectomy: An efficient and safe method for the treatment of hyperhidrosis. *J Am Acad Dermatol* 1995;33:78–81.
17. Reisfeld R, Nguyen R, Phini A. Endoscopic thoracic sympathectomy for treatment of essential hyperhidrosis syndrome: Experience with 650 patients. *Surg Laparosc Endosc Percutan Tech* 2000;10:5–10.
18. Han P, Gottfried O, Kenny K, Dickman C. Biportal thorascopic sympathectomy: Surgical techniques and clinical results for the treatment of hyperhidrosis. *Neurosurgery* 2002;50:306–12.