

**Mark Mackinnon**

FRACGP, is an examiner, The Royal Australian College of General Practitioners, and a general practitioner, Cairns, North Queensland. jomapytld@bigpond.com

In general practice, 'always expect the unexpected'

Case study

Mr SF, aged 72 years, presented to a senior colleague complaining of a scalp sore which was failing to heal. The patient had injured his head while mustering cattle 4 years earlier. He consulted his local medical officer at that time and was reassured and sent on his way.

Six weeks before presenting to our practice, Mr SF had split his head open again. Although he was not overly concerned about it at the time, it had been slow to heal and he had consulted a naturopath. The naturopath was packing the scalp sore with comfrey leaves and had advised Mr SF to eat curry to aid with its healing. He had been seeing this alternative practitioner each week for the preceding 6 weeks. Mr SF had become disillusioned with the poor results he was getting. At the behest of his wife he was seeking another opinion.

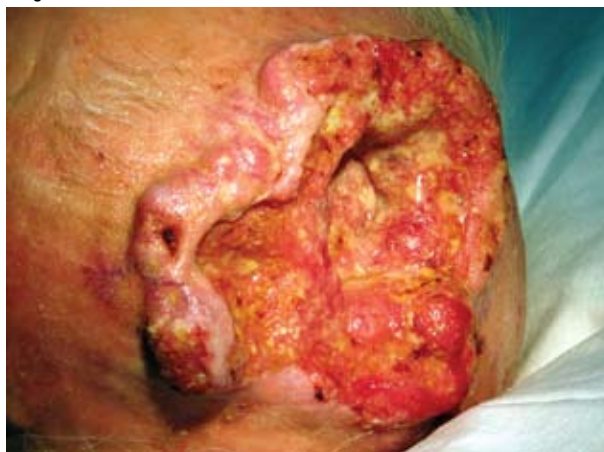■ Mr SF had been covering his head with gauze to protect it. Removal of the covering revealed a massive erosive lesion measuring 11x10 cm (*Figure 1*). It appeared that the lesion had eroded through the skull, soft tissue and down to the meninges of the brain. Careful observation showed a pulsatile area through which was percolating frank blood.

A provisional diagnosis of a squamous cell carcinoma (SCC) was made. Mr SF was referred to a local surgeon for opinion, together with follow up. Arrangements were made for a computerised tomography (CT) scan of the skull, as well as 9x3 mm biopsy of the tissue to identify the lesion.

Biopsy revealed the lesion to be a SCC without lateral or medial margins. The CT scan showed a large fungating scalp mass with a large bony defect at 44x32 mm in diameter, which passed into the cranial cavity involving the meninges. (Margins obtained by axial cut indicated that the skull and meningeal involvement was caused by erosive change rather than from the biopsy). No evidence of intracranial metastasis was shown but there was reactive oedema in the white matter of the right frontal lobe (*Figure 2a-d*).

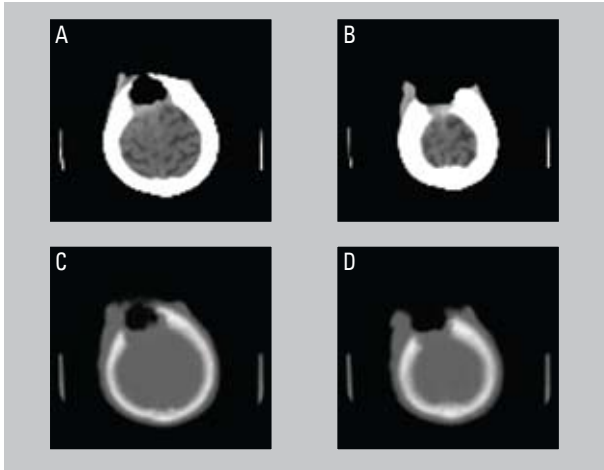
Feedback from the surgeon was that neurosurgical assessment would be required and the prognosis was unknown, but most likely

Figure 1. Erosive lesion



poor. Mr SF was referred on to a radiation oncologist and a decision was made to irradiate the lesion with 60–70 Gy to the remaining tissue as a palliative measure. During the assessment period he suffered left hemiparesis, which was progressive.

Figure 2a–d. CT scan revealing reactive oedema of right frontal lobe



Discussion

While the Australian community has embraced alternative medicine, cases such as this raise doubt about an 'alternative' practitioner's ability to diagnosis and recognise a life threatening problem. We also do not know how long the lesion was present. It is possible that the lesion was present and much smaller when Mr SF attended a GP with his 'scalp wound' 4 years previously. In general practice always expect the unexpected and in doing this, and in sharing and discussing cases with colleagues, you will appreciate that general practice is both clinically stimulating and surprising.

Conflict of interest: none declared.

Acknowledgment

Thanks to my colleague Dr Edward 'Ed' Williams whose patient this case study is based on.