

# More than just a headache

**Jerzy K Pawlak**

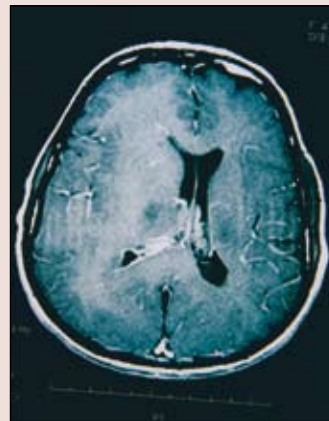
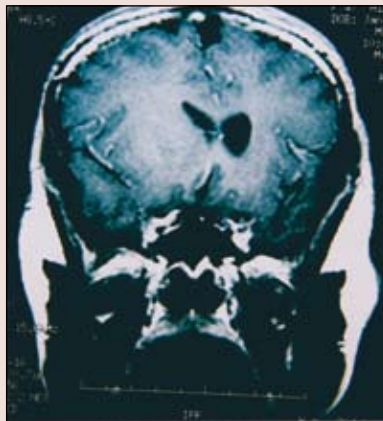
MBBS, MSc, PhD, is a general practitioner, Winnipeg, Canada.

**TJ Krocak**

is a student, Faculty of Science, University of Winnipeg, Canada.

**Case history**

Celine, aged 44 years, developed recurrent headaches about 7 months ago. She was found to have an elevated blood pressure at that time and this was treated. However, her headaches got worse and a few months ago, her family started noticing weakness on her left side with facial asymmetry and dragging of her leg. Celine then started to experience weakness in her left arm. Her family found that her speech had been slower and they reported some memory loss and difficulty in comprehension. Celine lives with her husband and one son. She is right handed and does most of her work on a computer. Magnetic resonance imaging (MRI) was performed.



**Question 1**

What does the MRI show?

**Question 2**

What is the likely diagnosis and why?

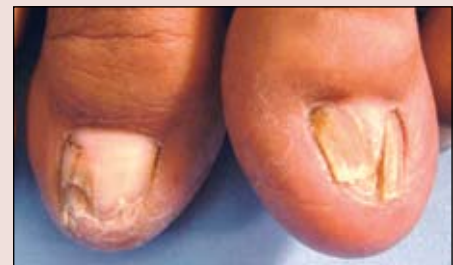**Question 3**

What treatment would you expect Celine to require?

**ANSWERS TO JULY BRAIN TEASER**

**Answer 1**

Both toenails have a central, slightly elevated ridge with a canal-like split within. The left toe is more severely affected and the vertical split is dividing the nail into two separate



portions. The right toe has similar longitudinal ridge but has not divided yet. The distal parts of the right toe nail shows onycholysis.

**Answer 2**

The diagnosis is median canal dystrophy. This condition is also known as dystrophic longitudinalis fissuriformis. It is an acquired nail deformity of unknown cause characterised by sudden onset development of a central groove in the nail plate.

**Answer 3**

Lichen planus is another differential diagnosis that can cause nail dystrophy and longitudinal splitting.