

**Terry Wu**

MBBS, FRACS, is a plastic surgeon, Waverley Private Hospital, Epworth Eastern Medical Centre, Cotham Private Hospital, Peter MacCallum Cancer Institute, Dandenong and Box Hill Hospitals, and the Skin and Cancer Foundation, Melbourne, Victoria. drttw@optusnet.com.au

Plastic surgery made easy

Simple techniques for closing skin defects and improving cosmetic results

BACKGROUND

Although meticulous technique cannot guarantee a superior cosmetic result when repairing skin wounds or excising skin lesions, a well planned and executed repair reduces the risk of unsatisfactory scarring.

OBJECTIVE

This article discusses sound plastic surgery principles that every doctor operating on the skin can apply. Common suture techniques and simple flap techniques and their indications are also discussed.

DISCUSSION

Principles of effective wound repair include: good lighting and equipment, atraumatic tissue handling, early repair of traumatic wounds, thorough wound debridement and lavage, avoiding healing by secondary intention, judicious antibiotic prophylaxis, appropriate planning of incisions, carefully executed incisions, avoiding wound repair under tension, layered wound repair, use of appropriate suture size and needle, everted wound edges, use of adjuncts such as skin tapes and soft tissue adhesives, and early suture removal. Useful suture techniques include deep dermal sutures with buried knots, simple interrupted sutures, vertical mattress, horizontal mattress, subcuticular sutures, continuous over-and-over sutures and far-near near-far pulley sutures. Rotation, transposition, advancement and island flaps can be useful to close defects in situations where skin grafting is not possible or desirable.

'Will the surgery leave a scar?' is one of the most frequently asked questions that surgeons face. While operating on deeper structures may present more of a challenge for surgeons, patients often judge the skills of a surgeon by the cosmetic appearance and scarring resulting from surgery. With appropriate expertise and technique, a well placed fine line scar should be a goal that all surgeons aim to deliver to their patients.

Every surgical or traumatic wound heals with a scar. The final appearance of any scar is dependent on:

- patient factors
- wound factors, and
- technical factors.

Patient factors include the patient's general health and comorbid conditions, age, ethnicity, hereditary predisposition, skin type, and medications. While these

factors are often outside the control of a surgeon, every effort should be made to optimise any correctable problems. A past history of keloid or hypertrophic scar should also alert the patient and the surgeon that close follow up and early intervention may be needed.

Wound factors include the nature of the wound (eg. traumatic vs. elective), the location and orientation of the wound, the vascularity and quality of local tissues, the elasticity and tension of adjacent soft tissues, and the degree of contamination by bacteria and dirt. Except for the location of traumatic wounds, surgeons can often influence the final result by improving some of the wound factors.

The technical factors are completely within the control of the surgeon and include the planning of incisions, care of tissue handling, adequacy of debridement, sutures used, method and tension of wound repair, the period of time that sutures are left in situ, and postoperative scar management.

Although meticulous technique cannot guarantee a fine line scar, a well planned and executed wound repair reduces the possibility of unfavourable scarring.

Basic principles of wound repair

Good lighting and equipment

It cannot be emphasised enough that good lighting and equipment are paramount for a good surgical result. Appropriately sized toothed forceps and needle holders are important, while good cutting scissors need to be part of every suture kit. A selection of scalpel sizes should also be available, although the most frequently used is the size 15 scalpel.

Atraumatic soft tissue handling

Tissue ischaemia and desiccation result in necrosis and poor scarring. It is vitally important to avoid rough tissue handling and crushing instruments. Skin hooks, cat's paws and toothed forceps facilitate atraumatic tissue handling. Frequent tissue wetting with normal saline prevents tissue desiccation. Judicious cautery can prevent bleeding and improve wound healing.

Early repair of traumatic wounds

Bacterial inoculation of the wound may be increased when the wound repair is significantly delayed. Traumatic wounds should be repaired as soon as possible. However, when an early repair is not possible, appropriate dressings to reduce tissue desiccation and contamination may allow the surgeon to close the wound up to 24–48 hours later.

Thorough wound debridement and lavage

Debridement involves the removal of all devitalised and contaminated tissues with maximal preservation of critical anatomical structures. Copious irrigation or pulsatile jet lavage should also be used to remove residual contaminants. Often when the border between viable and devitalised tissues is not clear, it is important to dress the wound appropriately to prevent desiccation and return for a subsequent debridement 24–48 hours later. More reconstructions after trauma fail because of inadequate debridement than because of failed reconstructive technique.

Avoid healing by secondary intention

Healing by secondary intention should be avoided as it is prolonged and often produces hypertrophic scarring.

Judicious antibiotic prophylaxis

A single prophylactic antibiotic dosage administered just before skin incision may reduce the incidence of wound infection.

Appropriate planning of incisions

In excising a lesion in an elliptical fashion, the long axis should be four times the length of the short axis. When the ellipse is too short, or one side of the ellipse is shorter than the other, 'dog ears' form at the ends of the repaired wound (*Figure 1*). Although 'dog ears' may flatten over time, prevention or primary correction gives the best result.

The final orientation of an elliptical incision should be parallel to the 'relaxed skin tension lines' (RSTL). These lines correspond to skin wrinkle lines and lie perpendicular to the long axis of underlying muscles. They represent lines of minimal skin tension. Maximal scar contraction occurs when a scar crosses RSTL at a right angle and may be very obvious. Scars are best concealed when they are placed along RSTL and natural borders between anatomical regions (*Figure 1*). Examples include placing the scars along forehead wrinkles or nasolabial folds.

Every effort should be made to avoid incisions crossing a joint crease at a right angle and particularly over the flexor surface of a joint. These incisions can result in scar and joint contractures.

When an excision is planned, it is important to avoid distortion of adjacent anatomical landmarks such as the eyelid, eyebrow or ear helical rim. Frequently a flap should be used to avoid distortion of an anatomical landmark even though direct closure is technically possible. Wedge excisions may be used on lips or eyelids while stepped wedge excisions may be useful to avoid helical notching when excising full thickness ear lesions (*Figure 2*).

Expertly executed incisions

Incisions should be made confidently and cleanly. Incisions should be perpendicular to the skin surface and should not be angled. Poorly executed incisions can impair wound edge apposition and result in poor scarring.

Avoid wound repair under tension

Wound repair under tension greatly increases tissue ischaemia and necrosis and often results in dehiscence and poor scarring. When tension free direct closure

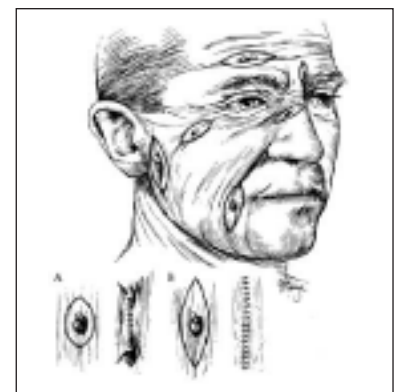

Figure 1. Positioning of incisions along RSTL and natural anatomical borders
Reproduced with permission: Aston SJ, Beasley RW, Thorne CHM, editors. Grabb and Smith's plastic surgery. 5th ed. Philadelphia: Lippincott-Raven, 1997

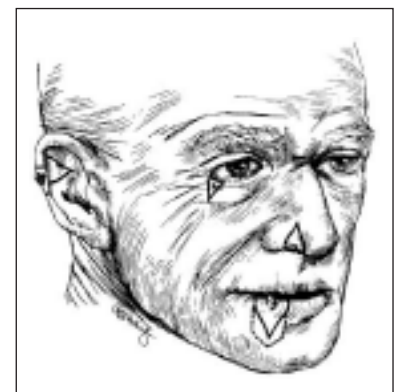


Figure 2. Wedge excisions on lips, nose, eyelids and ears
Reproduced with permission: Aston SJ, Beasley RW, Thorne CHM, editors. Grabb and Smith's plastic surgery. 5th ed. Philadelphia: Lippincott-Raven, 1997

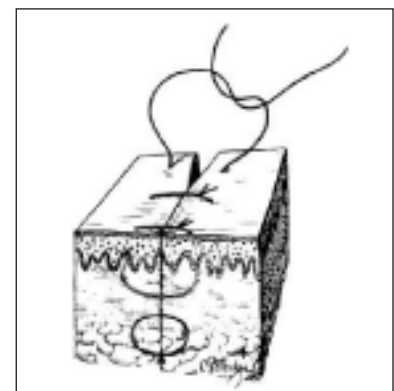


Figure 3. Deep dermal sutures decrease wound tension and facilitate wound eversion. Skin is then closed with simple interrupted sutures
Reproduced with permission: Aston SJ, Beasley RW, Thorne CHM, editors. Grabb and Smith's plastic surgery. 5th ed. Philadelphia: Lippincott-Raven, 1997

is not possible, reconstruction with either a skin graft or flap will be needed.

Layered wound repair

Deep dermal sutures with buried knots provide the strongest skin wound repair and remove the tension from superficial interrupted sutures. They also allow the superficial sutures to be removed at an earlier date in order to prevent cross hatching. Deep dermal sutures also align the dermis for accurate dermis apposition and sets the stage for superficial skin sutures.

Use appropriate suture size and needle

By using the smallest possible suture placed correctly, wound repair strength can be maintained and tissue ischaemia can be minimised. Usually 5/0 or 6/0 sutures are required for the face and hand, while 4/0 or 3/0 sutures may be used on the limbs or trunk. For skin repair, a cutting or reverse cutting needle traverses through tissue atraumatically.

Everted wound edges

Wound edge eversion is a tenet of good skin repair and is achieved by biting a larger amount of the deeper dermis when introducing the needle through the skin. This could be achieved by introducing the needle vertically at the skin surface and follow the arc of the needle by forearm supination. After tying the knot, the suture appears pear shaped in cross section.

Use of adjuncts such as skin tapes and soft tissue adhesives

Correctly applied skin tapes such as steri-strips or micropore tape provide wound splinting and reinforce the wound repair. In children, the application of tissue

adhesives such as Dermabond on the skin surface after deep dermal buried sutures can avoid the disadvantages of absorbable superficial sutures or the need to remove nonabsorbable superficial sutures.

Early suture removal

When sutures are left in for too long, they become buried and produce cross hatching. In general, when optimal wound healing has occurred and deep dermal buried sutures are used, superficial sutures should be removed from the face in about 3–5 days, while sutures elsewhere on the body should be removed in about 7–10 days. It is important that the wounds are supported by skin taping after suture removal.

Common techniques for sutures

Deep dermal sutures with buried knots

Usually an absorbable suture such as Monocryl is used. This deep suture is vital at facilitating wound eversion and accurate tension free superficial skin sutures (*Figure 3*).

Simple interrupted sutures

Simple interrupted sutures are the most commonly used sutures. The needle should be introduced at 90° into the skin in order to include a larger amount of the deeper dermis. This allows the width of the suture at its base in the dermis to be wider than the epidermal entrance and exit points. A synthetic nonabsorbable suture such as nylon is often used.

Vertical mattress

Vertical mattress sutures are used when wound eversion fails to be achieved by simple interrupted sutures. Vertical mattress sutures leave obvious cross hatching and must be removed early.

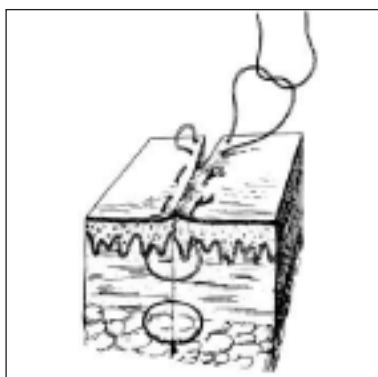


Figure 4. Horizontal mattress sutures
Reproduced with permission: Aston SJ, Beasley RW, Thorne CHM, editors. Grabb and Smith's plastic surgery. 5th ed. Philadelphia: Lippincott-Raven, 1997

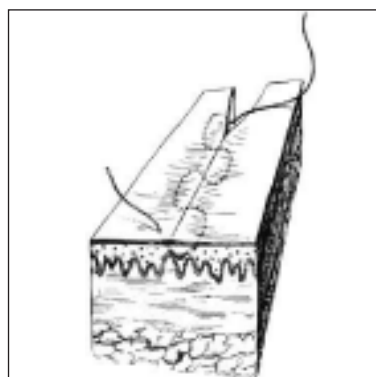


Figure 5. Continuous subcuticular sutures
Reproduced with permission: Aston SJ, Beasley RW, Thorne CHM, editors. Grabb and Smith's plastic surgery. 5th ed. Philadelphia: Lippincott-Raven, 1997

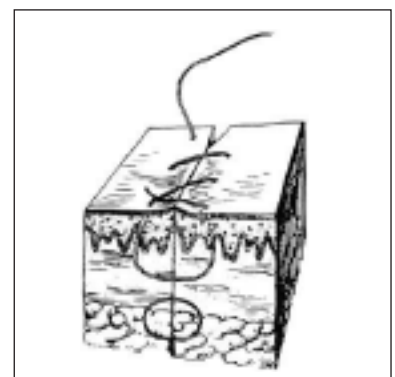


Figure 6. Continuous over-and-over sutures
Reproduced with permission: Aston SJ, Beasley RW, Thorne CHM, editors. Grabb and Smith's plastic surgery. 5th ed. Philadelphia: Lippincott-Raven, 1997

Horizontal mattress

Horizontal mattress sutures may help with wound eversion, although they theoretically cause more wound ischaemia (Figure 4).

Subcuticular

Continuous subcuticular sutures provide an excellent way to achieve accurate skin edge apposition without external sutures or cross hatching. The needle is introduced horizontally through the superficial dermis parallel to the skin surface and the bites need to be made at the same depth and of the same amount each time in order to achieve an accurate skin edge approximation (Figure 5). Either a synthetic absorbable suture such as Monocryl, or a synthetic nonabsorbable suture such as nylon, can be used and removed 1–2 weeks later.

Continuous over-and-over sutures

Continuous over-and-over sutures can be placed rapidly and provide haemostasis by compression of the wound edges (Figure 6). They may be useful in scalp closures.

Far-near near-far pulley sutures

The far-near near-far pulley sutures are a modification of the vertical mattress sutures and provide a pulley effect to achieve wound closure under tension. The sutures may be used as a temporary measure to bring the wound edges together in order for the deep dermal and superficial interrupted sutures to be placed. The pulley sutures may then be removed to minimise cross hatching. The first loop is placed approximately 4–6 mm from the wound edge on the far side and exits approximately 2 mm from the wound edge on the near side. The suture crosses the wound and re-enters the skin on the far side at 2 mm from the wound edge and the suture exits the skin on the near side 4–6 mm away from the wound. This completes the two loops that act as a pulley (Figure 7).

Flap techniques for the treatment room

Simple local flaps can provide better colour, texture and thickness of tissues for the reconstruction. Flaps are particularly useful when a skin graft is not desirable or possible due to poor recipient site factors. The main disadvantages of local flaps include a steep learning curve and additional scarring in the area of the reconstruction from the donor site. The basic principles of all flap reconstructions are to:

- define the defect first
- find an area where there are redundant tissues and design a way to transfer these tissues to repair the defect which is short of tissues.

This method relies on the skin's natural visco-elasticity and is often easier to carry out in the older patient as there is more skin laxity. The most important part of the flap reconstruction is in its planning. The flap should be designed 'in reverse' starting with defining the defect and transferring it onto a pattern. This pattern is then used to carry out the steps of flap reconstruction in the reverse order until

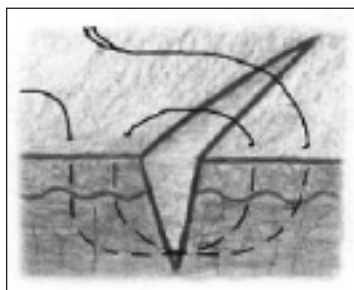


Figure 7. Far-near near-far pulley sutures

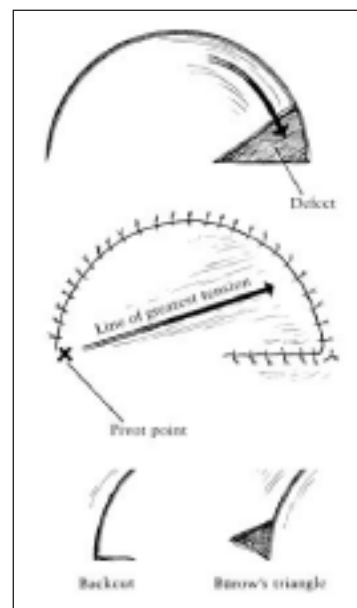


Figure 8. Rotation flap
Reproduced with permission: Aston SJ, Beasley RW, Thorne CHM, editors. Grabb and Smith's plastic surgery, 5th ed. Philadelphia: Lippincott-Raven, 1997

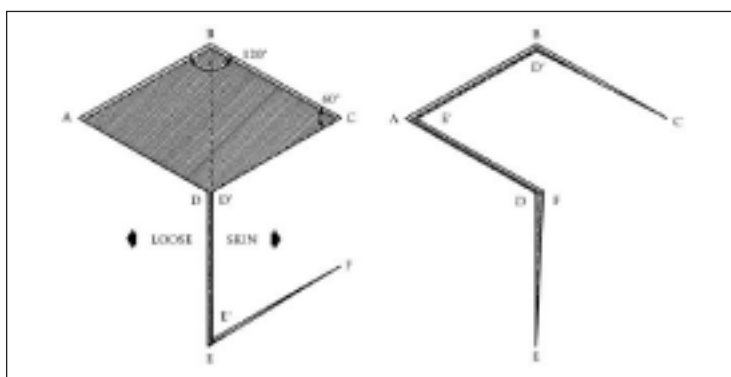


Figure 9. Transposition flap
Reproduced with permission: Aston SJ, Beasley RW, Thorne CHM, editors. Grabb and Smith's plastic surgery, 5th ed. Philadelphia: Lippincott-Raven, 1997

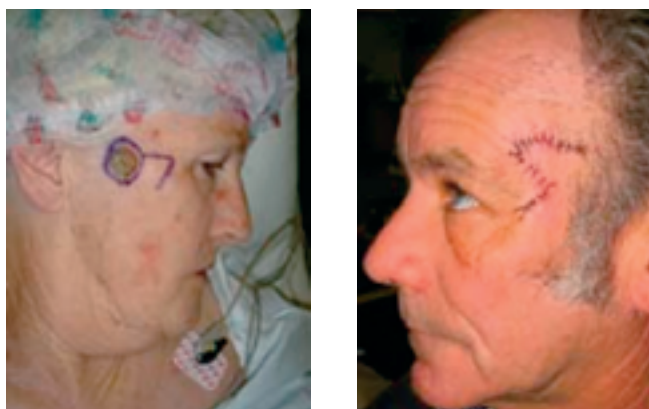

Figure 10. Clinical examples of Limberg flaps

the donor site is reached. The flap pedicle should be of adequate size and not be under excessive tension. Particular attention should be made to make the flap slightly bigger than needed, as one of the most common causes of failed flap reconstruction is an inadequately sized flap for the defect. The steps of the reconstruction should then be rehearsed again with the pattern before the actual execution.

There are several simple flaps that can be useful in the treatment room. Local flaps can be classified by their design. Flaps that rotate about a pivot point include rotation, transposition and interpolation flaps. Flaps that work by advancement include single pedicle advancement, V-Y advancement, Y-V advancement and bi-pedicle advancement flaps. Island flaps are designed with a vascular pedicle and can be inset into an adjacent or regional defect.

While a detailed description of these techniques is beyond the scope of this article, the following summary may be useful.

- A rotation flap is a semi-circular flap of skin that rotates about a pivot point into the defect. The circumference of the flap may need to be up to six times the length of the defect (*Figure 8*). The line of the greatest tension is from the pivot point to the distal limit of the defect and can be lessened by a back cut or a Burrow's triangle.
- A transposition flap is a rectangular flap of skin that is rotated about a pivot point into an immediately adjacent defect (*Figure 9*). An example is the 'Limberg flap'. It can be very useful around the temple and the area lateral to the lateral canthus (*Figure 10*).
- An advancement flap is moved directly forward into a defect without any rotation or lateral

movement (*Figure 11*). A back cut or Burrow's triangle may help the flap's advancement. Advancement flaps may be useful around the forehead.

- An island flap is based on a vascular pedicle and may allow a greater degree of freedom in the flap's inset. A nasolabial or nasalis myocutaneous island flap may be useful for a lateral nose defect (*Figure 12a-c*).

Conclusion

Every doctor performing a surgical procedure can practise the principles of plastic surgery. With a good understanding of anatomy and wound healing and meticulous attention to detail, all doctors can endeavour to provide their patients with superior surgical and cosmetic results.

Conflict of interest: none declared.

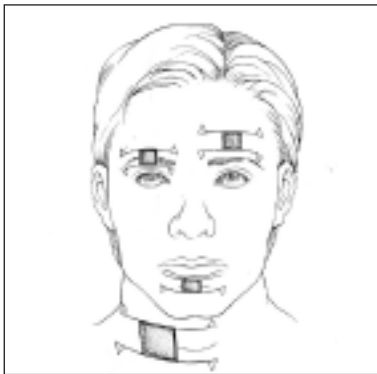

Figure 11. Advancement flaps
Reproduced with permission: Achauer BM, Eriksson E, Guyuron B, et al, editors. Plastic surgery indications, operations and outcomes. Vol. 3. St Louis: Mosby, 2000

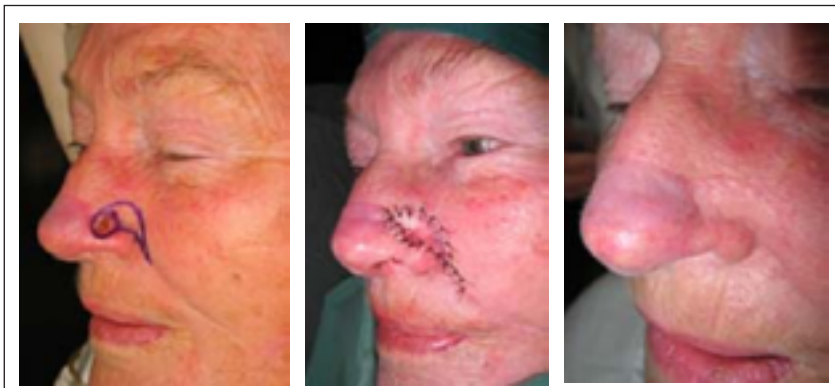

Figure 12a. Nasalis island flap planning
Figure 12b. Nasalis island flap immediately postoperation
Figure 12c. Nasalis island flap 3 months postoperation