

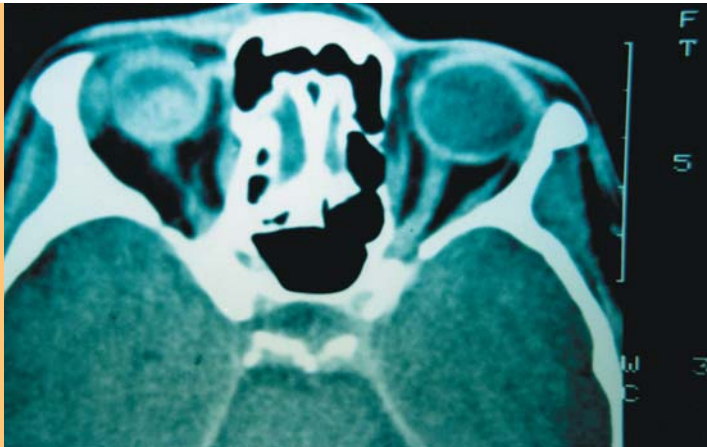


# Choroidal melanoma

Jerzy K Pawlak, MBBS, MSc, PhD, is a general practitioner, Winnipeg, Canada.

## Case history

A 51 year old woman with a known choroidal melanoma (diagnosed 5 years earlier) presented with marked visual loss to her right eye due to a massive retinal haemorrhage. The haemorrhage prevented examination of her retina. An ultrasound showed significant tumour growth. A computerised tomography (CT) scan of the orbits with infusion was performed.



## Question 1

What does the CT scan show?

## Question 2

How may a choroidal melanoma present clinically?

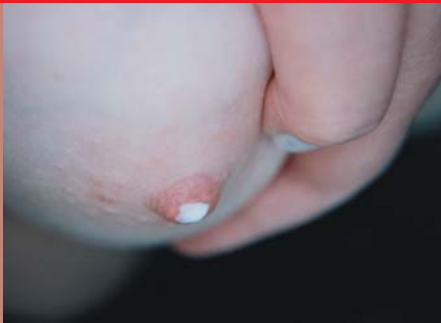## Question 3

What are the typical features on fundal examination?

## Question 4

What is the management of this patient?

## ANSWERS TO NOVEMBER BRAIN TEASER



### Answer 1

Galactorrhoea is defined as lactation in the absence of an appropriate physiological stimulus.

### Answer 2

Galactorrhoea can be associated with:

- hyperprolactinaemia
- hypothyroidism
- drugs (eg. chlorpromazine).

(Primary hypothyroidism was the cause in this patient).

### Answer 3

Initial investigations include serum prolactin (looking for hyperprolactinaemia) and thyroid stimulating hormone (elevated in hypothyroidism).

Send your answers to arrive by 7 January. A prize of 12 months subscription to 'eTG complete' valued at \$240 will be donated by Therapeutic Guidelines Ltd to the first correct entry drawn. The winner will be notified by mail and the answers published in the January/February issue.



Therapeutic Guidelines

Freecall 1800 061 260

Email entries to: [afp@racgp.org.au](mailto:afp@racgp.org.au)

OR mail to:

December Brain Teaser  
 Australian Family Physician  
 1 Palmerston Crescent  
 South Melbourne  
 Victoria 3205

The winner of the November Brain teaser is  
 Dr Say Poh Eng, Kuraby, Qld