



# Back pain – clinical assessment

**BACKGROUND** Low back pain accounts for approximately 5% of all general practice consultations. Although the majority of patients will have somatic low back pain of musculoskeletal origin, vigilance in excluding 'red flag' conditions is paramount. The identification of 'yellow flags', ie. psychosocial stress factors, becomes important in patients not making a rapid recovery, and these factors need to be identified and rectified early, lest they lead to chronic pain and disability.

**OBJECTIVE** This article presents a simple examination of the lower back designed with general practice in mind. It is based on the 'look, move, feel' paradigm of clinical orthopaedic examination.

**DISCUSSION** A thorough and conscientious physical examination is not time consuming. It reassures the patient that the practitioner is interested and concerned about their problem. In acute low back pain, this is the springboard to a simple effective management program and improved outcomes. It also confirms the site of pain, and is important in monitoring disability. However, there are no clinical signs, either singly or in multiples, which allow a valid anatomicopathological diagnosis to be made.

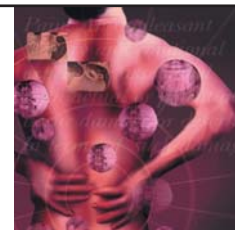
Low back pain (LBP) has reached endemic proportions in western societies. Epidemiological studies report a lifetime prevalence of between 60–80%, with a tendency for it to run a prolonged or relapsing course.<sup>1,2</sup> In Australia, of the 83% of the population who reported long term health problems, 21% suffered from back and disc problems.<sup>3</sup> A general practice survey in Australia found back pain to be one of the most common reasons for encounter with a general practitioner.<sup>4</sup>

A thorough clinical assessment of LBP need not consume excessive time, and can instil in the GP confidence that serious 'red flag' conditions are not being missed. Properly recorded, the clinical assessment should also guard against the ever increasing threat of medical negligence, as well as enabling progress in terms of pain and disability to be accurately monitored.

Such an assessment and clinical approach to management has been shown to obviate the need for excessive and unwarranted investigations, lead to a lower use of pharmaceutical agents (with their potential adverse effects) and alternative treatments, and result in less patients going on to develop chronic LBP (CLBP).<sup>5</sup>

This is despite the fact that examination findings lack strong inter-observer reliability. Also, there are no specific findings, either singly or in multiples, that enable the clinician to make a definitive anatomicopathological diagnosis. However, such accuracy in diagnosis is not necessary in the overwhelming majority of those presenting with LBP. The International Association for the Study of Pain (IASP) have coined the termed 'low back pain of undetermined origin' or 'somatic low back pain' as a diagnostic label for such patients.<sup>6</sup>

Radicular pain is a different clinical problem requiring a different clinical assessment and is covered elsewhere in this issue (see the article *Radicular pain* by Jay Govind page 409 this issue).



**Steve Jensen,**

MBBS, FAFMM, is Senior Lecturer in Musculoskeletal Medicine, Swinburne University of Technology Graduate School of Integrative Medicine, Victoria, Past President, Australian Association of Musculoskeletal Medicine, and a musculoskeletal physician, Footscray, Victoria.

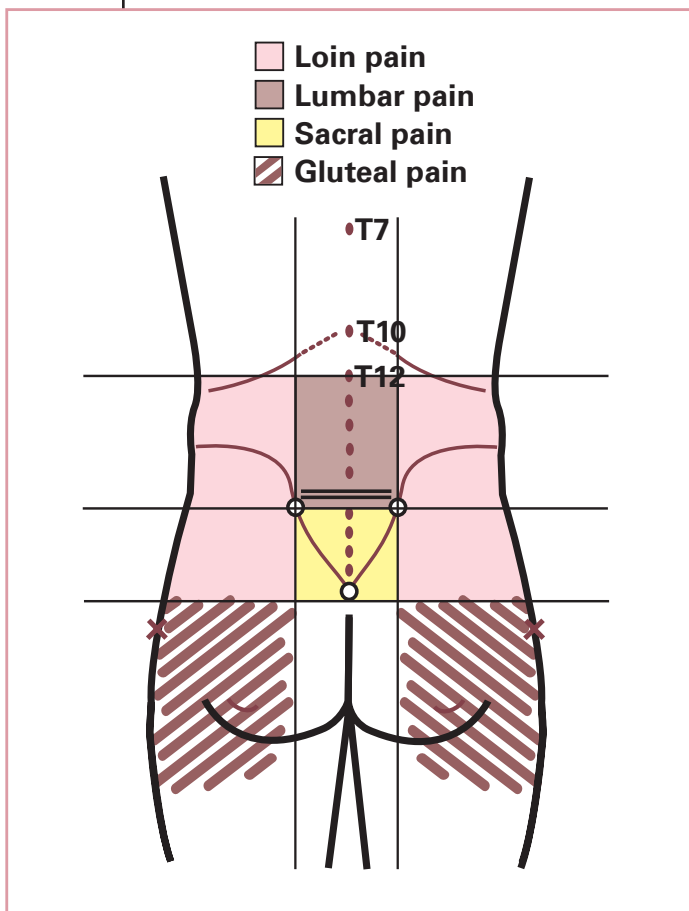


Figure 1. Site of pain as defined by the IASP

## Definition

### Site

What is meant by the term 'back pain'? The IASP have delineated anatomical borders to differentiate between lumbar, sacral and lumbosacral spinal pain. This needs to be differentiated from loin, groin and gluteal pain (Figure 1).<sup>6</sup> In the author's experience, patients often present with what they term 'hip pain', when in fact their pain can be more accurately categorised as lumbosacral or gluteal pain. Pain diagrams, in which the patient marks the site of their pain on a whole body diagram, can be very useful at delineating and recording which category a patient's pain falls within.

### Length of illness

By definition, the terms 'acute' and 'chronic' pertain only to the duration of pain. Acute pain is pain lasting less than 3 months, while chronic pain is that lasting longer than 3 months. A further category of 'subacute' pain has been devised for pain of between 5 weeks and 3 months duration.<sup>7</sup>

### Pain history

## Table 1. Taking a pain history<sup>9</sup>

- Circumstances associated with pain onset
- Primary site of pain
- Radiation of pain
- Character of pain (eg. is pain throbbing, sharp, aching)
- Intensity of pain (eg. on visual analogue scale)
  - at rest
  - on movement
  - at present
  - during past week
  - highest level
- Factors altering pain
  - what makes it worse?
  - what makes it better?
- Associated symptoms (eg. nausea)
- Temporal factors
  - is pain present continuously or otherwise?
- Effect of pain on activities
- Effect of pain on sleep
- Medications taken for pain
- Other treatments used for pain
- Health professionals consulted for pain treatment

### Pain history information of significance for symptomatic treatment of pain

- Expectations of outcome of pain treatment
- Patient's belief concerning the causes of pain
- Reduction in pain required to resume reasonable activities
- Patient's typical coping response for stress or pain, including presence of anxiety or psychiatric disorders (eg. depression or psychosis)
- Family expectations and beliefs about pain, stress and postoperative course
- Ways the patient describes or shows pain
- Patient's knowledge, expectations and preferences for pain treatment

The clinical history is no different to that required for any patient presenting with pain in any anatomical region (Table 1). Particular attention needs to be paid to the red flag indicators, which, although thankfully rare, should not be missed. A simple but comprehensive check list requiring a tick or cross for red flag indicators can be inserted into the patient history (Table 2). If the

Table 2. Check list for red flag indicators

Name:		<b>Low back pain</b>	
DOB:		MRN	
<b>Presence of</b>		<b>Cardiovascular</b>	<b>Endocrine</b>
Trauma	Y N	Risk factors	Corticosteroids
Night sweats	Y N	<b>Respiratory</b>	<b>Musculoskeletal</b>
Recent surgery	Y N	Cough	Pain elsewhere
Catheterisation	Y N	<b>Urinary</b>	<b>Neurological</b>
Venipuncture	Y N	UTI	Symptoms/signs
Occupational exposure	Y N	Haematuria	<b>Skin</b>
Hobby exposure	Y N	Retention	Infections
Sporting exposure	Y N	Stream problems	Rashes
(Overseas) travel	Y N	<b>Reproductive</b>	<b>GIT</b>
Illicit drug use	Y N	Menstrual problems	Diarrhoea
Weight loss	Y N	<b>Haematopoietic</b>	
History of cancer	Y N	Problems	
<b>Comments</b>		<b>Signature:</b>	
Source: Bogduk N. National Musculoskeletal Medicine Initiative. Evidence based clinical practice guidelines for the management of acute low back pain. CD-ROM Medseed Compass			

Table 3. Check list for yellow flag indicators

<p><b>Work</b></p> <ul style="list-style-type: none"> <li>• belief that pain is harmful, resulting in fear avoidance behaviour</li> <li>• belief that all pain must be abolished before attempting to return to work or normal activity</li> <li>• expectation of increased pain with activity or work</li> <li>• fear of increased pain with activity or work</li> <li>• belief that work is harmful</li> <li>• poor work history</li> <li>• unsupportive work environment</li> </ul> <p><b>Beliefs</b></p> <ul style="list-style-type: none"> <li>• catastrophising, thinking the worst</li> <li>• misinterpreting bodily symptoms</li> <li>• belief that pain is uncontrollable</li> <li>• poor compliance with exercise</li> <li>• expectation of 'techno-fix' for pain</li> <li>• low educational background</li> </ul>	<p><b>Behaviours</b></p> <ul style="list-style-type: none"> <li>• passive attitude to rehabilitation</li> <li>• use of extended rest</li> <li>• reduced activity with significant withdrawal from activities of daily living</li> <li>• avoidance of normal activity</li> <li>• impaired sleep because of pain</li> <li>• increased intake of alcohol or similar substances since the onset of pain</li> </ul> <p><b>Affective</b></p> <ul style="list-style-type: none"> <li>• depression</li> <li>• feeling useless and not needed</li> <li>• irritability</li> <li>• anxiety about heightened body sensations</li> <li>• disinterest in social activity</li> <li>• over protective partner/spouse</li> <li>• socially punitive partner/spouse</li> <li>• lack of support to talk about problems</li> </ul>
Source: Bogduk N. National Musculoskeletal Medicine Initiative. Evidence based clinical practice guidelines for the management of acute low back pain. CD-ROM Medseed Compass	

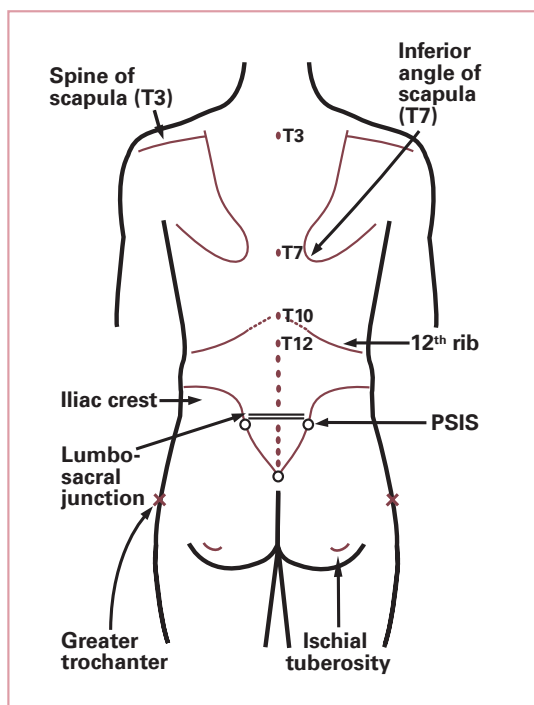


Figure 2. Surface anatomy landmarks: iliac crests (IC), posterior superior iliac spines (PSIS). Spinous process of L4 lumbar vertebra lies at or just below the level of the iliac crest.

Lumbosacral junction (=) lies 10–15° superiorly and toward the midline from the PSISs.

T12 can be located by counting spinous processes back from the lumbo-sacral junction. T10 is at a line drawn along the 12<sup>th</sup> rib and continued to the midline to meet its contralateral fellow

patient is well known to your practice, much of the background information such as past history, family history, smoking habit and medication history, will already be documented.

'Yellow flags' (Table 3) are those psychosocial variables that, when present in multiples, are associated with a poor prognosis in terms of pain and related disability. They need to be identified and dealt with early and appropriately to minimise the risk of this occurring.<sup>8</sup> A more detailed description of taking a history for back pain is available elsewhere in the literature.<sup>7,9</sup>

## Physical examination

Current musculoskeletal medicine teaching implores the clinician to reproduce the patient's pain during the musculoskeletal examination, leading to the conclusion that the pain is very likely musculoskeletal in origin. An examination bereft of such symptom reproduction is an indicator to search for nonmusculoskeletal causes and red flag conditions.

Convention dictates that the orthopaedic paradigm of:

- inspection – 'look'
- movement 'move', and
- palpation 'feel'

should be utilised in such an examination. While this process allows a description of the patient, current best evidence is that no particular clinical sign or combination of clinical signs elicited on physical examination allows any valid anatomical or pathological diagnosis to be applied. Nor do they offer any predictive value in terms of treatment.<sup>2,10</sup> There is also only relatively weak agreement between the results of physical examination and the subjective reporting of the severity of pain and disability.<sup>11</sup>

Nonetheless, it has been shown that such an examination does instil confidence in the patient, from which a simple yet effective and evidence based management plan can be invoked by an equally confident GP (see the article *Acute low back pain* by Victor Wilk page 403 this issue).<sup>5</sup> Furthermore, it does provide some objectivity in terms of patient progress. One would expect the clinical findings to objectively improve as the patient's pain and level of disability subjectively improve. This improvement can then be utilised in subsequent visits to instil further confidence in the patient that positive progress is being made.

As with any thorough clinical examination, certain requirements need to be met. These include being systematic, having the necessary equipment such as a couch that can be accessed from all sides (and preferably adjustable in height), having aesthetically pleasant surroundings, and exposing the area to be examined sufficiently – yet discreetly – to ensure that patient comfort is optimal.

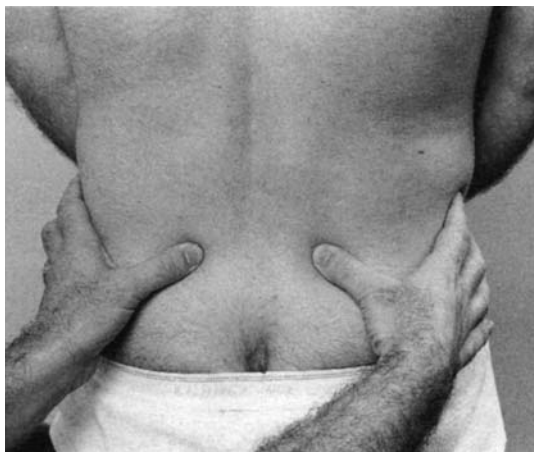## Surface anatomy landmarks

The first part of any examination is to know the surface anatomy pertaining to the region to be examined. The important surface landmarks for the lumbosacral region are demonstrated in Figure 2.

## Functional tests

The examination begins by observing the patient in the waiting room and then watching their gait and general demeanour as they make their way into the consulting room. For example, slow guarded movements and much groaning and holding of the back is representative of abnormal illness behaviour, or a rare red flag disorder.

Commencing the examination with functional tests also aids in assessing the general behaviour of the patient,



**Figure 3.** Assessment of the level of the iliac crests. The iliac crests are palpated from the sides by sliding the hands down from the waist creases. The hands can then be slid posteriorly, following the iliac crests to the posterior superior iliac spines. Note is taken of any asymmetry  
© Elsevier Australia. Reprinted with permission

as well as providing a screening neurological assessment. These include walking on toes (predominantly an S1 nerve root function), and walking on heels (predominantly L5), as well as getting down to and rising from the squatted position or a low chair or couch, marking time, walking heel-to-toe and balancing on one leg.

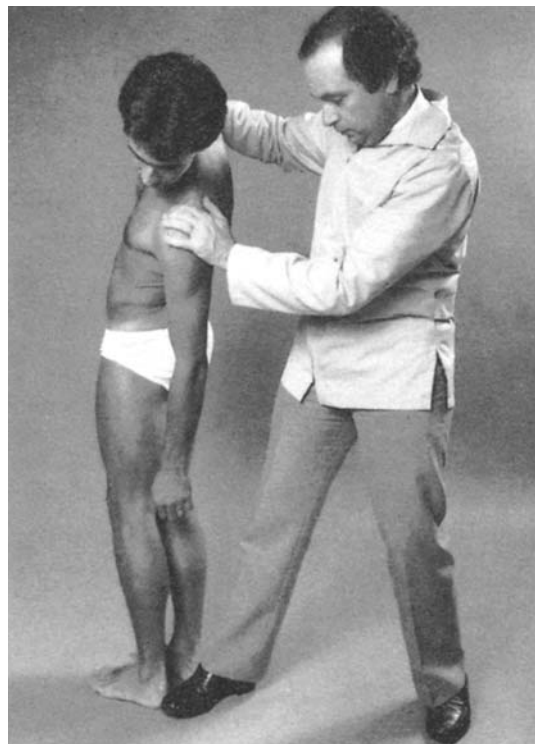
### Inspection

The patient is observed in standing from the front, back and sides for body habitus, as well as any asymmetry of posture, spinal curves, or muscle bulk, or abnormalities on the skin. The level of the iliac crests is then assessed (*Figure 3*) and note taken of any asymmetry, which may indicate leg length inequality, a pelvic rotation, a thoraco-lumbar scoliosis or inequality in the size of the hemipelvis.

### Movement

Detection of gross limitations of movement, and pain on gross movement, generally have at least moderate inter-observer reliability.<sup>2,5,12</sup> When assessing movement, not only the range should be observed and recorded, but any disturbance of the cadence or rhythm of motion. Deviation to one side during flexion or extension is said to be (but has not been proven) a sign of either subtle lumbosacral instability or a significant disc bulge or prolapse.

For recording, measurements of range of motion can be estimated in degrees, either by 'eye balling' and estimating, or with gadgets such as goniometers or inclinometers. Another way of recording range of



**Figure 4.** The lumbar quadrant test: the combined motion of extension, lateral flexion, and rotation, with axial loading, used in an attempt to reproduce the patient's pain, if not done so already  
© Elsevier Australia. Reprinted with permission

motion is relative to tips of fingers reaching anatomical markers in the lower limbs. For example, flexion in standing can be recorded relative to finger tips reaching the tibial tuberosity or malleoli; and for side bending relative to the superior or inferior pole of the patella.

The six cardinal planes of motion: flexion, extension, lateral flexion bilaterally and rotation bilaterally are tested. For rotation, the hips need to be stabilised to exclude motion of the pelvis, either by the examiner holding the hips, or by testing in the seated position. If reproduction of pain has not occurred with these routine movements, then overpressure by the examiner in each plane can be used to further stress the spinal column. The quadrant test, (the combined motion of extension, rotation and lateral flexion), is another provocative test used if pain reproduction has still not occurred (*Figure 4*).

The patient is then seated on the edge of the examination couch. Straight leg raise (SLR) in sitting is tested first. The slump test (*Figure 5*), which is said to be a sign of neuromeningeal irritation, can be added if pain reproduction has not occurred with the sitting SLR.

The patient then lies supine, where leg lengths can

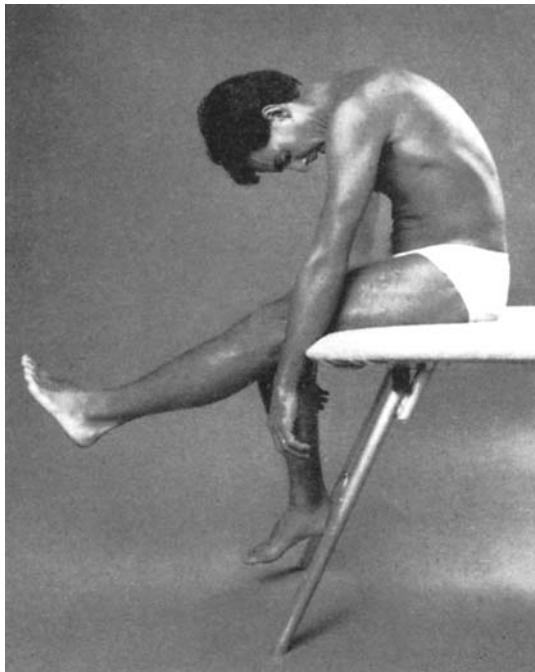


Figure 5. Slump test: the patient sits on the edge of the couch, then in a stepwise fashion, increased stretch is introduced as follows: a) the patient slumps forward, b) then flexes the neck, c) then straightens the leg, d) then dorsiflexes the foot. Purportedly, if any back or leg pain reproduced so far is eased when the neck is then extended, and/or the ankle plantar flexed, then neuromeningeal irritation, rather than hamstring pain, is invoked  
© Elsevier Australia. Reprinted with permission

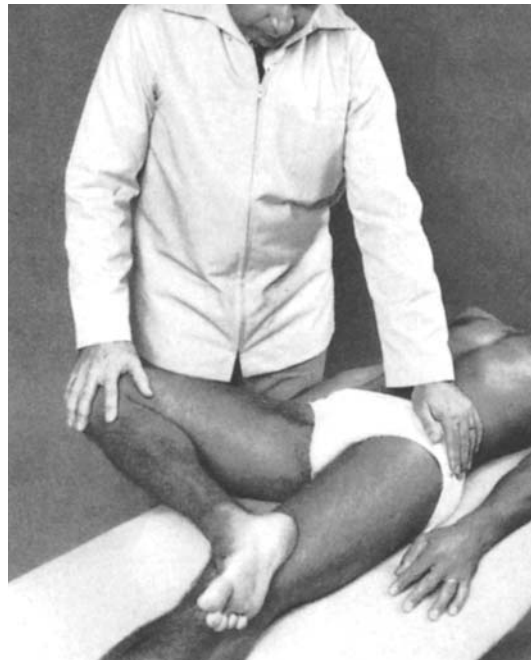


Figure 6. The Faber, or Patrick test: the patient lies supine with the foot of the involved side on the opposite knee. The knee is allowed to move laterally which takes the hip into Flexion, ABduction, and External Rotation (FABER). In the normal hip, the leg should come to lie almost horizontal to the couch. Restriction and groin pain may be indicative of hip pathology. If there is more posterior pain such as in the back or buttocks, then the sacroiliac joint may be pathological  
© Elsevier Australia. Reprinted with permission

again be assessed and compared. The straight leg raise test, with and without dorsiflexion of the ankle, can also be assessed here.

Both the slump test, and SLR with enhancement by dorsiflexion of the ankle, can purportedly differentiate between neuromeningeal irritation or hamstring tightness as a source of any leg pain. Neck flexion in the slump test, and ankle dorsiflexion in SLR should make no difference to any back or leg pain in cases of hamstring tightness or pain, but would tend to increase pain in cases of neuromeningeal irritation.

A screening of hip motion can then be undertaken. Restriction of hip flexion that produces discomfort in the back and/or buttock, rather than the groin, may be due to stiffness in the lumbar spine, and/or shortening of buttock muscles and not due to hip pathology.

While lying supine further provocative tests purportedly of the sacroiliac joint function, namely the FABER (Figure 6) and the FADLong (Figure 7) tests are performed.

## Palpation

The patient is then asked to lie prone. A pillow placed under the abdomen is often more comfort-

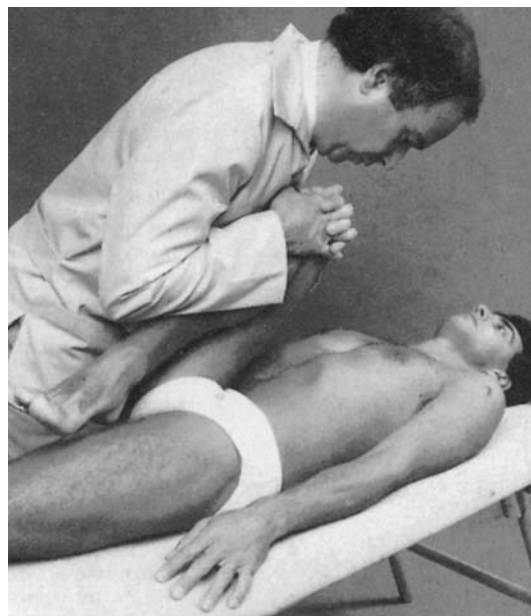


Figure 7. FADLong test: the patient's hip is Flexed and the knee ADducted toward the contralateral shoulder, a Longitudinal load is then applied along the line of the shaft of the femur. Reproduction of buttock or back pain is an indication of sacroiliac joint dysfunction  
© Elsevier Australia. Reprinted with permission

**Table 4. Nonorganic signs of LBP<sup>13</sup>**

- Widespread 'nonanatomical' tenderness and/or superficial tenderness
- Back pain on simulated tests for axial loading
- Back pain on simulated rotation of the hips
- Straight leg raise improves with distraction
- Regional sensory changes (nondermatomal)
- Regional weakness (jerky, give way weakness in nonanatomical distribution)
- Over reaction during examination (overt pain behaviour, eg. crying out, exaggerated responses)

able and allows for maximal relaxation of lumbar paraspinal muscles. A gentle palpatory screen is first undertaken to gauge the degree and location of any muscle spasm, as well as changes in skin texture.

A systematic approach to further palpation is then undertaken. Palpation over each of the spinous processes (*Figure 8*), and then unilaterally on each side (*Figure 9*) is performed, looking for underlying intervertebral segmental stiffness, tenderness and pain reproduction. Systematic palpation of each segment from the thoracolumbar junction to the lumbosacral junction should be performed. Palpation around the sacrum and buttock completes the examination.

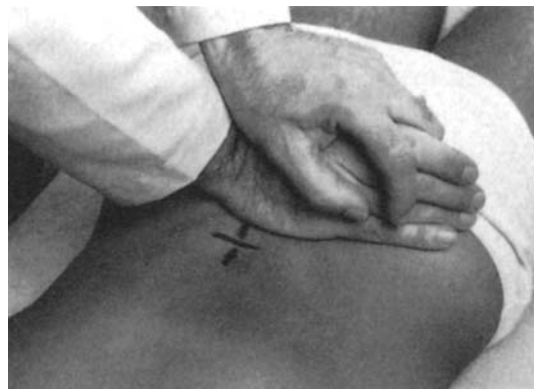It should be remembered that low back pain can be referred from the thoracolumbar junction, and that sacroiliac joint dysfunction can also be a cause of LBP.

Studies have shown that there is excellent reliability for the finding of tenderness somewhere in the lumbar spine in patients with LBP. However, the more specific the location of tenderness is cited, the poorer the inter-observer reliability. This includes the reliability of myofascial trigger points, which themselves have relatively poor inter-observer reliability.<sup>2</sup>

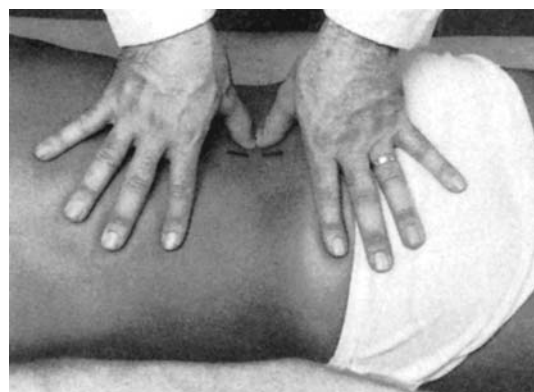### Nonorganic signs

Waddell<sup>13</sup> reported a number of 'nonorganic' clinical signs that suggest the presence of significant psychosocial distress in a patient presenting with LBP (*Table 4*). These are not signs of malingering. They are, however, indicators of a poor prognosis. A patient with nonorganic signs needs plenty of reassurance, which can be given during a careful, caring examination. This is a vitally important role for the GP. For example, during and after the examination, the patient can be reassured that there is no serious damage done, and that there is no neurological abnormality.

### Neurological examination



**Figure 8. Palpation of the L5 spinous process using the pisiform prominence of the hand**  
© Elsevier Australia. Reprinted with permission



**Figure 9. Palpation unilaterally, using the tips of the thumbs**  
© Elsevier Australia. Reprinted with permission

Neurological examination is only required if the patient has radicular leg pain, or if the history suggests neurological symptoms such as paraesthesia, weakness, or sphincter dysfunction (see the article *Radicular pain* by Jay Govind page 409 this issue).

### Conclusion

Although the scientific reliability and validity of clinical signs in the lower back is lacking, a careful, confident, caring and systematic approach to the clinical assessment of patient's presenting with LBP can be undertaken within the time constraints of a busy general practice. This has the potential to be of great therapeutic benefit in its own right. Furthermore, it can lead to an evidence based, simple, safe and economical management plan, resulting in an improved long term prognosis. It will also ensure that any of the rare, but potentially serious causes of low back pain will not be overlooked.

### Summary of important points

- A thorough clinical assessment of the patient presenting with LBP is an important stepping stone to patient reassurance and a proven simple and effective GP controlled management plan. It can also alert the GP to any 'red flag' conditions.
- Pain diagrams can be a useful tool at delineating and recording which category a patient's pain falls within.
- Reproducing the patient's pain during examination is essential in determining whether the pain is musculoskeletal.
- The paradigm of 'look, move, feel' should be utilised in the examination.
- The patient with nonorganic signs needs plenty of reassurance, which can be given during a careful, caring examination.

Conflict of interest: none declared.

### References

1. Waddell G. The back pain revolution. Ch 5. London: Churchill Livingstone, 1998.
2. Bogduk N, McGuirk B. Medical management of acute and chronic low back pain. An evidence based approach. Ch 4. Amsterdam: Elsevier, 2002.
3. Australian Bureau of Statistics. Canberra: National Health Survey, 2001.
4. Britt H, Miller GC, Knox S, et al. General practice activity in Australia 2002-2003. Australian Centre for Evidence Based Clinical Practice. Available at: [www.acebcp.org.au](http://www.acebcp.org.au).
5. McGuirk B, King W, Govind J, Lowry J, Bogduk N. Safety, efficacy, and cost effectiveness of evidence based guidelines for the management of acute low back pain in primary care. *Spine* 2001;26:2615-2622.
6. Merskey H, Bogduk N, eds. Classification of chronic pain. Descriptions of chronic pain syndromes and definitions of pain terms. 2nd edn. Seattle: IASP Press, 1994;178-186.
7. Bogduk N. Taking a history of back pain. *Australasian Musculoskeletal Medicine* 2000;5:14-19.
8. New Zealand Guidelines Group. Guide to assessing psychosocial yellow flags in acute low back pain: risk factors for long term disability and work loss. Auckland, New Zealand: 1998.
9. National Health and Medical Research Council (NHMRC). Acute pain management: information for general practitioners. Commonwealth of Australia, 1999;7-10.
10. Australian Acute Musculoskeletal Pain Guidelines Group. Evidence based management of acute musculoskeletal pain. National Health and Medical Research Council (NHMRC), 2003.
11. Michel A, Kohlmann T, Raspe H. The association between clinical findings on physical examination and self reported severity in back pain. *Spine* 1997;22:296-304.
12. Yelland MJ. The effects of a brief training intervention on the reliability of lumbar spinal signs. *Australasian Musculoskeletal Medicine* 2001;6:55-58.
13. Waddell G, McCulloch JA, Kummell E, Venner RM. Nonorganic physical signs in low back pain. *Spine* 1980;5:117-125.

### Resources

Murtagh J, Kenna C. Back pain and spinal manipulation. A practical guide, 2nd edn. Oxford: Butterworth-Heinemann Medical, 1997.  
 Bogduk N, McGuirk B. Medical management of acute and chronic low back pain. An evidence based approach. Amsterdam: Elsevier, 2002.

The author suggests attending practical hands-on workshops such as those run by the Australian Association of Musculoskeletal Medicine. Email: [webmaster@musmed.com](mailto:webmaster@musmed.com) for details.

Email: [jensen@tpg.com.au](mailto:jensen@tpg.com.au)

AFP