

# Marine envenomations

## Part 1 – Jellyfish

**BACKGROUND** Many venomous marine creatures inhabit Australian waters, causing significant morbidity and occasional fatalities. Part 1 of this article looks at jellyfish envenomations, an important overall cause of marine injuries.

**OBJECTIVE** To discuss the features of envenomation by some of the more commonly encountered jellyfish of medical significance, and the recommended first aid and medical management of such envenomations.

**DISCUSSION** It is intended that the information contained in this article will be informative to general practitioners dealing with jellyfish stings throughout Australia. Much of what we know has come from the astute observations of GPs in tropical Australia. However, there remains a lot to be learnt about jellyfish envenomation.

Australian waters contain a great variety of venomous creatures including jellyfish, stinging fish, blue-ringed octopus, sea snakes, cone snails and stingrays. Jellyfish stings are probably the most common of the medically significant venomous marine creatures. It is estimated that in excess of 10 000 jellyfish stings occur in Australia each year.

### Box jellyfish (*Chironex fleckeri*)

The box jellyfish, (*Chironex fleckeri*) (Figure 1) is the most dangerous jellyfish and arguably the most dangerous venomous creature in the world. There have been at least 67 deaths attributed to box jellyfish in the Indo-Pacific region. The two most recent Australian fatalities were both in North Queensland – in 2000 a five year old boy,<sup>1</sup> in 2003 a seven year old boy.<sup>2</sup> The box jellyfish is found in coastal waters of northern Australia, from Gladstone in Queensland to Broome in Western Australia, but not on the Great Barrier Reef. It is a large jellyfish, weighing up to 6 kg and measuring about 20–30 cm across the bell. It is also transparent in the water and therefore difficult to see. It has four bundles of tentacles – which may number up to 60 in total – stretching up to 3 m. Each tentacle contains millions of nematocysts (or stinging cells) that discharge venom into the skin on contact. Thus, contact with a large amount of ten-

tacular material over a wide surface area can result in massive envenomation (Figure 2). Barnes<sup>3</sup> asserted that death was probable (without treatment) if the total length of weals on the victim measured more than 6–7 m, but severe envenomation and death are possible with much less contact. Stings are more common during the summer months (September to May), although they have been reported all year round. Most stings occur in shallow water near the beach and are particularly common in children. In a study of 40 patients presenting to the Royal Darwin Hospital, eight were under the age of 15 years (median 21 years).<sup>4</sup> Precautions that should be taken to avoid potentially fatal box jellyfish envenomation are summarised in Table 1.

Most stings are minor, resulting in sting site pain and skin changes, however death can occur within five minutes following massive envenomation. The mechanism(s) of toxicity are poorly understood, but death is thought to be due to respiratory failure, possibly central in origin, or to direct cardiotoxicity leading to A–V conduction disturbances or to paralysis of the cardiac muscle in systole.<sup>5</sup> Patients may become unconscious before they can leave the water. In addition to cardiotoxic and neurotoxic properties, the venom also contains dermatonecrotic components producing patches of full thickness skin necrosis that result in

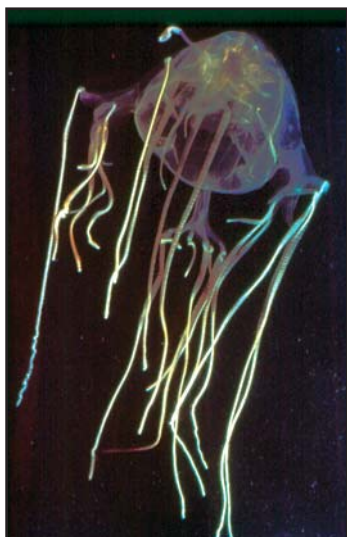
**B Nimorakiotakis,  
K D Winkel**



*B Nimorakiotakis, MBBS, FACEM, is Staff Specialist, Epworth Hospital, and Fellow, The Australian Venom Research Unit, Department of Pharmacology, the University of Melbourne, Victoria.*



*K D Winkel, MBBS, BMedSc, PhD, FACTM, is Director, The Australian Venom Research Unit, Department of Pharmacology, the University of Melbourne, Victoria, and President elect, the Australasian College of Tropical Medicine.*



**Figure 1. Box jellyfish (Chironex fleckeri)**

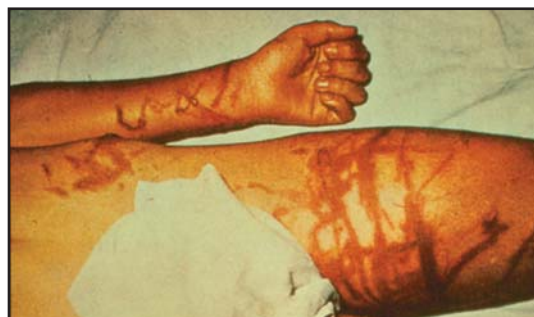severe and permanent scarring. There is also a haemolytic component in box jellyfish venom, although it is of doubtful clinical significance.

### Symptoms and signs of box jellyfish envenomation

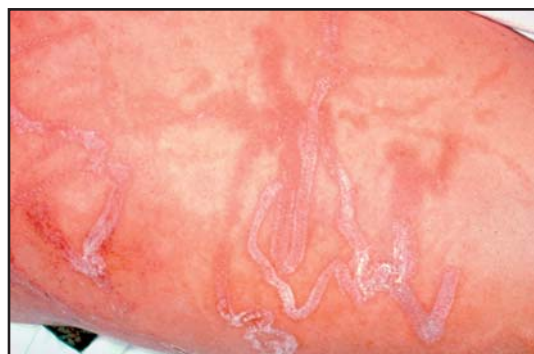- Severe localised pain, often associated with vigorous attempts by the patient to remove the tentacles (this may worsen envenomation by causing the discharge of further nematocysts)
- Pain increasing over about 15 minutes even after the removal of tentacles
- Wide (0.5–1.0 cm) erythematous lines where the tentacles have been in contact with the skin (Figure 3). Total area of skin involvement may provide an indication to sting severity
- Difficulty breathing (hypoventilation), swallowing or speaking
- Unconsciousness, hypotension, dysrhythmia and cardiopulmonary arrest.

### First aid and treatment

- Remove victim from the water once it is safe to do so
- If in cardiopulmonary arrest, attend to airway, breathing and circulation (ABCs)
- If tentacles are attached, douse area with vinegar for at least 30 seconds to inactivate remaining nematocysts before removing them
- Current Australian Resuscitation Council guidelines recommend pressure immobilisation should not be applied if it interferes with or



**Figure 2. Box jellyfish (Chironex fleckeri) massive envenomation**  
Photo courtesy of Dr J Barn



**Figure 3. Erythematous lines from box jellyfish tentacle contact**  
Photo courtesy of Dr J Williamson

delays basic life support.<sup>6</sup> (This is a controversial area still subject to further study)

- Call for help (Queensland paramedics routinely carry antivenom in endemic areas)
- Analgesia (opiates such as morphine or pethidine).

### Antivenom

Antivenom may need to be administered by life-savers or other paramedical personnel at the scene. For this reason, antivenom may be given intramuscularly, although the intravenous route is preferable if appropriately skilled personnel are available. The antivenom (produced by CSL Ltd, Australia), which has been available since 1970, consists of purified sheep immunoglobulin and no significant adverse reactions have been reported following its use in over 100 cases (except for one case of generalised rash). Its efficacy has been established by in vitro neutralisation and subsequent protection of experimental animals. Indications for box jellyfish antivenom include:

- cardiorespiratory arrest or cardiac arrhythmias, and
- difficulty with breathing, speech, or swallowing, and severe pain.

According to CSL recommendations, an initial

### Table 1. How to avoid box jellyfish envenomation

- Don't swim at northern Australian beaches during 'jellyfish season' (variable, but usually September to May)
- Heed warning signs on beaches and advice from 'locals'
- Don't swim alone or at remote beaches
- Wear specially designed 'stinger suits' in known box jellyfish waters
- Swim at beaches patrolled by lifesavers, preferably equipped with vinegar, antivenom and basic resuscitation facilities
- Use caution on entering the water (do not dive or run into the water)
- Strictly supervise children (they are more vulnerable to stings)
- Swim at beaches with 'nets' to exclude box jellyfish (this will not prevent Irukandji stings, as these animals are much smaller than box jellyfish and can fit through gaps in nets)

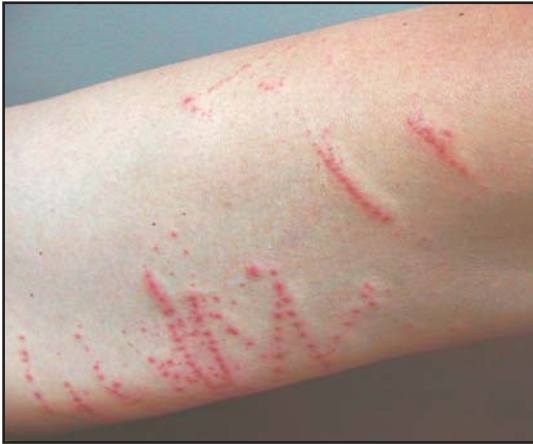

Figure 4. Delayed hypersensitivity reaction



Figure 5. Irukandji jellyfish (*Carukia barnesi*)

dose of one ampoule is required if given by the intravenous route or three ampoules are required if given by the intramuscular route.

#### **Dermonecrosis and delayed cutaneous hypersensitivity reactions**

Dermonecrosis is commonly seen with a box jellyfish sting. No animal or human clinical data has identified any agent to reduce long term scarring. There are some case reports of acute and long term improvement if intravenous antivenom is used but good evidence for this is lacking. Areas affected should be treated in the same way as a burn. Delayed hypersensitivity reactions (Figure 4) occur in approximately 50% of cases and should be treated with corticosteroid cream and antihistamines.

#### **Chiropsalmus quadrigatus**

*Chiropsalmus quadrigatus* is closely related to, but smaller than, *Chironex fleckeri*. The bell measures up to 7 cm, and the number of tentacles seldom exceeds nine. Its venom also has lethal, derma-

tonecrotic and haemolytic properties in the same proportions as box jellyfish venom, but the stinging potential of *Chiropsalmus* is estimated to be only around 10% of that of box jellyfish, and no deaths have been reported. Scarring is usually minimal. Box jellyfish antivenom has been shown experimentally to neutralise the venom, but clinical experience is lacking.

#### **Irukandji syndrome (carybdeids)**

It has been postulated that a number of jellyfish can cause Irukandji syndrome. *Carukia barnesi* (Figure 5) is, however, the jellyfish conclusively known to do so. Irukandji is a small (~2 cm diameter bell) jellyfish responsible for an unusual and dramatic syndrome observed most commonly in North Queensland. Unlike box jellyfish, Irukandji are found both on and offshore. Divers and snorkellers are particularly at risk. Stings have been recorded from Bundaberg in Queensland to Broome in Western Australia, and a similar syndrome has been described elsewhere in the Pacific, even noted offshore of Florida. Approximately 160 people from North Queensland, including many international visitors, were hospitalised with this envenomation during the summer of 2001–2002, including two deaths. Both had intracerebral bleeds which were felt to be a result of hypertension caused by envenomation. It is important to note that one of the patients was on warfarin and the other had an arteriovenous malformation and therefore both were at higher risk of bleeding.<sup>7,8</sup>

#### **Symptoms and signs of Irukandji envenomation**

The syndrome has three recognised clinical forms or patterns consisting of:

- acute muscular chest and back pain
- catecholamine-like effects notably sweating, anxiety, nausea, vomiting, headache, tachycardia, potentially life threatening hypertension with supraventricular tachyarrhythmias, and
- cardiopulmonary decompensation.

Most patients present with milder, nonlife threatening symptoms including generalised pain, hypertension, nausea, vomiting and distress. About half require hospital admission and a small number need advanced life support, usually because of cardiac failure.<sup>9</sup> The mechanism of cardiac dysfunction is not well understood. A recent prospective study of 116 patients presenting to Cairns Base Hospital (Qld), found that no patient had clinical cardiac failure. Of these



Figure 6. Bluebottle/Portuguese man-o-war *Physalia* spp.  
Photo courtesy of Neal Saker

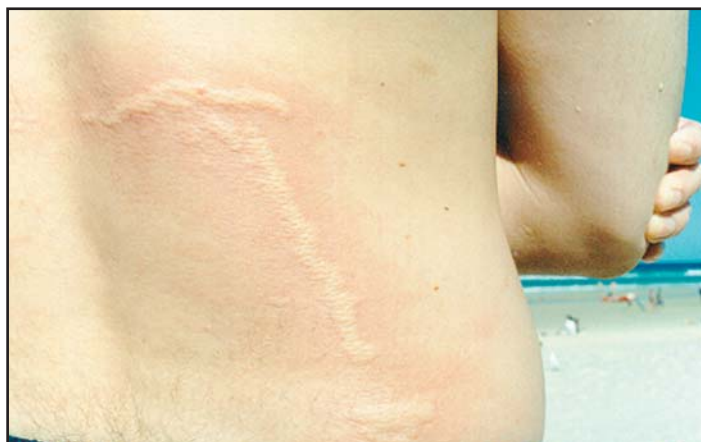

Figure 7. String of beads lesions from bluebottle envenomation  
Photo courtesy of Stephen Leahy

Table 2. Jellyfish type and features

Jellyfish type	Chirodropids	Irukandji	Morbakka or fire jellyfish	Bluebottle/ Portuguese man-o-war	Hairy stinger
	Chironex fleckeri Chiropsalmus quadrigatus	Carukia barnesi	Unidentified carybdeids	<i>Physalia</i> species	<i>Cyanea capillata</i>
<b>Characteristics</b>	Medium-large sized 'box' jellyfish, translucent, medusae may be large, up to 64 tentacles	Medusae very small (1–2 cm) and very rarely seen by the victim as they are also translucent, 4 tentacles only	Medium sized 'box' jellyfish, 4 tentacles only, translucent	Obvious blue bubble shaped floating sac with 1 or several attached tentacles	Large, slimy, 'a mop hiding under a dinner plate', variably coloured with numerous thin, translucent tentacles
<b>Sting site lesion</b>	Multiple wide erythematous lines with transverse bars, vesiculation and necrosis common	May be transient blistering associated with diffuse pale erythema, no necrosis	Raised red weals surrounded by red 'flare', may become itchy	String of beads skin lesions with discrete weals surrounded by erythema, variable width, single or replicated line, necrosis rare	Multiple thin zig-zag but parallel weals surrounded by pale erythema
<b>Sting site pain</b>	Immediate and severe persists (for up to 24 hours)	Mild, may be unnoticed, transient	Moderately severe, typically 'burning' in nature	Moderately severe for up to 2 hours	Transient mild 'burning' (usually less than 11 hours)
<b>Systemic features</b>	Only in severe cases; confusion, agitation, collapse with respiratory failure +/- cardiac arrest	Typically, after a delay of 30–45 minutes; nausea, vomiting, sweating, muscular pain, agitation, hypertension, tachycardia Less commonly cardiopulmonary decompensation	Uncommon; may cause throat 'tightness', cough and backache	Only with larger multitentacled species (except for allergic reactions); headaches, nausea, vomiting, abdominal pain and collapse	Uncommon; nausea, backache and abdominal pain
<b>Circumstances of sting</b>	Wading or swimming in coastal areas of northern Australia	Wading or swimming in coastal areas, snorkelling or diving offshore	Wading or swimming in coastal areas NB: seems to be seen in more southern waters than the box jellyfish	Wading or swimming in coastal areas; snorkelling offshore	On and offshore
<b>Antivenom</b>	Yes	No	No	No	No

patients, 25 had an elevated troponin level, and 18 had echocardiography with cardiac dysfunction noted in eight cases. The syndrome can last for hours to days. Unlike the box jellyfish sting, there is little local pain and tissue destruction.

### First aid and treatment

- No definitive first aid
- Analgesia and reassurance
- Vinegar
- The role of pressure immobilisation is unclear. Antihypertensives, such as phentolamine and glycerol trinitrate may be used, however, caution should be taken in patients with proven cardiac dysfunction. Acute pulmonary oedema should be treated in the usual manner with supplemental oxygen, inotropic support and positive pressure ventilation. Cardiac dysfunction is normally transient and generally returns to normal within 3–4 days. Magnesium has been postulated to be of advantage with a loading dose of 10 mmol followed by an infusion of 5 mmol per hour.<sup>10</sup> This has been used with good clinical effect and currently the subject of a prospective clinical trial. Box jellyfish antivenom does not appear to be useful for this syndrome.<sup>11,12</sup>

### Bluebottle jellyfish (*Physalia*)

The Portuguese man-o-war or bluebottle (*Physalia* spp.) (Figure 6) is well known throughout Australian waters (and the Pacific and Atlantic oceans) for causing painful stings. It is not a true jellyfish but a colony of individual organisms. No fatalities have been confirmed in Australia. The float measures 2–15 cm. The main or fishing tentacle may be up to 10 m long and is responsible for most stings. There are probably two species, of which the larger Atlantic specimens (*P. utriculus*) probably represents more of a threat to life. The venom contains lethal and haemolytic components and has been shown to produce nerve conduction disturbances, flaccid paralysis and smooth muscle contraction in experimental animals.<sup>13,14</sup>

### Symptoms and signs of bluebottle envenomation

- Pain is the most prominent feature, along with localised skin lesions with a ‘string of beads’ (Figure 7) appearance, discrete weals surrounded by erythema
- Systemic symptoms are uncommon but may

include headache, nausea and vomiting, abdominal pain and occasionally collapse.

### First aid and treatment

- Remove victim from the water to avoid further envenomation
- Remove the tentacles, preferably with forceps
- Vinegar is not recommended as it may cause discharge of nematocysts
- Cold packs or topical anaesthetic agents may be of use
- Analgesia (oral, intravenous or intramuscular)
- Box jellyfish antivenom is not useful.

The features of these jellyfish and other medically significant species are summarised in Table 2.

### Conclusion

As recreation in the marine environment increases, new jellyfish and new envenomation syndromes are likely to be encountered. However, management of all injuries is adherence to the principles of first aid, in particular to the patient’s airway breathing and circulation, inactivation of nematocysts, symptomatic relief and, where necessary, the use of specific treatments.

Conflict of interest: none declared.

#### SUMMARY OF IMPORTANT POINTS

- Box jellyfish stings can be rapidly fatal. Immediate treatment consists of topical vinegar to inactivate undischarged nematocysts, and antivenom ASAP for severe stings. Particular attention should be paid to ABCs.
- The use of pressure immobilisation for envenomation is currently not recommended for box jellyfish stings.
- Stings by the Irukandji jellyfish cause a potentially life threatening syndrome of abdominal, back and joint pain, hypertension and tachycardia and, occasionally, cardiopulmonary decompensation.
- Studies are currently underway as to the effectiveness of magnesium in the treatment of patients presenting with Irukandji syndrome.
- Most other jellyfish stings cause minor skin lesions and are associated with acutely painful stings requiring symptomatic management.

## References

1. Lill J. Fatal sting. Box jellyfish kills boy, 5. The Cairns Post 2000; January 25.
2. Gregory J, Edmiston L. Boy, 7, killed by jellyfish sting. The Courier Mail 2003; March 24.
3. Barnes J H. Studies on three venomous Cubomedusae. In: Rees W J, ed. The Cnidaria and their evolution. New York: Academic Press, 1966.
4. O'Reilly G M, Ibister G K, Lawrie P M, Treston G T, Currie B J. Prospective study of jellyfish stings from tropical Australia, including the major box jellyfish *Chironex fleckeri*. Med J Aust 2001; 175:652-665.
5. Bailey P M, Little M, Jelinek G A, Wilce J A. Jellyfish envenoming syndromes: unknown toxic mechanisms and unproven therapies. Med J Aust 2003; 178 (1):34-37.
6. Policy Document Australian Resuscitation Council 2003. Press Release 5th August 2002.
7. Fenner P J, Hadok J C. Fatal envenomation by jellyfish causing Irukandji syndrome. Med J Aust 2002; 177(7):326-363.
8. Dawson A H. Fatal envenomation by jellyfish causing Irukandji syndrome. Med J Aust 2003; 178(3):139.
9. Huynh T T, Seymour J, Preira P, Mulcahy R, Cullen P, Carrette T, Little M. Severity of Irukandji syndrome and nematocyst identification from skin scrapings. Med J Aust 2003; 178:38-41.
10. Corkeron M A. Magnesium infusion to treat Irukandji syndrome. Med J Aust 2003; 178(8):411.
11. Fenner P. The Irukandji syndrome. Aust Fam Physician 1999; 28(11):1131-1137.
12. Winkel K D, Hawdon G M, Fenner P J, Gershwin L, Collins A G, Tibballs J. Jellyfish antivenoms: Past, present and future. J Toxicol Toxin Rev 2003; 22(1):115-127.
13. Hawdon G. Hazardous marine creatures. Conn's Current Therapy 2001; 1179-1190.
14. Sutherland S K, Tibballs J. Australian animal toxins: The creatures, their toxins and the care of the poisoned patient. Melbourne: Oxford University Press, 2001; 570.

AFP

## CORRESPONDENCE

Email: [kdw@unimelb.edu.au](mailto:kdw@unimelb.edu.au)