

**Phillip Chang**

MBBS, is Visiting Medical Officer, St. Vincents Hospital and Sydney Children's Hospital, and Clinical Director, Shepherd Centre for Hearing Impaired Children, New South Wales. pchang@stvincents.com.au

Samuel Kim

MBBS, MMed, is Associate Clinical Lecturer, University of Sydney, New South Wales.

Cholesteatoma – diagnosing the unsafe ear

Background

Cholesteatoma represents the most common destructive disease of the ear, affecting the adult and paediatric population alike.

Objective

This article describes the pathogenesis of cholesteatoma and provides a guide to the examination and management of this common disease.

Discussion

Despite advances in surgery and imaging, the diagnosis of cholesteatoma is often delayed. A favourable outcome following treatment of a cholesteatoma rests in part on an early diagnosis, and in reducing significant complications and associated morbidity. Primary care physicians should maintain a high index of suspicion for the presence of cholesteatoma, awareness of otoscopic findings and promptly refer for investigations and management.

■ **Cholesteatoma is clinically defined as an abnormal extension of skin into the middle ear and mastoid air cell spaces. The point of entrance of skin into the middle ear is reliably identifiable on otoscopic examination as a perforation or retraction pocket of the tympanic membrane. Otoscopy therefore represents the most reliable and sensitive means of diagnosing a cholesteatoma.**

In pathological terms cholesteatoma is simply benign keratinising squamous epithelium that forms a cyst within the middle ear or mastoid. The term 'cholesteatoma', which arose in the 1800s when the lesion was mistakenly diagnosed as a 'pearly tumour of fat' due to its macroscopic appearance, is in fact a misnomer.

Once established the cholesteatoma exhibits independent growth and is locally destructive due to enzymes and acid produced by the skin. Although cholesteatoma is not a malignant lesion, its biological behaviour is associated with progressive local destruction of the bony and soft tissue structure within the temporal bone.

Cholesteatomas are associated with symptoms that are generally insidious and slowly progressive. Hearing loss and intermittent ear discharge are the most common early presentations. The early and definitive diagnosis of a cholesteatoma remains dependant on its identification on otoscopic examination. The more florid symptoms arising from facial nerve weakness, inner ear invasion and intracranial infection are late symptoms reflecting extensive and complicated disease.

Pathogenesis

Cholesteatoma are classified according to the presumed aetiology as being either:

- congenital, or
- acquired.

Most cholesteatomas in adults are acquired.

Congenital cholesteatomas are due to embryonal rests of epithelial cells persisting within the middle ear cleft. The average age of presentation for congenital cholesteatoma is 4.5 years with

a male preponderance of 3:1.¹ Most congenital cholesteatomas present as a spherical white mass in the anterosuperior quadrant of the middle ear and are seen behind an intact tympanic membrane (*Figure 1*). Persistent conductive hearing loss, despite the treatment of any associated middle ear fluid, is often the only symptom.

Acquired cholesteatomas occur as a result of a number of pathological processes. Most commonly acquired cholesteatomas result from a retraction pocket within the tympanic membrane as a result of underlying Eustachian tube dysfunction, often dating from early childhood.²

With long standing Eustachian tube dysfunction, the most flaccid portion of the tympanic membrane is retracted and forms a pocket. The two weakest and most vulnerable parts of the tympanic membrane are its most superior aspect and the posterosuperior quadrant (*Figure 2*). Within this retraction pocket the shed skin, or

keratin, accumulates and the sac slowly enlarges within the middle ear and mastoid air cell spaces (*Figure 3*).

Rarely cholesteatomas can arise due to the migration of skin cells through an established marginal tympanic membrane perforation or the inadvertent implantation of skin within the middle ear secondary to trauma or surgery.³ Replication of these cells over a number of years will result in a clinical cholesteatoma.

Cholesteatomas are locally destructive due to the fact that the skin produces proteolytic enzymes. In more than 30% of cases the first casualty of cholesteatoma are the ossicles of the middle ear.⁴ Usually the incus is the first ossicle to be eroded followed by the stapes (*Figure 4a*). As it extends deeper within the ear the facial nerve, cochlea and balance canals are affected. Particularly in children, extension of this bone destruction into the mastoid may result in a postauricular abscess associated with underlying mastoiditis (*Figure 5*).

Only once the cholesteatoma is extensive, is the tegmen threatened. The tegmen represents the bony plate that separates the middle ear and mastoid from the cranial cavity above. Once the tegmen is breached the risk of intracranial infection including meningitis and brain abscess formation increases dramatically (*Figure 4b*).³

Clinical presentation

History

As cholesteatoma is often related to longstanding Eustachian tube dysfunction, patients often have a history of childhood otitis media. There may be a history of multiple sets of ventilation tubes, which are considered in certain patients to be protective against

Figure 1. Congenital cholesteatoma (right ear) presenting as a discrete white mass behind an intact tympanic membrane

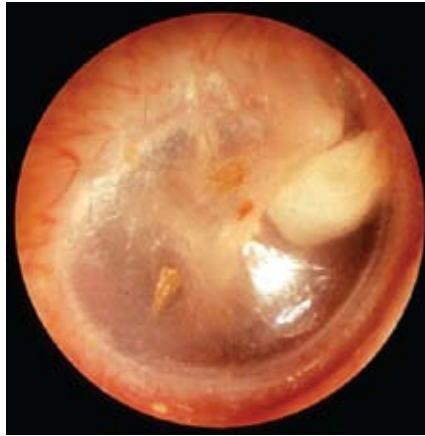

Figure 2. Classic locations for acquired cholesteatoma. The two parts of the tympanic membrane most vulnerable to retraction and therefore to the formation of a cholesteatoma are the most superior portion (A) and the posterosuperior quadrant (B)

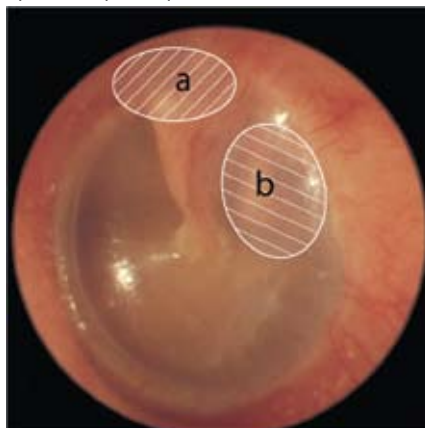
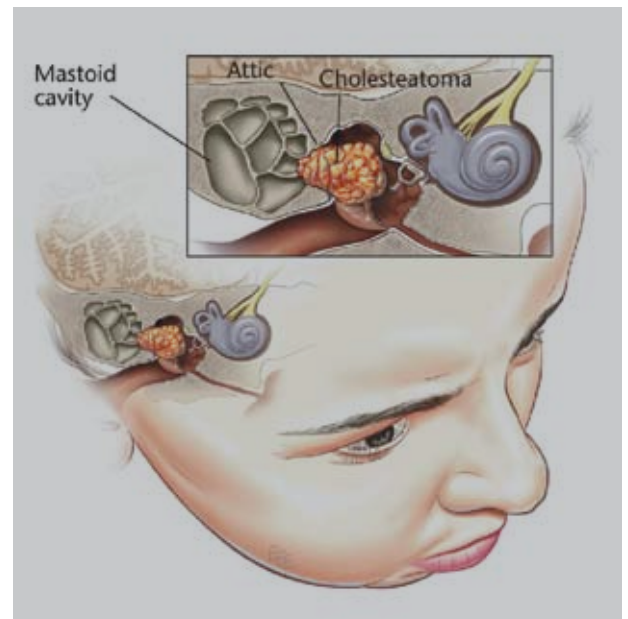


Figure 3. Formation of cholesteatoma. Often the appearance of the tympanic membrane remains unchanged, despite the progressive enlargement of the cholesteatoma



Reproduced with permission: Mi-tec Media Pty Ltd

the formation of cholesteatoma. Previous ventilation tubes do not necessarily guarantee that a cholesteatoma will not develop in adulthood.⁵ In addition, underlying conditions such as cleft palate and Down syndrome predispose to formation of the disease.⁶

A cholesteatoma in its initial stage is often asymptomatic but may be apparent on otoscopic examination. Once the cholesteatoma enlarges to engulf the underlying ossicles it is commonly associated with conductive hearing loss (*Table 1*). Hearing loss however, may be minimal despite the presence of a large cholesteatoma. This occurs because a large cholesteatoma

Figure 4a. Often the first casualty of the cholesteatoma is the ossicular chain. Involvement of the facial nerve and the inner ear may soon follow

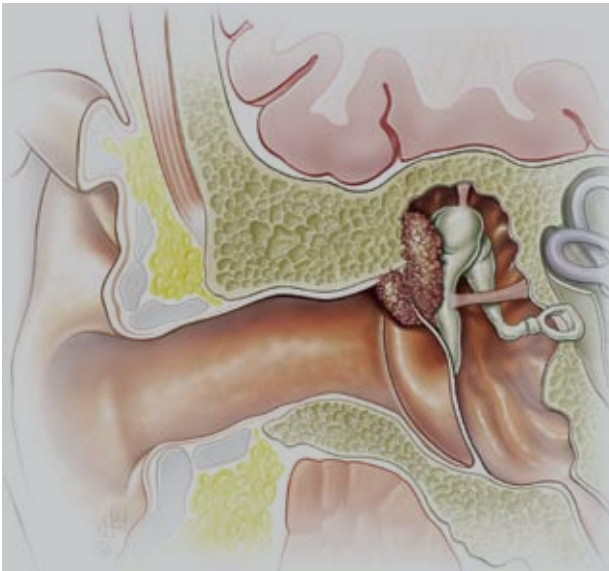


Figure 4b. Eventual involvement of the bony barrier between the middle ear and the cranial cavity results in the risk of developing intracranial infection

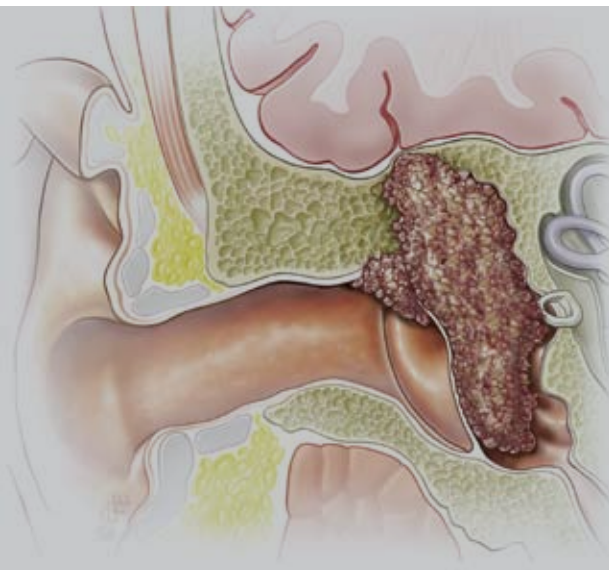

Figure 5. Postauricular abscess

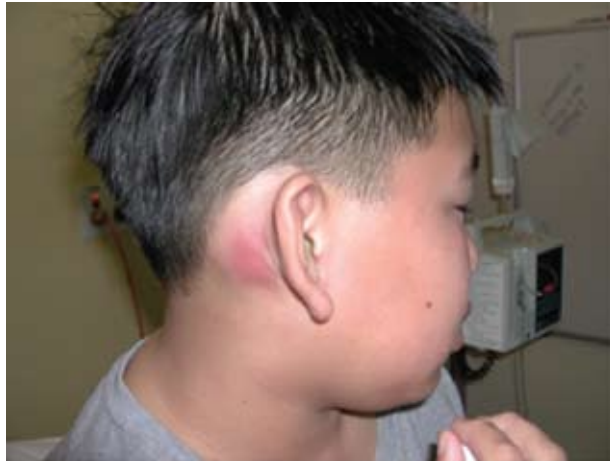

Table 1. Cholesteatoma presenting history (in order of most common)

- Conductive hearing loss
- Foul smelling ear discharge
- Persistent otitis media
- Otalgia
- Vertigo
- Facial weakness

sac may serve to transmit sound through the middle ear. Any sensorineural hearing loss indicates involvement of the inner ear either due to toxins or direct invasion.

Water within the ear can precipitate an acute infection of the cholesteatoma and results in otorrhea. In any patient with otitis media that fails to settle with appropriate antibiotic treatment, a cholesteatoma should be suspected.

A cholesteatoma is rarely associated with pain. Pain however reflects extensive disease with the possibility of intracranial invasion and dural irritation.⁷

Vertigo is also associated with an extensive cholesteatoma and requires urgent attention. Vestibular dysfunction suggests extension into the inner ear.⁷

Facial nerve twitching or weakness indicates that the facial nerve is involved by the cholesteatoma cyst.⁸ As the facial nerve courses through the middle ear and mastoid regions, the nerve is vulnerable to damage by cholesteatoma at multiple points. Recovery of facial nerve function is often possible with appropriate and prompt mastoid surgery. Steroids are given in the peri-operative period to facilitate recovery of the facial nerve.

Examination

Otосcopy is the most important means of evaluating the presence of a cholesteatoma. The ear should be examined in a systematic fashion and with optimal equipment.⁹

Figure 6a. Attic cholesteatoma involves the superior portion of the tympanic membrane; there is often obvious bone destruction of the adjacent bony ear canal

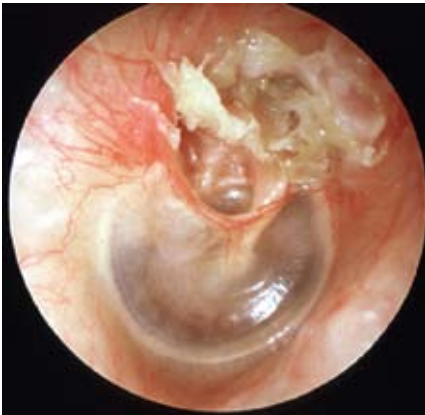

Figure 6b. Posterosuperior mesotympanic cholesteatoma is represented by a wide mouth retraction pocket. The retraction pocket involves the fibrous rim of the tympanic membrane

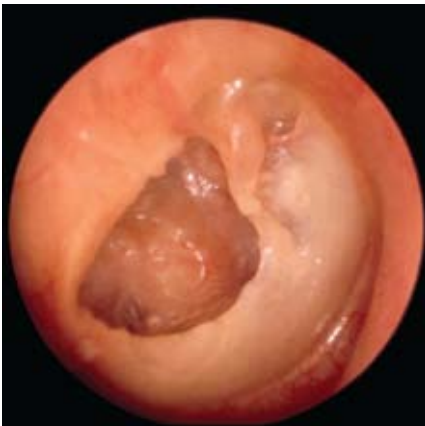
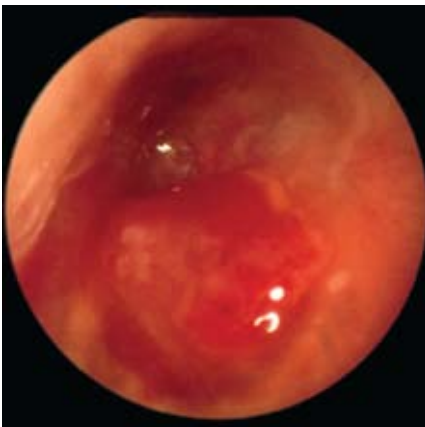
Figure 6c. A polyp of granulation tissue situated within the external auditory canal



A retraction pocket seen in the attic or posterosuperior quadrant of a tympanic membrane is the hallmark of an acquired cholesteatoma. Often there is an accumulation of squamous debris within the pocket (*Figure 6a, b*).

Granulation tissue may arise from the mucosa adjacent to the cholesteatoma (*Figure 6c*). A granular polyp within an ear canal represents a cholesteatoma until proven otherwise. Caution must be taken not to remove any polyp within the ear as the cholesteatoma may be attached to vulnerable underlying structures such as the ossicles or facial nerve.

Antibiotic-steroid eardrops can be instilled on a daily basis over 1 week to treat any polyp occluding the ear canal and obstructing the view of the underlying tympanic membrane.

If a cholesteatoma is suspected the patient's facial nerve should be examined. The patient should also be examined for dizziness using the fistula test. A fistula test involves applying positive pressure to the affected ear. It can be performed by placing a finger to the external auditory meatus and creating an airproof seal, or with the insufflation device built within the otoscope.⁹ The test is positive if the increased pressure on the tympanic membrane causes either dizziness or nystagmus.

Differential diagnoses

There are a number of otological conditions that can mimic the appearance of a cholesteatoma such as an osteoma or exostoses (*Figure 7a, b*). Osteoma is a simple growth of the bone of the ear canal forming a sessile lump. Diagnosis can be confirmed by their solid nature on palpation. Solitary exostoses often arise from the roof of bony ear canal and may mimic or hide pathology of the superior tympanic membrane.

Tympanosclerosis is fibrotic scarring of the tympanic membrane (*Figure 7c*). This often indicates previous episodes of otitis media or trauma to the tympanic membrane and is a common appearance after the insertion of ventilation tubes. The fibrous tissue occurs within the layers of the tympanic membrane. On otoscopy, the white lesion within the tympanic membrane can be mistaken for a cholesteatoma deeper within the middle ear. Tympanosclerosis can be distinguished from pathology within the middle ear as it is mobile with the tympanic membrane on pneumo-otoscopy.

Certain perforations and retractions of the tympanic membrane can also potentially mimic cholesteatoma (*Figure 8a, b*). In general, perforations and retractions that occur in the superior and posterior edge of the tympanic membrane ought to be regarded as a cholesteatoma until proven otherwise. There are a number of other features that suggest a perforation is associated with a cholesteatoma (*Table 2*).

Malignancy of the ear canal needs to be suspected in the presence of bone destruction; particularly if there is gross distortion of the soft tissue and bone of the ear canal (*Figure 9*). Areas of ulceration or granulation tissue formation result in blood stained discharge and mild otalgia. Consideration of the diagnosis of malignancy needs to be given to any chronic ear infection that persists despite appropriate medical therapy.

Investigations

Further investigations are required if a cholesteatoma is suspected. This includes an audiogram, where the most common finding is conductive hearing loss.¹⁰ If there is any associated sensorineural hearing loss of an asymmetrical nature the cholesteatoma is thought to be associated with involvement of the inner ear.¹⁰

Computer tomography of the temporal bone is required to determine the extent of the disease and the presence of associated complications.¹¹ The radiological hallmark of cholesteatoma is a lesion within the middle ear and mastoid associated with bone

Figure 7a. Osteoma of the ear canal

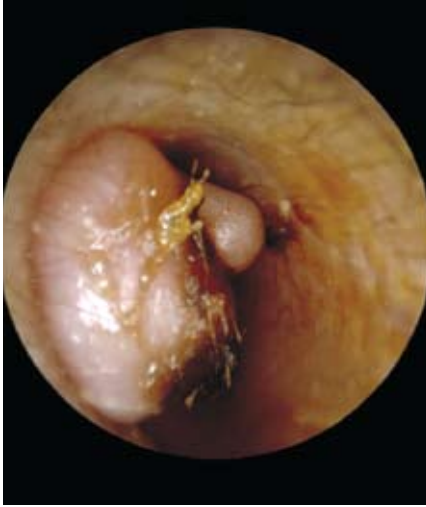

Figure 8a. Subtotal perforations of the tympanic membrane are likely to be safe if they are central and do not involve the fibrous edge of the tympanic membrane

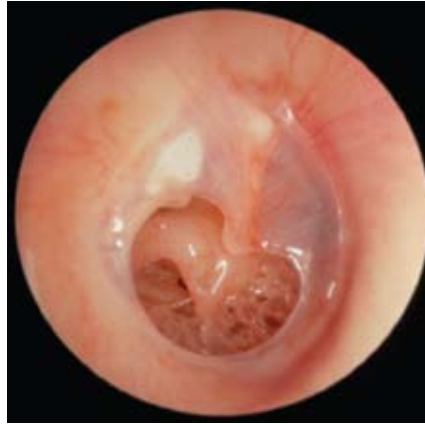

Figure 7b. Solitary exostoses of the ear canal

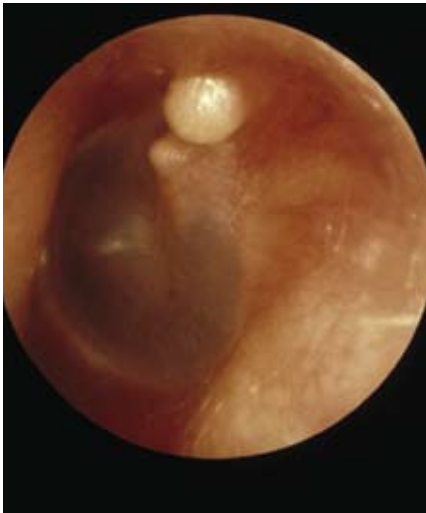

Figure 8b. Total perforation is safe if it does not involve the edge of the tympanic membrane and has no associated white mass, granulation or bone erosion

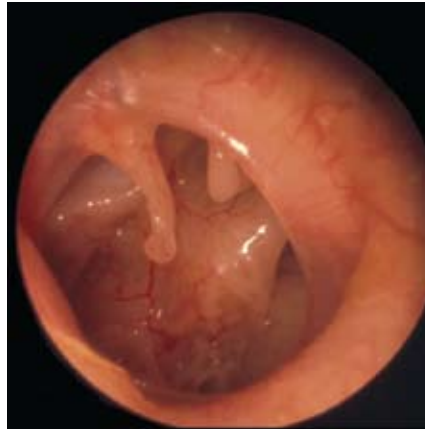
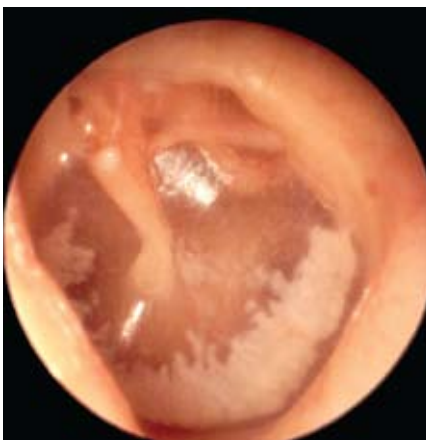
Figure 7c. Tympanosclerosis



destruction. Such bony destruction may involve the ossicles, the bony septa of the mastoid air cells, and the bony covering of the inner ear and facial nerve.

Occasionally magnetic resonance imaging is also required if extension of the cholesteatoma into the cranial cavity is suspected.

Management

Cholesteatomas potentially pose a threat to hearing, balance and facial nerve function. Extensive cholesteatomas are associated with a significant risk of intracranial infection.³ Therefore all cholesteatomas require attention.

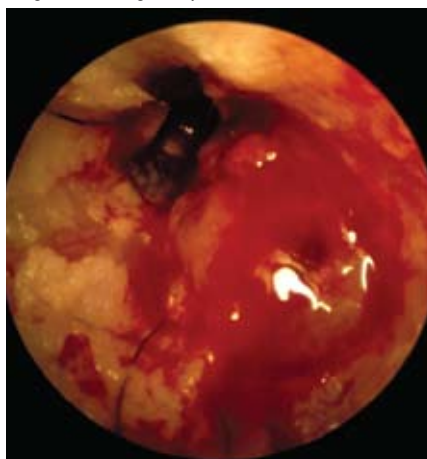The mainstay of treatment for cholesteatoma is mastoid surgery with the aim of providing a safe, dry, waterproof and hearing ear. The procedure is performed through a postauricular incision under general anaesthetic. A concurrent aim of surgery is to restore the hearing with reconstruction of the ossicles.

Surgery to remove a cholesteatoma is not without risk to the vital structures to which the cholesteatoma is intimately associated, including the facial nerve. The

Table 2. Signs of unsafe perforation of tympanic membrane on otoscopy

- Superior and/or posterior edge of tympanic membrane perforation
- Perforation involving fibrous edge or annulus of the tympanic membrane
- Associated granulation tissue
- White mass within middle ear seen through perforation
- Bone erosion

Figure 9. Malignancy of the external ear



integrity of the facial nerve is safeguarded, in part, by the use of a facial nerve monitor during surgery.

Mastoid surgery is often associated with an enlargement of the entrance of the ear canal or meatoplasty. This allows the enlarged cavity within the ear to be properly aerated and free of infection and assists in postoperative care and surveillance.

Occasionally a cholesteatoma is managed conservatively by the regular removal of dead skin within the cyst to control its progression. Skin removal is performed using an operating microscope by an ear, nose and throat surgeon. Treatment is appropriate for cholesteatomas in the elderly or in those with serious health problems for whom surgery would be risky. Cholesteatoma in the only hearing ear is often treated conservatively. Patients need to comply with regular review.

Conclusion

Despite advances in surgery and imaging, the diagnosis of cholesteatomas is often delayed. A favourable outcome following treatment of a cholesteatoma – be it surgical or conservative – rests in part on an early diagnosis, and in reducing the significant complications and associated morbidity.

Primary care physicians should maintain a high index of suspicion for the presence of cholesteatoma, awareness of otoscopic findings and promptly refer for investigations and management.

Conflict of interest: none declared.

References

1. Levenson M, Michaels L, Parisier S. Congenital cholesteatomas of the middle ear in children: origin and management. *Otolaryngol Clin North Am* 1989;22:941–54.
2. Sculerati N, Bluestone CD. Pathogenesis of cholesteatoma. *Otolaryngol Clin North Am* 1989;22:859–68.
3. Tran Ba Huy P, Aisenberg N. Cholesteatoma and cholesteatomas. Pathophysiological and clinical significance of keratin in the middle ear. In: *Pathogenesis in cholesteatoma*. Kugler, 1999.
4. Dornelles C, da Costa S, Meurer L, Schweiger C. Some considerations about acquired adult and pediatric cholesteatomas. *Rev Bras Otorrinolaringol* 2005;71:536–46.
5. Kay DJ, Nelson M, Rosenfeld RM. Meta-analysis of tympanostomy tube sequelae. *Otolaryngol Head Neck Surg* 2001;124:374–80.
6. Kemppainen HO, Puhakka HJ, Laippala PJ, Sipilä MM, Manninen MP, Karma PH. Epidemiology and aetiology of middle ear cholesteatoma. *Acta Otolaryngol* 1999;119:568–72.
7. Smith J. Complications of chronic otitis media and cholesteatoma. *Otolaryngol Clin North Am* 2006;39:1237–55.
8. Smith JA, Danner CA. Complications of chronic otitis media and cholesteatoma. *Otolaryngol Clin North Am* 2006;39:1237–55.
9. Chang P, Pedler K. Ear examination: a practical guide. *Aust Fam Physician* 2005;34:857–62.
10. Haberman R. Middle ear and mastoid surgery. Thieme 2004; p. 100.
11. Williams MT, Ayache D. Imaging in adult chronic otitis. *J Radiol* 2006;87:1743–55.