



**Rumi Khajotia**  
**Sree Raman**  
**Pathmanathan Rajadurai**  
**Wan Yaacob**

# A patient with nodular skin swelling

**Keywords:** general practice; medical oncology; lung neoplasms; skin neoplasms; skin diseases



## Case study

A man, 70 years of age, presents to his general practitioner with a 6 week history of a nodular skin swelling on the trunk. He is a nonsmoker and a known diabetic treated with oral hypoglycaemic agents (OHA). Physical examination reveals a firm, nodular swelling, 4.5 cm in diameter on the skin of the left upper quadrant of the abdomen. The swelling is erythematous and nontender with some excoriation of the overlying skin. The rest of the clinical examination is normal. The GP orders a full blood examination (FBE), fasting blood glucose (FBG) and glycated haemoglobin (HbA1c) and gives the patient a script for flucloxacillin 500 mg qid for 7 days. The patient presents the next day for the results of the tests which reveal a mild leucocytosis ( $13.6 \times 10^9/L$  cells, rest of FBE normal), FBG of 9.6 mmol/L and an HbA1c of 8.5%. The GP discusses with the patient the importance of diabetic self monitoring and lifestyle management and adjusts his OHA therapy. The patient is asked to return in 2 weeks for further review of his diabetic management, however, he does not attend this appointment. He then returns 3 months later complaining of a persistent swelling on the trunk and 2 weeks of cough and pain in the left infrascapular region. On examination, the swelling has slightly increased in size with further excoriation of the overlying skin (*Figure 1*). Breath sounds are absent over the left lower zone of the lung posteriorly. The GP orders a chest radiograph which shows dense infiltration in the left lower zone.

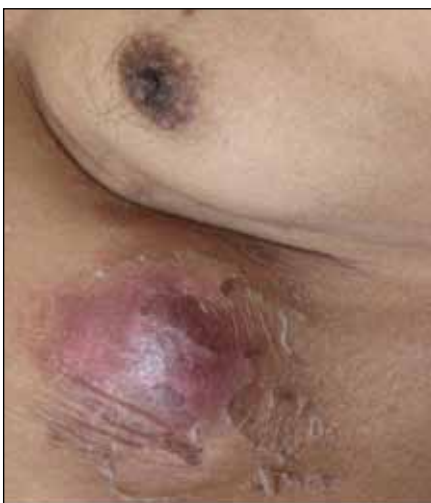

Figure 1. A firm nodular skin swelling in the region of the left upper quadrant

The patient was referred to the emergency department of the local hospital where he had a CT scan of the chest which showed a well defined solid lesion in the left lung which was posterior and peripherally located (*Figure 2*). An incisional biopsy of the skin lesion showed an ulcerating skin tumour with enlarged vesicular nuclei and occasional mitotic activity, originating from the overlying epidermis with invasion into the underlying stroma and positive staining for CK5/6 (*Figure 3a*). A percutaneous lung biopsy showed tumour cells similar in morphology to those seen in the skin with CK5/6 positivity

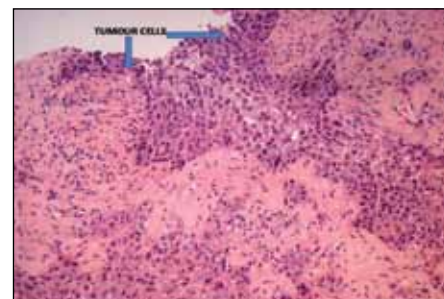


Figure 3a. Histopathology of the skin lesion showing invasive tumour cells originating from the overlying epidermis and invading into the underlying stroma

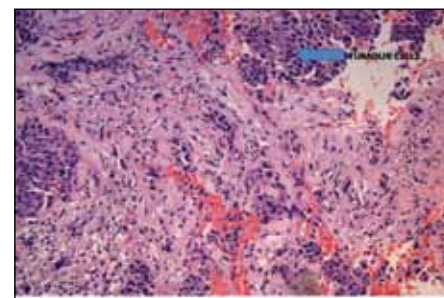


Figure 3b. Histopathology of the lung tissue showing invasive tumour cells with vesicular nuclei and occasional mitotic activity

(*Figure 3b*). The patient was diagnosed with a primary squamous cell carcinoma of the skin (CK5/6 positive) and a lung tumour which was most likely to be a metastasis from the primary skin tumour (T3, N1, M1).<sup>1-3</sup>

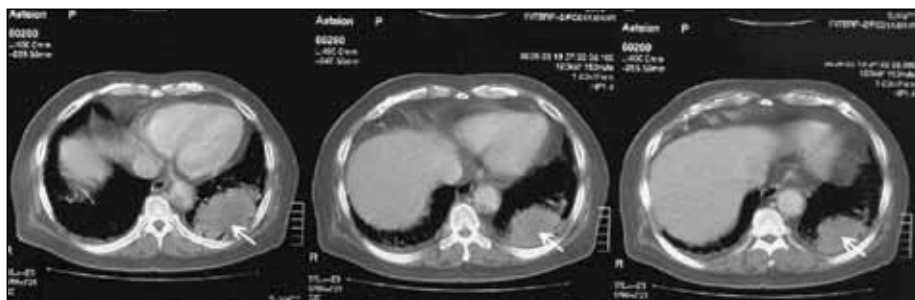

Figure 2. CT scan of the chest showing a solid, well defined, rounded lesion in the left lung posteriorly

### Question 1

At initial presentation, what is the most likely diagnosis?

### Question 2

At the second presentation, what are the indicators that suggest the patient now needs further investigation?

### Question 3

What are the possible differential diagnoses at the second presentation?

### Question 4

Were there any clues to the final diagnosis at the original presentation? Could the GP have done anything different that might have avoided the final outcome?

### Answer 1

The most likely diagnosis at initial consultation is a cutaneous infection (a carbuncle), subcutaneous skin abscess or infected sebaceous cyst. This diagnosis is consistent with an erythematous swelling in a patient with known diabetes. The GP has instituted appropriate treatment with an antibiotic and adjustment of hypoglycaemic therapy for better diabetic control.

### Answer 2

When the patient returns 3 months later, indicators that suggest the need for further investigation include:

- persistence and increase in size of the lesion
- the fact that the lesion is 'firm' and 'nontender'
- the development of a cough with pain and lung infiltration.

### Answer 3

The lesion could still represent a carbuncle, subcutaneous skin abscess or infected sebaceous cyst in an uncontrolled diabetic. The patient could have a pneumonia secondary to haematogenous spread of the infection to the lung or a pneumonia of an unrelated (community acquired) cause. Unusual infections of the skin (such as blastomycosis or tularemia) with subsequent lung infection may also cause this presentation. In addition, carcinoma of the skin with spread to the lungs should be suspected, particularly as the lesion is persistent, firm and nontender.

### Answer 4

When the patient first presented, there were two subtle clinical features which could have alerted the GP to the possible diagnosis, ie. the swelling was both firm and nontender. This could have raised the suspicion of malignancy and therefore the patient could have been alerted to the possibility and asked to closely follow up and report any changes to the nodule, such as an increase in size, recent ulcerations over the nodule, presence of other satellite lesions and emergence of palpable lymph nodes.

### Discussion

Skin swellings are a common presentation to GPs in their day-to-day practice. Usually they are of infective aetiology and resolve with antibiotics and/or drainage. Rarely (as in this case), there is a more sinister cause such as a skin cancer, and it is important for GPs to be alert to any atypical features such as firmness and lack of tenderness. In this case, it was impossible to know whether the cancer had already spread to the lungs at the first presentation. However, early clinical suspicion of cutaneous malignancy could have resulted in a more prompt diagnosis and management (including complete surgical resection of the skin nodule).

It is important for patients to be advised to look for changes in the size of a nodule, the presence of ulceration, development of satellite lesions and emergence of palpable lymph nodes, and contact the GP immediately if they notice these changes.

The incidence of primary cutaneous squamous cell carcinoma has increased dramatically over the past decade.<sup>4</sup> While most of these cancers occur in sun exposed areas of the skin<sup>4</sup> (mostly the scalp, forehead, ears, nose and lips) and metastasis to the lung is rare, it has been observed that the clinical accuracy of detecting cutaneous squamous cell carcinomas is not very high (39%).<sup>5</sup> A high index of suspicion of skin cancer should be maintained in any case where a skin lesion displays atypical clinical features.

### Authors

Rumi Khajotia MBBS, MD, DM, FAMA, FAMS, is Associate Professor, Department of Internal Medicine, International Medical University

Clinical School, and consultant pulmonologist, Department of Internal Medicine, Hospital Tuanku Ja'afar, Seremban, Negeri Sembilan, Malaysia. rumi@imu.edu.my

Sree Raman MBBS, MRCP, FRCP, FNHAM, is Senior Consultant Physician, Department of Internal Medicine, Hospital Tuanku Ja'afar, Seremban, Negeri Sembilan, Malaysia

Pathmanathan Rajadurai MBBS, MD, FRCPA, is Professor of Pathology, Malaysia School of Medicine and Health Sciences, Monash University, Sunway, Malaysia

Wan Yaacob MPath, is pathologist, Pathology Department, Hospital Tuanku Ja'afar, Seremban, Negeri Sembilan, Malaysia.

Conflict of interest: none declared.

### References

1. Sobin L, Wittenkind C. TNM classification of malignant tumours, 6th edn. Hoboken, NJ: John Wiley & Sons, 2002.
2. Rowe DE, Carroll RJ, Day CL Jr. Prognostic factors for local recurrence, metastasis, and survival rates in squamous cell carcinoma of the skin, ear and lip: implications for treatment modality selection. *J Am Acad Dermatol* 1992;26:976–90.
3. Leong PP, Rezaei B, Koch WM, et al. Distinguishing second primary tumors from lung metastasis in patients with head and neck squamous cell carcinoma. *J Natl Cancer Inst* 1998;90:972–7.
4. Rodust PM, Stockfleth E, Ulrich C, et al. UV-induced squamous cell carcinoma – a role for antiapoptotic signalling pathways. *Br J Dermatol* 2009;161(Suppl 3):107–15.
5. Green A, Leslie D, Weedon D. Diagnosis of skin cancer in the general population: clinical accuracy in the Nambour survey. *Med J Aust* 1988;148:447–50.

correspondence [afp@racgp.org.au](mailto:afp@racgp.org.au)