



Sergio Vano-Galvan

MD, is a dermatology resident, Department of Dermatology, Ramon y Cajal University Hospital, Madrid, Spain. sergiovano@yahoo.es

Elena de las Heras

MD, PhD, is Dermatology Senior, Department of Dermatology, Ramon y Cajal University Hospital, Madrid, Spain.

Ingrid Aguayo-Leyva

MD, is a dermatology resident, Department of Dermatology, Ramon y Cajal University Hospital, Madrid, Spain.

Dermatoscopy for in vivo diagnosis of malignant melanoma

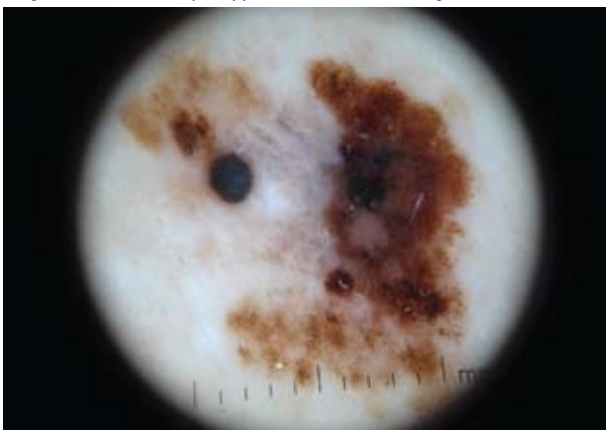
Case study

A man, 59 years of age, presented with a pigmented lesion that was discovered on lung auscultation by a family physician. Clinically, a 12 mm long, slightly elevated, brown lesion with variegate pigmentation was observed on his back (*Figure 1*). Dermatoscopy revealed a multicomponent pattern characterised by irregular pigmented network, radial streaming and pseudopods along with extensive blue-grey areas and a dark brown patch (*Figure 2*).

Figure 1. Clinical image showing an irregular, slightly elevated brown lesion with variegate pigmentation located on the back of the patient

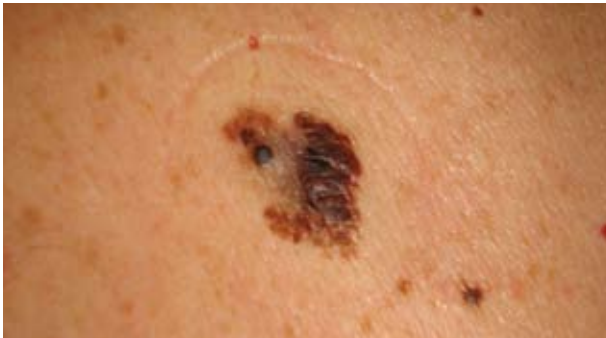

Figure 2. Dermatoscopic appearance of lesion in Figure 1



Question 1

What is your differential diagnosis?

Question 2

What is the most likely diagnosis given the dermatoscopic appearance?

Answer 1

The differential diagnosis of this pigmented lesion would include a pigmented basal cell carcinoma, dysplastic naevus, malignant melanoma or seborrheic keratosis.

Answer 2

In this patient, clinical findings were suggestive of a malignant pigmented skin lesion. This was reinforced by the dermatoscopic findings outlined above. Dermatoscopic features of malignant melanoma include an irregular pigmented network, multiple colours (blue, brown, black, grey red), radial streaming, peripheral black dots and globules, and a blue-white veil over the lesion. These features are not visible to the naked eye.

Excisional biopsy was therefore indicated. Histology confirmed the diagnosis of superficial spreading malignant melanoma (Breslow 1.01 mm, Clark level III and regression less than 50%). Sentinel lymph node biopsy was negative.

Discussion

The worldwide incidence of melanoma and nonmelanoma skin cancers is increasing alarmingly. The development of new techniques such as dermatoscopy leads to a consequent progress in skin cancers screening. Dermatoscopy (epiluminescence microscopy) is a noninvasive technique designed for in vivo microscopic examination of pigmented skin lesions, particularly for the early recognition of malignant melanoma.

The dermatoscope, despite its ease of handling, is not a mere magnifying glass, but a more complex instrument,

Pedro Jaén

MD, PhD, is Chief, Department of Dermatology, Ramon y Cajal University Hospital, Madrid, Spain.

allowing the superimposition of the skin layers. It allows in vivo evaluation of colours and microstructures of the epidermis, dermoepidermal junction, and papillary dermis not visible to the naked eye. These structures are specifically correlated with histological features.¹ The identification of specific diagnostic patterns related to the distribution of colours, the degree of pigmentation and dermatoscopic structures may improve diagnosis of a malignant versus a benign pigmented skin lesion. Dermatoscopy may also differentiate not only whether to biopsy (benign or malignant), but whether to excise in the case of suspected melanoma or biopsy with an incisional method (eg. punch, shave or curette) in the case of a nonmelanocytic suspected lesion such as a pigmented basal cell carcinoma. Consensus documents of dermatoscopic patterns have been published, based on scientific evidence and expert experience, in order to provide guidelines and improve the quality of the reporting of dermatoscopic findings.²

Dermatoscopy, in the hands of experienced physicians, has higher discriminatory power than naked eye examination to detect skin cancers.³ Accuracy in diagnosing melanoma and other dark skin lesions improves dramatically with dermatoscopic skills.⁴ This technique has emerged as a cost effective in vivo method for early diagnosis of melanoma, improving the diagnostic accuracy in the clinical evaluation of pigmented skin lesions, and leading to a decreased number of excised benign lesions. Early recognition and excision of potential primary melanomas remains the most effective way to increase survival in this highly malignant disease.

Conflict of interest: none declared.

References

1. Campos-do-Carmo G, Ramos-e-Silva M. Dermoscopy: Basic concepts. *Int J Dermatol* 2008;47:712–9.
2. Malvehy J, Puig S, Argenziano G, et al. Dermoscopy report: Proposal for standardization. Results of a consensus meeting of the International Dermoscopy Society. *J Am Acad Dermatol* 2007;57:84–95.
3. Massone C, Di Stefani A, Soyer HP. Dermoscopy for skin cancer detection. *Curr Opin Oncol* 2005;17:147–53.
4. Dixon AJ, Hall RS. Managing skin cancer: 23 golden rules. *Aust Fam Physician* 2005;34:669–71.