

# Nicorandil induced oral ulceration

**C S Farah**, BDSc, MDSc, PhD, is Senior Lecturer in Oral Medicine and Pathology, The University of Queensland, and Consultant Oral Pathologist, Brisbane, Queensland.

**L M Carey**, MBBS, FRACP, is Consultant Cardiologist, Queensland Cardiovascular Group, Brisbane, Queensland.

**N W Savage**, MDSc, PhD, FFOP RCPA, FICD, is Reader in Oral Medicine and Pathology, The University of Queensland, and Consultant Oral Pathologist, Royal Brisbane Hospital, Queensland.

Many drugs cause oral ulcerative lesions,<sup>1</sup> including antihypertensive drugs such as angiotensin converting enzyme inhibitors<sup>2</sup> and angiotensin 2 receptor antagonists,<sup>1,3</sup> antimetabolites, and cytotoxic drugs.<sup>1</sup> So too does nicorandil, a new class of potassium channel activator used for angina pectoris. It is a relatively new drug that has been described as a hybrid between nitrates and potassium channel activators.<sup>4</sup> There have been several reports describing oral ulceration associated with its use and administration,<sup>5-8</sup> but as yet not in Australia.

## Clinical presentation

A 74 year old caucasian man was referred by his general dental practitioner to the Oral Medicine Clinic at the School of Dentistry, the University of Queensland, with a three week history of an ulcerative lesion on the anterior ventral tongue. The patient had a history of angina pectoris, exertional dyspnoea, hypertension, previous acute myocardial infarction treated by percutaneous transluminal coronary angioplasty, and renal calculi.

The patient's initial therapy included atenolol, amlodipine besylate, nicorandil, isosorbide mononitrate, atorvastatin calcium, aspirin 100 mg, and glyceryl trini-

trate spray. He was commenced on nicorandil (20 mg per day) approximately 2-3 months before the onset of oral lesions.

Clinical examination revealed a 1.0-1.5 cm oedematous ulcerative lesion with a heavy surface pseudomembrane involving the anterior ventral tongue (Figure 1a). There was no induration, fixation, or other signs of neoplasia, and no nodes were palpable. There was no history of previous oral ulceration or trauma to the area. The lesion was locally painful, especially at mealtime and the patient reported significant functional impairment.

The provisional diagnosis was a reactive inflammatory lesion, and was managed with tetracycline hydrochloride mouthwash twice per day to debride the surface pseudomembrane, and mometasone furoate 0.1% ointment twice per day to reduce the inflammation. At one week there was an overall marked improvement, but the site appeared lichenoid (Figure 1b). The patient decreased the atenolol from 50-25 mg per day, while amlodipine was increased from 5-10 mg per day. Two weeks later it was still not resolved, and the patient had peripheral oedema. Therefore, the nicorandil was stopped. The ulcer completely resolved four weeks later with no complications.

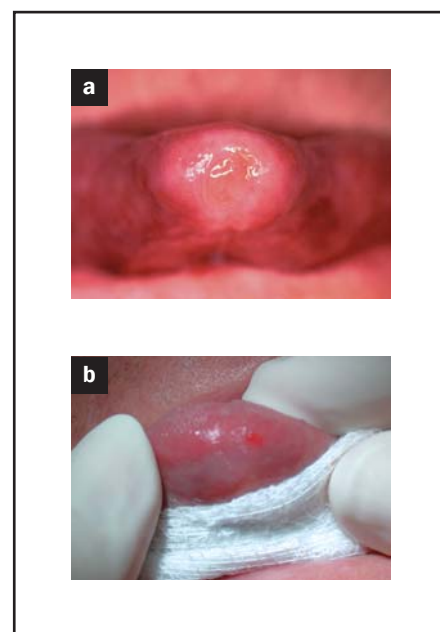


Figure 1a, b. Oral ulceration involving the anterior tip of the tongue

## Discussion

The most common adverse effect reported in patients receiving nicorandil therapy in clinical trials was headache (36.4%), occasionally severe and prolonged.<sup>9</sup> Other common adverse effects are myalgia, abdominal pain, lethargy, back pain, chest pain, dizziness and infection. Other less common (<1%) adverse

events include nausea, vomiting, diarrhoea, malaise, dyspepsia, constipation, insomnia, skin rashes, and peripheral oedema. Rare adverse effects (<0.1%) include stomatitis and oral ulceration.<sup>9</sup>

There have been three reports of tongue ulceration and glossitis submitted to the Australian Therapeutic Goods Administration Adverse Drug Reactions Advisory Committee out of a total of 36 reported drug reactions associated with nicorandil.

The ulcers are relatively large in size (0.8–1.5 cm), appearing like aphthous ulcers, and beginning between immediately to three years after commencing nicorandil. Most cases are in patients receiving daily doses as high as 60 mg. Resolution is usually complete, without scarring, 2–6 weeks after ceasing the drug.<sup>5–8</sup>

Many drugs used in the management of patients with cardiovascular disease give rise to adverse events that affect the oral mucosa.<sup>1</sup> Antihypertensive agents and beta adrenergic blockers can cause dry mouth, while angiotensin converting enzyme (ACE) inhibitors, thiazide diuretics and beta blockers are known to cause lichenoid drug reactions. Others such as calcium channel blockers (nifedipine) can cause gingival enlargement, while captopril (ACE inhibitor) and losartan (angiotensin 2 receptor antagonist) can cause angioedema and oral ulceration.<sup>1</sup>

Nicorandil is yet another drug associated with severe oral ulceration. The mechanism by which this occurs is not clear, especially since nicorandil has been reported to be protective against experimentally induced gastric ulceration in an animal model.<sup>10</sup>

## Conclusion

It is clear that many drugs used in the management of patients with cardiovascular disease can lead to several adverse reactions in the oral cavity. The clinician must therefore be aware of such complications and be prepared to deal with them accordingly.

## SUMMARY OF IMPORTANT POINTS

- Oral ulceration and lichenoid changes are common side effects of many cardiovascular drugs.
- Diagnosis may be difficult and the history is usually most helpful.
- Management is simply centred on withdrawing the drug.
- If this is not possible for cardiac reasons, only symptomatic treatment can be offered (corticosteroid ointment, or local anaesthetic).

Conflict of interest: none declared.

## References

1. Scully C, Cawson R A. Medical problems in dentistry. 4th edn. Oxford: Wright, 1998.
2. Seedat Y K. Aphthous ulcers of mouth from captopril. *Lancet* 1979; 15:1297–1298.
3. Goffin E, Pochet J M, Lejuste P, De Plaen J F. Aphthous ulcers of the mouth associated with losartan. *Clin Nephrol* 1998; 50:197.
4. Krumenacker M, Roland E. Clinical profile of nicorandil: An overview of its hemodynamic properties and therapeutic efficacy. *J Card Pharm* 1992; 20(Suppl 3):S93–S102.
5. Reichert S, Antunes A, Trechot P, et al. Major aphthous stomatitis induced by nicorandil. *Eur J Dermatol* 1997; 7:132–133.
6. Cribier B, Marquart-Elbaz C, Lipsker D, et al. Chronic buccal ulceration induced by nicorandil. *Br J Dermatol* 1998; 138:372–373.
7. Shotts R H, Scully C, Avery S M, Porter S R. Nicorandil induced major aphthous ulceration: A newly recognised oral disease. *Oral Surg Oral Med Oral Pathol Oral Radiol Endod* 1999; 87:706–707.
8. Scully C, Azul A M, Crighton A, et al. Nicorandil can induce severe oral ulceration. 2001; 91:189–193.
9. Roland E. Safety profile of an anti-anginal agent with potassium channel-opening activity: An overview. *Eur Heart J* 1993; 14(Suppl B):48–52.
10. Sakai K, Akima M, Katsuyama I. Effects of nicorandil on experimentally induced gastric ulcers in rats: A possible role of K(ATP) channels. *Jpn J Pharmacol* 1999; 79:51–57.

AFP