

Back lesion

Steve Trumble, MBBS, MD, DipRACOG, FRACGP, is Editor in Chief, Australian Family Physician, Associate Professor, the University of Melbourne, Honorary Clinical Associate Professor, Monash University, and a general practitioner, East Brighton, Victoria.

72 year old Alan Henry is a retired cane farmer from Tully in North Queensland. His daughter noticed this 3 mm lesion on his back about one year ago. She doesn't think it has changed during that time. You examine it with a magnifying glass and dermatoscope.

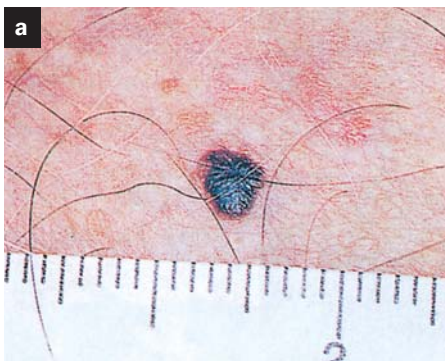


Figure 1a. View under magnification (mm)

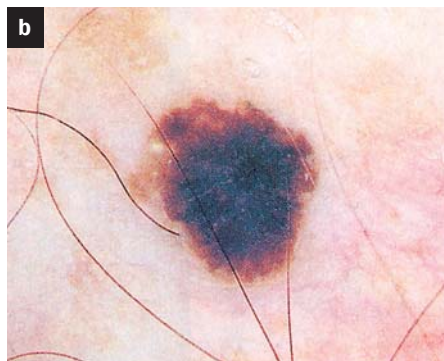


Figure 1b. View through dermatoscope with oil

Photos reprinted with permission: Menzies S, McCarthy W H, Crotty K A, Ingvar C. An Atlas of Surface Microscopy of Pigmented Skin Lesions: Dermoscopy. Sydney: McGraw Hill, 2003.

Question 1

What is the likely diagnosis?

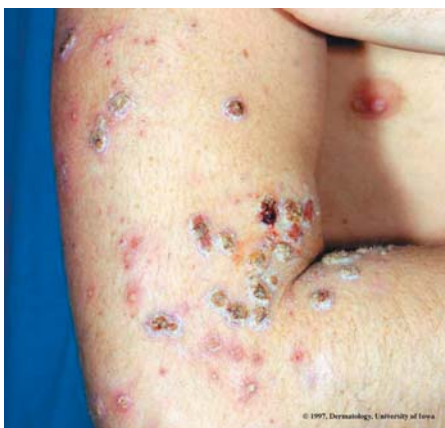Question 2

What are the key positive and negative features of this lesion under surface microscopy?

Question 3

What is the appropriate management?

Answer to last month's brain teaser



Answer 1

Impetigo, commonly called 'school sores', is a highly contagious infection of the skin, particularly common in young children.

Answer 2

The most common causative organisms are Group A β -haemolytic streptococci and *Staphylococcus aureus*.

Answer 3

Management for localised or uncomplicated lesions consists of washing the crusts off and applying topical mupirocin 2% ointment every eight hours. Multiple lesions or those not responding to topical treatment are treated as for cellulitis, ie. flucloxacillin 25 mg/kg (max 500 mg) orally every six hours for seven days.

Send your answers to arrive by 5 November. A voucher for medical books or medical equipment to the value of \$100 will be awarded for the first correct entry drawn. The winner will be notified by mail and the answer published in the November 2003 issue.

**Address entries to:
October Brain Teaser
Australian Family Physician
1 Palmerston Crescent
South Melbourne
Victoria 3205**

The winner of the August Brain teaser is Dr Siavash Missaghi, Rockhampton, Qld