

# Patient with a leg ulcer

**Gary Wu**, is a trainee intern, Dunedin School of Medicine, New Zealand.

**Fernanda Teixeira**, MD, PhD, is Senior Lecturer, Dunedin School of Medicine, New Zealand.

**Branko Sijnja**, MD, FRACGP, is a general practitioner, Balclutha, New Zealand.

**Leo Celi**, MD, is an Infectious Disease Consultant, Dunedin Public Hospital, New Zealand.

**Penelope Wright**, MBChB, is a pathology senior registrar, Dunedin Public Hospital, New Zealand.

**Andre Van Rij**, MD, FRACS, is Head of Surgery, Dunedin Public Hospital and Dunedin School of Medicine, New Zealand.

## Case history

Ms M, a previously well 38 year old woman, presented after noticing the appearance of a papule on the medial side of her right leg that grew over a period of two weeks to form a tender, red, golf ball size mass. As she reported to have fallen from a ladder some time before the appearance of the lesion, the diagnosis of abscess was made and she was treated with penicillin without improvement. In the next fortnight the lesion continued to grow and showed a central area of ulceration. The affected area was exquisitely painful. Figure 1 shows the appearance of the lesion on the day of admission to hospital. The lines on the leg outline the extent of the erythematous, swollen skin. The ulcer grew in diameter from day to day.

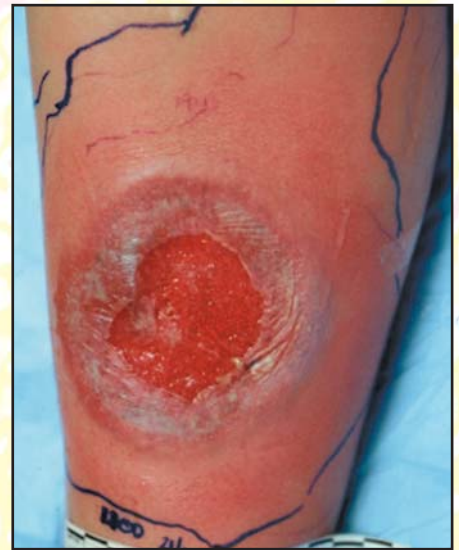

Figure 1. Ulceration of leg

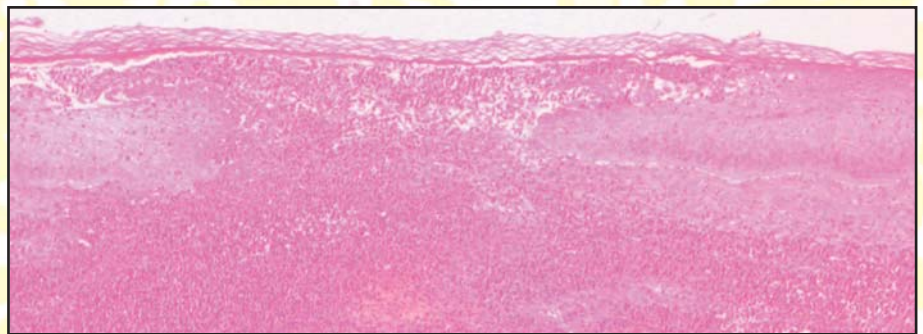


Figure 2. Biopsy of ulcer

## Question 1

What are the possible diagnoses in this case?

## Question 2

A biopsy was taken from the border of the ulcer and is shown in Figure 2. Stains for bacteria, mycobacteria and fungi were all negative. What is the most probable diagnosis?

## Question 3

How would you manage this patient? Figure 3 shows the appearance of Ms M's leg after one month of treatment.

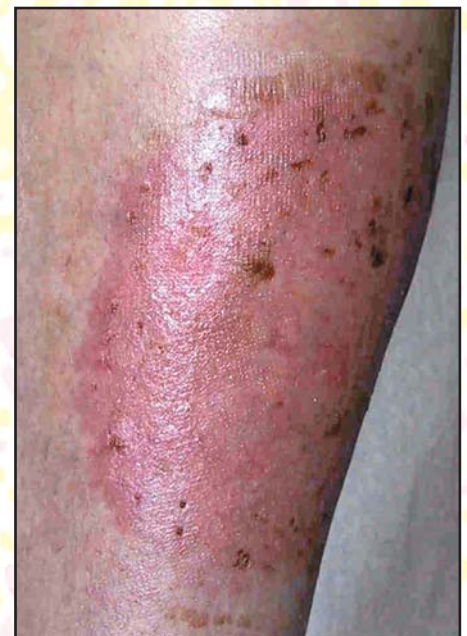

Figure 3. Leg post-treatment

## Answers

### Answer 1

The appearance of a rapidly enlarging ulcer on a young person's leg evokes several diagnostic possibilities including:

- **Necrotising fasciitis:** This condition should be included in the differential diagnosis as rapid surgical debridement is essential for its treatment. Many patients with this condition will be very toxic, with anaesthesia or crepitus of the affected skin and laboratory evidence of rhabdomyolysis or disseminated intravascular coagulation.
- **Insect and spider bites:** Although Ms M lives on a farm, she could not recall being bitten by an arthropod. A biopsy would show an inflammatory infiltrate containing eosinophils, and a neutrophilic vasculitis with necrosis of arterial walls and areas of the dermis and subcutaneous fat.
- **Panniculitis:** In some forms of panniculitis, especially those accompanied by vasculitis, there may be ulceration that may heal with scarring.
- **Factitial ulcer:** Ms M's history does not suggest a tendency for self mutilation.
- **Ulcerated necrobiosis lipoidica:** Ms M's glucose levels were normal, but as only one-quarter of cases of necrobiosis lipoidica are associated with diabetes or glucose intolerance, this entity would have to be excluded by biopsy.
- **Deep mycoses, mycobacterial infections, cutaneous amoebiasis and other infections:** Fungi, amoebas and mycobacteria can be searched in the biopsy material with special stains, culture and polymerase chain reaction can help to detect mycobacteria as they are usually very scarce.
- **Pyoderma gangrenosum:** Although a diagnosis of exclusion, is a possibility in Ms M's case considering the evolution of the lesion and its purple, undermined borders. The diagnosis of pyoderma gangrenosum is a clinical one, as biopsy changes are nonspecific'.

### Answer 2

A punch biopsy was taken from the undermined border and showed no micro-organisms. There was marked neutrophilic infiltrate of all layers of the skin with areas of necrosis of the epidermis but no evidence of vasculitis. These data were compatible with the clinical diagnosis of pyoderma gangrenosum.

### Answer 3

The patient with pyoderma gangrenosum must be examined for underlying systemic disorders including rheumatoid disease, inflammatory bowel disease, haematologic malignancy and liver disease, particularly active chronic hepatitis B or C and primary biliary cirrhosis. Investigations can be divided into:

First line investigations

- complete blood count
- liver function tests
- rheumatoid factor
- further gastrointestinal investigation.

Second line tests

- although most leg ulcers associated with antiphospholipid syndrome are deeply punched out, indolent and with little inflammation, in some patients they may be similar to pyoderma gangrenosum. If this is a possibility, the following tests should be considered:
  - venereal disease research laboratory (VDRL)
  - anticardiolipin antibody, and
  - partial thromboplastin time
- in older patients, plasma protein electrophoresis could be part of the search for an underlying haematologic malignancy
- antineutrophil cytoplasmic antibody (ANCA). Patients with pyoderma gangrenosum may show perinuclear ANCA, especially those who have inflammatory bowel disease
- as cryoglobulinaemia is an extra-hepatic manifestation of hepatitis C infection that can lead to the appearance of leg ulcers, cryoglobulin screen can be carried out.

Because the pathogenesis of pyoderma gangrenosum is poorly understood, treatment has been developed on an empirical basis. Topical treatment is in conjunction with systemic drugs, or alone in mild cases and includes:

- rest, limb elevation and bio-occlusive semipermeable dressings
- if the pain is not intense, improvement has been reported after intralesional injections of triamcinolone acetonide.

Debridement is not recommended as patients with pyoderma gangrenosum tend to form new lesions in areas of trauma ('pathergy').

Systemic corticosteroids are effective in many severe or rapidly evolving cases. Ms M received 80 mg of prednisone per day, which was tapered down in 30 days. On the third day of treatment the pain had virtually disappeared and at month end the lesion had healed (Figure 3). Patients who are refractory to this treatment may be commenced on cyclosporine. Reports of success with dapsone, clofazimine and sulfasalazine have been published. Some cases associated with cryoglobulinemia or chronic hepatitis have responded to interferon alfa and in those desperate cases that fail to respond to any of the above modalities, a course of 100 mg of thalidomide per night may be attempted, although this drug has to be handled with extreme care due to its teratogenic properties and tendency to produce peripheral neuropathy.

Conflict of interest: none declared.

### Conclusion

- If an ulcer is not healing, it should be biopsied.
- A diagnosis of pyoderma gangrenosum should prompt a search for underlying disease.

### Reference

1. Callen J P. Pyoderma gangrenosum. *Lancet* 1998; 351(9102):581-585.